MASTERING ANATOMY
A Comprehensive Guide to MCQs, Essays, and OSPEs
Part III

Uva Wellassa University

Batch - 1 Semester 3 and 2nd MBBS

- **Head & Neck**
- **Central Nervous System**
- **Lower Limb**

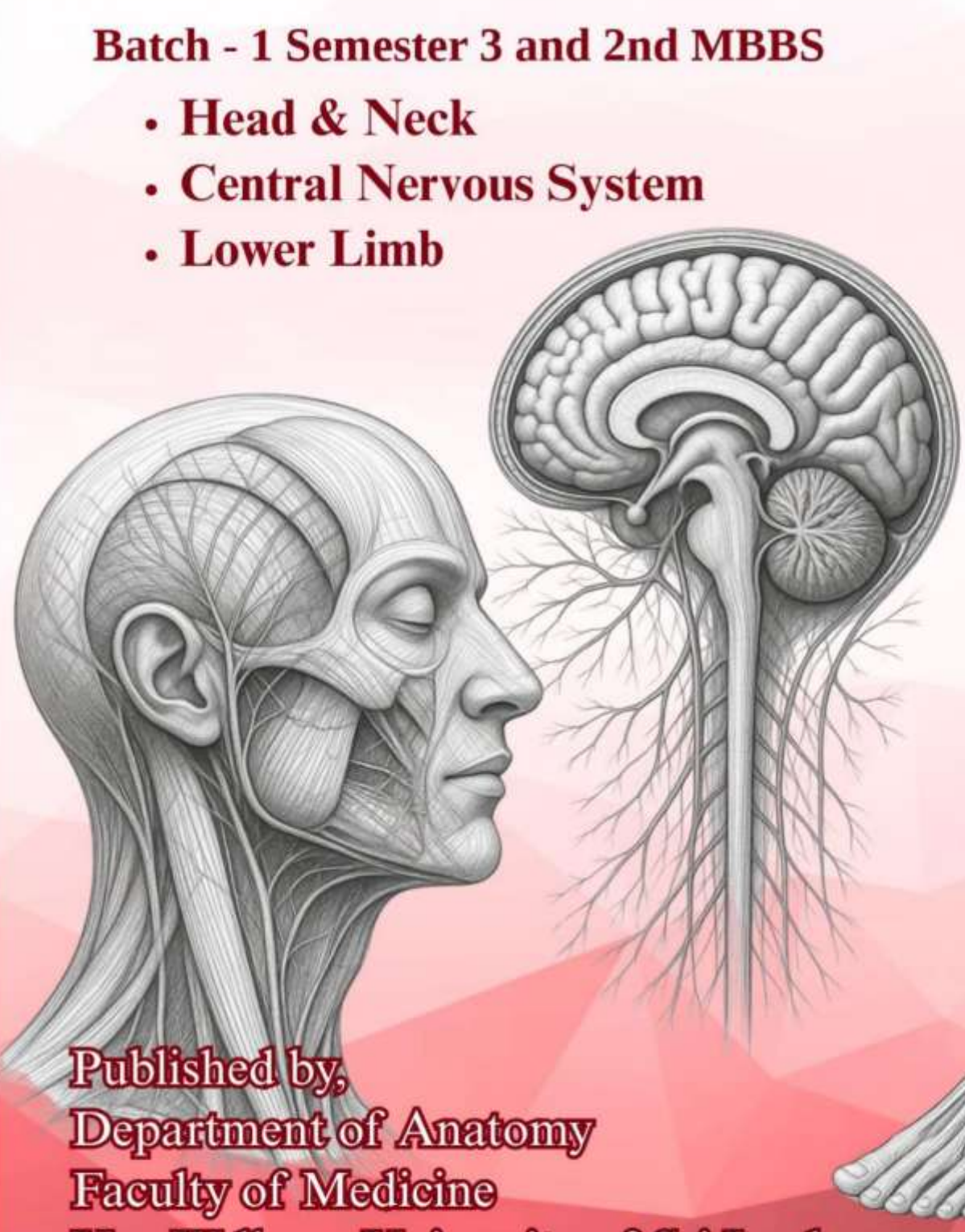

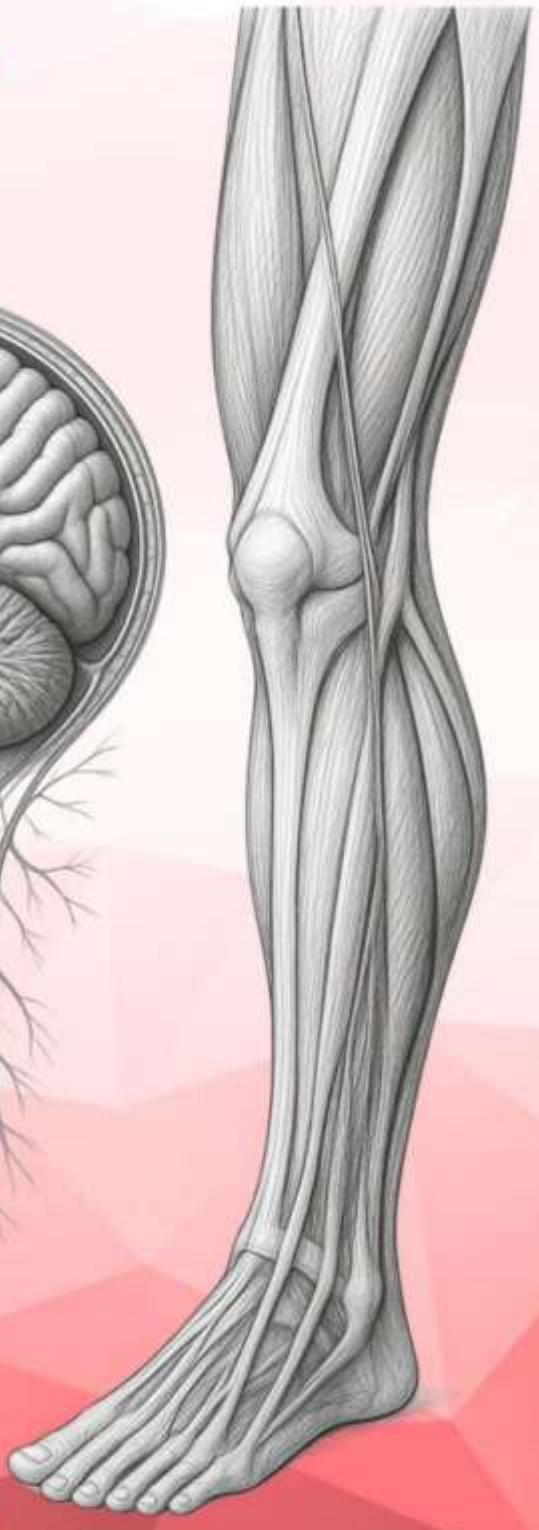

Published by,
Department of Anatomy
Faculty of Medicine
Uva Wellassa University of Sri Lanka

2026

MASTERING ANATOMY

A Comprehensive Guide to MCQs, Essays & OSPEs

Part III

Batch 1 - Semester 3 and 2nd MBBS

- **Head & Neck**
- **Central Nervous System**
- **Lower Limb**

Authored by:

Department of Anatomy

Faculty of Medicine

Uva Wellassa University of Sri Lanka

2026

Mastering Anatomy
A Comprehensive Guide to
MCQs, Essays & OSPEs
Part III

Batch 1 - Semester 3 and 2nd MBBS

Copyright © 2026 Department of Anatomy, Faculty of Medicine, Uva Wellassa University of Sri Lanka.

All rights reserved.

No part of this publication may be reproduced, stored in a retrieval system, or transmitted in any form or by any means-electronic, mechanical, photocopying, recording, or otherwise-without prior written permission from the publisher.

Disclaimer: Educational Purpose Only.
This book, including the multiple-choice questions (MCQs), answers, and rationales, is intended strictly for educational and examination review purposes for medical students. It is designed to reinforce learning and evaluate theoretical knowledge. It should not be treated as a clinical reference manual or used as a guide for real-world patient care, diagnosis, or treatment.

ISBN: 978-624-6685-48-5
Compiled by:
Department of Medical Education, Faculty of Medicine,
Uva Wellassa University of Sri Lanka,
Passara road, Badulla,
Sri Lanka.
90 000

Published & Printed by:

First Edition: 2026.08.13 Rs. 1500/=

Contributors to Excellence

A concept of: Snr. Prof. Muditha Vidanapathirana, Dean, Faculty of Medicine

---

Authors:

Dr. Lakmal Hewage
MBBS (COL), MD SURGERY (COL), MRCS (ENG)
Consultant Neurosurgeon, Senior Lecturer (Grade II)
Head of the Department of Anatomy

Professor Ajith Peiris Malalasekera
MBBS(Col), MS(Col), MRCS(Lond), FCS(SL)
Professor in Urology
Consultant Urological Surgeon
Department of Anatomy
Faculty of Medicine, University of Colombo, Sri Lanka.

Mrs. Nishadi Sachinthani Rodrigo
BSc. Anatomy (Special) (USJ), MSc (UOC), PG. Cert. (Andrology) (UOC)
Lecturer (Probationary)

Dr. Nishantha Liyadipita
MBBS (Col), PG Dip. Anatomy
Senior Medical Officer
Base Hospital Welimada

Dr. H.M. Piyumika Prabodhani
MBBS (Ruhuna)
Temporary Demonstrator, Department of Anatomy

Dr. M.M. Chathurika Piyumali
MBBS (Peradeniya)
Temporary Demonstrator, Department of Anatomy

Snr. Prof. Muditha Vidanapathirana
MBBS (Col), DLM, MD, MA (SJP), FFFLM (UK)
Head of the Department of Forensic Medicine

Cover design by:
Dr. Shamod Abeysekara
MBBS (Peradeniya)
Temporary Demonstrator, Department of Physiology



Message from the Vice Chancellor

Dear Students,

It gives me great pleasure to extend my heartfelt congratulations and sincere appreciation to the Faculty of Medicine, Uva Wellassa University of Sri Lanka, and particularly to Senior Professor Muditha Vidanapathirana, Dean of the Faculty of Medicine, for their remarkable achievement in successfully publishing "Mastering Anatomy – Part III: A Comprehensive Guide to MCQs, Essays & OSPEs."

This publication serves as an exceptional academic resource, offering considerable value not only to the MBBS undergraduates of Uva Wellassa University of Sri Lanka but also to medical students throughout the country.

I strongly encourage students to make the best use of the high-quality learning materials developed by the Faculty of Medicine. Resources such as this guide can greatly enhance the learning process, making studies more organized, productive, and rewarding.

I wish you every success in your future academic pursuits and professional careers.

Senior Professor Kolitha B. Wijesekara
B.Sc. (Hon.) (Peradeniya), M.Phil. (Peradeniya),
Dr. Sc. Agr. (Gottingen, Germany), M.Biol.
Vice Chancellor
Uva Wellassa University of Sri Lanka
06.01.2026



Message from the Head of the Department

Dear Students,

As the Head of the Department of Anatomy, I am pleased to share my thoughts on the publication of "Mastering Anatomy – Part III: A Comprehensive Guide to MCQs, Essays, and OSPEs." This resource has been carefully developed to support your learning and enhance your understanding of anatomy, which serves as a fundamental pillar of medical education and clinical practice.

Medical training requires commitment, perseverance, and access to effective learning tools. In keeping with our department's dedication to academic excellence, this guide has been designed to help you strengthen your knowledge, apply concepts confidently, and prepare successfully for assessments. By combining different question formats with explanatory content, it provides opportunities to reinforce learning and develop a more comprehensive grasp of anatomical principles.

I encourage you to use this guide actively throughout your studies. Engaging with the questions and explanations will not only improve your knowledge but also cultivate critical thinking and analytical skills that are essential for your future roles as healthcare professionals. A strong foundation in anatomy will greatly contribute to your success in clinical learning and patient care.

I extend my sincere gratitude to the faculty members who generously contributed their expertise and effort to this publication. I hope this guide serves as a valuable companion in your academic journey and supports your future achievements in medicine.

Warm regards,

Dr. Lakmal Hewage
MBBS (COL), MD SURGERY (COL), MRCS (ENG)
Consultant Neurosurgeon, Senior Lecturer (Grade II)
Head of the Department of Anatomy
Faculty of Medicine
Uva Wellassa University of Sri Lanka

CONTENTS

ANATOMY PRACTICE MCQs (T/F & SBR) 10
Head & Neck Practice MCQs 11
Central Nervous System Practice MCQs 17
Lower Limb Practice MCQs 19
ANATOMY PRACTICE MCQs ANSWERS (T/F & SBR) 23
Head & Neck Practice MCQs Answers 24
Central Nervous System Practice MCQs Answers 48
Lower Limb Practice MCQs Answers 57
BATCH 02 – SEMESTER 03 SMALL GROUP DISCUSSIONS (SGDs) WITH ANSWERS 72
SGD 01 – Skull, Cervical spine & Anatomy of Neck Movements MCQs 73
SGD 01 – Skull, Cervical spine & Anatomy of Neck Movements MCQs Answers 75
SGD 02 - Arteries, Veins & Lymphatic Drainage of the Head & Neck MCQs 82
SGD 02 - Arteries, Veins & Lymphatic Drainage of the Head & Neck MCQs Answers 84
SGD 03 - Anatomy of Neck 91
SGD 03 - Anatomy of Neck Answers 92
SGD 04 - Cerebral Cortex 105
SGD 04 - Cerebral Cortex Answers 106
SGD 05 - Basal Ganglia & Cerebellum 111
SGD 05 - Basal Ganglia & Cerebellum Answers 112
SGD 06 - Applied Anatomy of CNS 120
SGD 06 - Applied Anatomy of CNS Answers 121
SGD 07 - Anatomy of Knee and Popliteal Fossa 124
SGD 07 - Anatomy of Knee and Popliteal Fossa Answers 125
SGD 08 - Calf & Ankle Joint 130
SGD 08 - Calf & Ankle Joint Answers 131
SGD 09 - Applied anatomy of Lower limb 136
SGD 09 - Applied anatomy of Lower limb Answers 137

BATCH 02 – SEMESTER 03 TUTORIALS WITH ANSWERS.....141
Tutorial 01 - Face.....142
Tutorial 01 – Face Answers.....143
Tutorial 02 - Spinal Cord & Tracts.....150
Tutorial 02 - Spinal Cord & Tracts Answers.....151
Tutorial 03 - Hip & Gluteal Region.....155
Tutorial 03 - Hip & Gluteal Region Answers.....156
BATCH 02 – CAT 03 MOCK EXAM PAPERS WITH ANSWERS.....158
Batch 02 – CAT 03 - MOCK MCQ Paper.....159
Batch 02 – CAT 03 - MOCK MCQ Paper Answers.....163
Batch 02 – CAT 03 - MOCK OSPE Paper.....176
Batch 02 – CAT 03 - MOCK OSPE Paper Answers.....186
CONTINUOUS ASSESSMENT (CAT) – 03 PAPERS WITH ANSWERS.....190
Batch 01 – CAT 03 (2025) – MCQ Paper.....191
Batch 01 - CAT 03 (2025) – MCQ Paper Answers.....197
Batch 01 – CAT 03 (2025)– OSPE Paper.....198
Batch 01 – CAT 03 (2025) – OSPE Paper Answers.....201
Batch 02 – CAT 03 (2026) – MCQ Paper.....203
Batch 02 – CAT 03 (2026) – MCQ Paper Answers.....209
Batch 02 - CAT 03 (2026) - SEQ Paper.....210
Batch 02 - CAT 03 (2026) - SEQ Paper Answers.....212
Batch 02 – CAT 03 (2026)– OSPE Paper.....215
Batch 02 – CAT 03 (2026) – OSPE Paper Answers.....225
BATCH 01 2nd MBBS (PROPER) PAPERS WITH ANSWERS.....230
Batch 01- 2nd MBBS Proper (2025) – MCQ Paper.....231
Batch 01- 2nd MBBS Proper (2025) – MCQ Paper Answers.....244
Batch 01- 2nd MBBS Proper (2025) - SEQ Paper.....246
Batch 01- 2nd MBBS Proper (2025) - SEQ Paper Answers.....248
Batch 01- 2nd MBBS Proper (2025)– OSPE Paper.....254
Batch 01- 2nd MBBS Proper (2025) – OSPE Paper Answers.....257

BATCH 01 2nd MBBS (REPEAT) PAPERS WITH ANSWERS.....259
Batch 01- 2nd MBBS Repeat (2026)– MCQ Paper 260
Batch 01- 2nd MBBS Repeat (2026) – MCQ Paper Answers 273
Batch 01- 2nd MBBS Repeat (2026)- SEQ Paper 275
Batch 01- 2nd MBBS Repeat (2026) - SEQ Paper Answers.....278
Batch 01 – 2nd MBBS Repeat (2026)– OSPE Paper.....286
Batch 01 – 2nd MBBS Repeat (2026)– OSPE Paper Answers.....306

ANATOMY PRACTICE MCQs (T/F & SBR)

(1) Head & Neck

(2) Central Nervous System

(3) Lower Limb

Head & Neck Practice MCQs

(1) True or False regarding a typical cervical vertebra?

(A) It is smaller than a typical lumbar vertebra.
(B) It has a foramen in each of its transverse process.
(C) It articulates with a vertebra next above by synovial joints.
(D) It has anterior and posterior tubercles on each of its transverse processes.
(E) It has a smaller vertebral foramen than a typical lumbar vertebra.

(2) Which arteries provide the blood supply to scalp?

(A) Supratrochlear artery
(B) Supraorbital artery
(C) Occipital artery
(D) Superficial temporal artery
(E) Facial artery

(3) True or False regarding the venous dural sinuses?

(A) These are lined by pia matter.
(B) Mandibular division of trigeminal nerve lies in the lateral wall of cavernous sinus.
(C) Sphenoparietal sinus drains into superior sagittal sinus.
(D) CSF is absorbed into venous circulation through arachnoid granulation.
(E) Walls are lined by thick fibrous tissue and epithelium.

(4) True or False regarding the platysma muscle?

(A) It lies deep to the deep fascia.
(B) Deltoid muscle makes up part of its origin.
(C) It is innervated by the facial nerve.
(D) It is pierced by the internal jugular vein.
(E) It is denervated making a transverse incision in the lower neck.

(5) True or False regarding the occipitofrontalis muscle?

(A) It has no bony attachment.
(B) Its nerve supply is derived from the facial and trigeminal nerves.
(C) Its occipital belly attached to the external occipital protuberance and superior nuchal line.
(D) It is supplied by the posterior auricular and temporal branches of the facial nerve.
(E) Its occipital belly is smaller than frontal belly.

(6) True or False regarding the external jugular vein?

(A) It receives blood from the retromandibular vein.
(B) It pierces the investing layer of the deep cervical fascia.
(C) It accompanies with no nerves.
(D) It drains to the subclavian vein.
(E) It is separated from the surface of the sternocleidomastoid by deep cervical fascia.

(7) True or False regarding prevertebral fascia?

(A) It blends with the esophagus.
(B) It fuses with carotid sheath.
(C) It encloses the thyroid gland.
(D) It attaches to the base of the skull.
(E) It blends with the arch of the aorta.

(8) True or False regarding carotid sheath?

(A) It fuses with adventitia of aorta.
(B) It is thin on its lateral side.
(C) It contains external carotid artery.
(D) It is posterior to phrenic nerve.
(E) It is anterior to sympathetic chain.

(9) What structures are transmitted through the temporal bone?

(A) The trigeminal nerve
(B) Facial nerve
(C) Vestibulocochlear
(D) Greater petrosal nerve
(E) Accessory nerve

(10) What are the structures contained in the Carotid triangle?

(A) Bifurcation of the common carotid artery
(B) Posterior auricular artery
(C) Hypoglossal nerve
(D) Anterior jugular vein
(E) External laryngeal nerve

(11) True or False regarding contents of the posterior triangle?

(A) External jugular vein
(B) Transverse fascial artery
(C) Hypoglossal nerve
(D) Superior root of ansa cervicalis
(E) Inferior belly of omohyoid

(12) True or False regarding the maxillary air sinus?

(A) It is projected laterally into the zygomatic process of the maxilla.
(B) The posterior superior alveolar nerve grooves its posterior wall.
(C) Inferior orbital nerve grooves its upper surface.
(D) It has a small opening high on its medial wall.
(E) It is related to the upper incisor.

(13) True or False regarding the nasal cavity & Paranasal sinuses?

(A) Vestibule of the nose lined by respiratory epithelium.
(B) Sphenoethmoidal recess lies below superior concha.
(C) Posterior ethmoidal sinus opens into superior meatus.
(D) Frontal sinus is absent at birth.
(E) Frontal sinus infection spreads to maxillary sinus.

(14) True or False regarding the lateral wall of the nose?

(A) The sphenoid sinus opens into the sphenoethmoidal sinus.
(B) The ethmoidal bulla is situated under the middle concha.
(C) The hiatus semilunaris is a groove below the ethmoidal bulla.
(D) Frontal air sinus opens into the superior meatus.
(E) The nasolacrimal duct opens anterior to the infundibulum of hiatus semilunaris.

(15) Which of the following bones form the orbit?

(A) Frontal bone
(B) Zygomatic bone
(C) Sphenoid bone
(D) Ethmoid bone
(E) Vomer

(16) True or False regarding the regarding the eye?

(A) Cornea has no blood vessels.
(B) Optic disc is in the retina.
(C) Aqueous humor flows into the sinus venosus sclera.
(D) Dilator pupillae is supplied by the parasympathetic nerves.
(E) Oculomotor nerve supplies the parasympathetic nerves to the smooth muscles of the eye.

(17) True or False regarding the cornea?

(A) It is an avascular structure.
(B) It is nourished by the aqueous humor.
(C) It is developed by the ectoderm.
(D) Tear firm is indispensable to integrity of it.
(E) It has pigmented cells.

(18) True or False regarding the eye muscles?

(A) When superior oblique is paralyzed, eye cannot move upward and laterally.
(B) Lateral rectus is supplied by the trochlear nerve.
(C) Inferior oblique is attached to the sclera behind the coronal equator of the eye ball.
(D) Action of the oblique muscles is tested by asking the patient first look medially.
(E) All the muscles of the eye ball are attached to a tendinous ring.

(19) Which muscles are supplied by the oculomotor nerve?

(A) Superior oblique
(B) Superior rectus
(C) Inferior rectus
(D) Involuntary portion of levator palpebrae superioris
(E) Lateral rectus

(20) True or False regarding the extraocular muscles of the eye?

(A) The superior oblique muscle is supplied by the superior division of the oculomotor nerve.
(B) Downward and medial movement is mediated by the inferior rectus muscle.
(C) Downward and medial movement is mediated by the superior rectus muscle.
(D) Medial movement is mediated through the oculomotor nerve.
(E) The lateral rectus is supplied by the trochlear nerve.

(21) True or False regarding the tongue?

(A) The foramen caecum is at the apex of the sulcus terminalis on the dorsum of the tongue, towards the back.
(B) Its musculature is derived by from the suboccipital somites.
(C) Its all muscles are supplied by the XII cranial nerve.
(D) It has about 12 circumvallate papillae situated just behind the sulcus terminalis.
(E) It is attached to the mental spine of the mandible by the genioglossus.

(22) True or False regarding the tongue?

(A) The tip has bilateral lymph drainage which crosses midline.
(B) The taste and general sensation from the posterior 1/3 are carried by the 9th cranial nerve.
(C) It has genioglossus which prevents the tongue been pulled posteriorly.
(D) The posterior part lymph drains to the deep cervical lymph nodes.
(E) Lingual vein lies deep to it.

(23) What are the structures transmitted through the superior orbital fissure transmits?

(A) Optic Nerve
(B) The nasocilliary, oculomotor, and abducent nerves within the common tendinous ring
(C) Maxillary Nerve
(D) Ophthalmic Nerve
(E) Ophthalmic vein

(24) True or False regarding the movements of the larynx?

(A) The cricothyroid muscle lengthens the vocal folds.
(B) The vocalis muscle shortens and tenses the folds.
(C) Thyroarytenoid muscle adducts the vocal folds.
(D) Approximation of the vestibular folds is mediated by the aryepiglottic muscle.
(E) The posterior cricoarytenoid muscles abduct the vocal cord.

(25) True or False regarding the thyroid gland?

(A) It is covered by the prevertebral fascia.
(B) It is partly developed from the endoderm.
(C) It is related to the internal laryngeal and external laryngeal nerves.
(D) It is supplied by branches of the external carotid and subclavian arteries.
(E) It drains totally into the internal jugular vein.

(26) True or False regarding the thyroid gland?

(A) The isthmus lies on the arch of the cricoid cartilage.
(B) The thyroid venous plexus is between the capsule of the prevertebral fascia and the gland.
(C) Superior thyroid artery divides into its terminal branches before it enters the gland.
(D) Superior parathyroid develops from the third pharyngeal pouch.
(E) The thyroid veins have connections with the internal vertebral venous plexus.

(27) What are the structures that superior constrictor of the pharynx attaches to?

(A) Stylohyoid ligament
(B) Pterygomandibular raphe
(C) Hyoid bone
(D) Pharyngeal raphe
(E) Pterygoid hamulus

(28) A young boy was presented to the hospital with an inability to move his neck due to a trauma to the neck. On examination, his neck was turned to the right and his face was turned to the left side. This condition was identified as wry neck. Which one of these muscles was paralyzed in this condition? (SBR)

(A) Right trapezius muscle
(B) Left trapezius muscle
(C) Left sternocleidomastoid
(D) Right sternocleidomastoid
(E) Left scalenus anterior muscle

(29) A 45-year-old man presented with diplopia. His left eye was adducted and abduction is not possible. All the other eye movements are normal in both eyes. What is the nerve damaged? (SBR)

(A) Left abducent nerve
(B) Left oculomotor nerve
(C) Left trochlear nerve
(D) Right oculomotor nerve
(E) Right abducent nerve

(30) Accommodation of the eye occurs due to which action? (SBR)

(A) Contraction of the medial rectus muscle.
(B) Contraction of the papillary muscle.
(C) Constriction of the pupil.
(D) Contraction of medial rectus and ciliary muscles.
(E) Constriction of pupil and contraction of medial rectus and ciliary muscles.

(31) A 45-year-old female underwent a thyroidectomy. The surgeon was careful to preserve the recurrent laryngeal nerve during the procedure. What is the important anatomical relationship to preserve the nerve? (SBR)

(A) It lies within pretracheal fascia.
(B) It is related to the inferior thyroid artery.
(C) It is related to the upper pole of the thyroid gland.
(D) It is immediately posterior to the gland.
(E) It enters the larynx below the inferior constrictor muscle.

Central Nervous System Practice MCQs

(1) True or False regarding the frontal lobe?

(A) It is separated from the ipsilateral temporal lobe by the longitudinal fissure.
(B) Lesion in it causes anti-social behavior.
(C) It has a paracentral lobe.
(D) Broca's area is in the frontal lobe.
(E) The middle cerebral artery supplies the frontal lobe.

(2) True or False regarding the blood supply of the brain?

(A) Occlusion in the basilar artery compromises blood supply to anterior circulation.
(B) Acute occlusion of right vertebral artery compromises posterior circulation.
(C) Middle cerebral artery feed anterior circulation.
(D) Posterior communicating arteries connects the right and left posterior circulations.
(E) Brainstem is supplied by the posterior circulation.

(3) Loss of pain & temperature of the opposite side of the body occurs as a result of a lesion in where?

(A) Posterior column of spinal cord
(B) Lateral part of medulla oblangata
(C) Anterior gray commissure
(D) Anterior limb of internal capsule
(E) Posterior ventral nucleus of the thalamus

(4) What are the connections that globes pallidus includes?

(A) Thalamostriate fibers
(B) Corticostriate fibers
(C) Striatopallidal fibers
(D) Pallidofugal fibers
(E) Nigrostriate fibers

(5) True or False regarding the subarachnoid space?

(A) It contains the circle of Willis.
(B) It does not extend below the L1 vertebral level.
(C) It contains arachnoid granulations.
(D) Rupture of Berry aneurism bleed to subarachnoid space.
(E) Rupture of Berry aneurism bleed to subarachnoid space.

(6) What are the blood vessels that supply the internal capsule?

(A) Anterior cerebral artery
(B) Posterior cerebral artery
(C) Anterior communicating artery
(D) Posterior communicating artery
(E) Anterior choroidal artery

(7) True or False regarding the thalamus?

(A) It is a component of the brainstem.
(B) It consists of group of nuclei.
(C) It is the main emotional center.
(D) It is related to the internal capsule laterally.
(E) It is an important relay station for sensory pathways

(8) True or False regarding the spinal accessory nerve?

(A) It traverses through the foramen magnum.
(B) It accompanies the vagus nerve at the base of the skull.
(C) It pierces sternocleidomastoid.
(D) It is a pure motor nerve.
(E) It is likely to damage during thyroidectomy.

(9) A person was admitted with a heavy blow to the skull and the scan showed an extramural haemorrhage in the pterion area. Which of the following structure is most likely to cause it? (SBR)

(A) Diploic veins
(B) Emissary vein
(C) Middle meningeal artery
(D) Superficial temporal artery
(E) Superior cerebral artery

(10) A 65-year-old female had met a doctor complaining about left side facial nerve paralysis and hearing impairment. Where is the possible site for the injury? (SBR)

(A) In the inner ear.
(B) At the internal auditory meatus.
(C) In the middle ear cavity.
(D) In the stylomastoid foramen.
(E) Within the parotid gland.

Lower Limb Practice MCQs

(1) Which of the following bony parts are palpable?

(A) Head of femur
(B) Ischial spine
(C) Shaft of femur
(D) Anterior inferior iliac spine
(E) Coccyx

(2) True or False regarding the bones of the lower limb?

(A) Femur is the largest bone of the body.
(B) Damaged to the neck of femur can cause avascular necrosis.
(C) Fracture of the distal end of the femur tears the popliteal artery.
(D) Popliteal pulse is difficult to felt in popliteal fossa.
(E) Femoral artery directly lies on the head of the femur.

(3) True or False regarding the mid-thigh region?

(A) The floor of the adductor canal is formed by the adductor magnus.
(B) The roof of the adductor canal is formed by sartorius.
(C) Femoral artery is medial to the femoral vein.
(D) Iliotibial tract is nonexistent.
(E) The gracilis is often supplied by the femoral nerve.

(4) True or False regarding the adductor magnus?

(A) It is pierced by perforating branches of the profunda femoris artery.
(B) There is an opening for the femoral artery.
(C) It extends the hip joint.
(D) It is posterior to the sciatic nerve.
(E) It has ischio-condylar part that supplied by the femoral nerve.

(5) What are the hamstring muscles of lower limb?

(A) Quadrates femoris
(B) Biceps femoris
(C) Sartorius
(D) Semimembranosus
(E) Semitendinosus

(6) True or False regarding the vascular examination of the foot?

(A) Dorsalis pedis is a continuation of the anterior tibial artery.
(B) It is palpated lateral to the extensor hallucis longus tendon.
(C) The posterior tibial artery passes anterior to the medial malleolus.
(D) Absence of the dorsalis pedis pulse always indicates disease.
(E) The posterior tibial artery can be palpated behind the medial malleolus.

(7) A patient with pes planus (flatfoot) is evaluated. Which statements are true?

(A) The medial longitudinal arch is collapsed.
(B) The spring ligament supports the head of the talus.
(C) Tibialis posterior provides dynamic support.
(D) Long plantar ligament supports the medial arch.
(E) Plantar aponeurosis acts as a tie beam.

(8) True or False regarding the medial longitudinal arch?

(A) The talus acts as the keystone.
(B) The spring ligament supports the head of talus.
(C) Tibialis posterior is an important dynamic stabilizer.
(D) The arch is flatter than the lateral longitudinal arch.
(E) Plantar aponeurosis helps maintain the arch.

(9) True or False regarding the lateral longitudinal arch?

(A) It is more rigid and weight-bearing than the medial arch.
(B) The cuboid acts as the keystone.
(C) It is supported by the long plantar ligament.
(D) Peroneus longus contributes to its stability.
(E) It is higher than the medial longitudinal arch.

(10) A patient receives an intramuscular injection in the gluteal region and subsequently develops weakness in knee flexion and foot drop. Which nerve is most likely injured? (SBR)

(A) Superior gluteal nerve
(B) Inferior gluteal nerve
(C) Femoral nerve
(D) Sciatic nerve
(E) Obturator nerve

(11) A 34-year-old man who was subjected to a road traffic accident came to the ward with a fracture in the upper end of the femur. One month later a vascular necrosis had occurred in the head of the femur. Which is the most likely site of fracture? (SBR)

(A) Middle of the neck of femur
(B) Base of neck of femur
(C) Pertrochanteric fracture
(D) Subcapital fracture
(E) Subtrochanteric fracture

(12) 30-year-old married women was admitted to the surgical casualty wit fever & left knee joint pain. She also had pain in the left iliac fossa region. On examination her knee joint was perfectly normal. Ultrasound examination of the pelvis reveled an inflammatory mass pressing a nerve. What is the nerve most likely to be affected? (SBR)

(A) Femoral nerve
(B) Obturator nerve
(C) Sciatic nerve
(D) Saphenous nerve
(E) Posterior cutaneous nerve of thigh

(13) A 70-year-old man was fallen down from a height and L3 spinal segment was damaged. The neurologist used lower limb movements to assess the level of the spinal cord injury. Which of the following movement, that is not affected by the above injury? (SBR)

(A) Ankle dorsiflexion
(B) Ankle plantarflexion
(C) Big toe extension
(D) Knee extension
(E) Flexion of hip

(14) A 12-year-old girl who presented with right side flexed hip deformity was found to have pain on extension of hip. Ultra sound examination revealed an inflamed retrocecal appendix. The cause for flexed hip deformity was suspended to be due to irritation of underlying structure by inflamed appendix. What is the most likely structure to be irritated? (SBR)

(A) Right femoral nerve
(B) Right hip joint
(C) Right obturator internus muscle
(D) Right psoas muscle
(E) Right quadratus lumborum

(15) A football player sustains a knee injury with the foot fixed on the ground and the body twisting. He presents with pain and locking of the knee. Which structure is most commonly injured? (SBR)

(A) Lateral meniscus
(B) Medial meniscus
(C) Anterior cruciate ligament
(D) Posterior cruciate ligament
(E) Fibular collateral ligament

(16) surgeon is operating in the popliteal fossa and wants to avoid injury to the most superficial structure. Which of the following structures is most superficial in the popliteal fossa? (SBR)

(A) Popliteal artery
(B) Popliteal vein
(C) Tibial nerve
(D) Common peroneal nerve
(E) Small saphenous vein

(17) A 35-year-old man suddenly feels a "snap" in the back of his ankle while playing badminton. He is unable to stand on tiptoe, and squeezing the calf produces no plantarflexion. Which structure is most likely injured? (SBR)

(A) Plantaris tendon
(B) Achilles tendon
(C) Tibialis posterior tendon
(D) Flexor hallucis longus tendon
(E) Peroneus longus tendon

(18) A patient complains of burning pain and numbness over the sole of the foot. Symptoms worsen at night. On examination, percussion behind the medial malleolus reproduces the pain. Which nerve is affected? (SBR)

(A) Deep peroneal nerve
(B) Superficial peroneal nerve
(C) Tibial nerve
(D) Sural nerve
(E) Saphenous nerve

(19) A 28-year-old male sustains a fracture at the neck of the fibula. He presents with foot drop and sensory loss over the dorsum of the foot. Which nerve is most likely injured? (SBR)

(A) Tibial nerve
(B) Deep peroneal nerve
(C) Superficial peroneal nerve
(D) Common peroneal nerve
(E) Sural nerve

ANATOMY PRACTICE MCQs ANSWERS (T/F & SBR)

(1) Head & Neck

(2) Central Nervous System

(3) Lower Limb

Head & Neck Practice MCQs Answers

(1)

(A) **T -** Lumbar is the largest typical vertebrae.
(B) **T -** where vertebral artery travel.
(C) **F -** Synovial joints above + 2 synovial joints below.
(D) **T**
(E) **F -** Vertebral canal becomes progressively smaller from above downwards.

Readily identified by the foramen transversarium perforating the transverse processes. These foramina transmit the vertebral artery (except that of C7), the vertebral veins and sympathetic fibers. Spines are small and bifid (except C1 and C7, which are single). Articular facets are relatively horizontal.

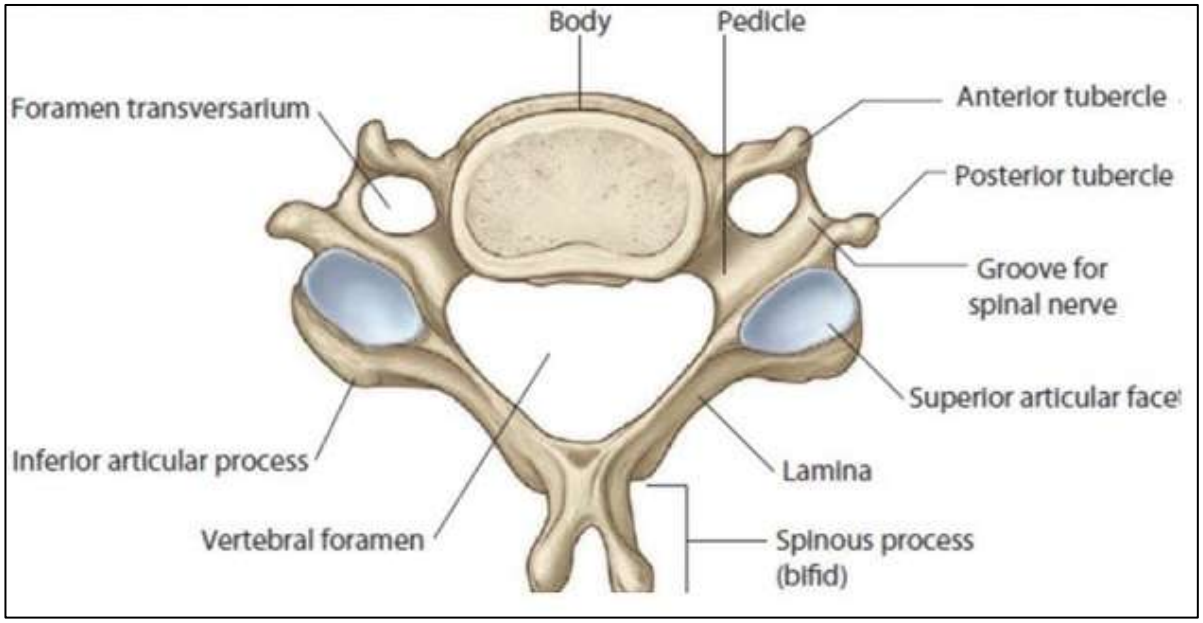

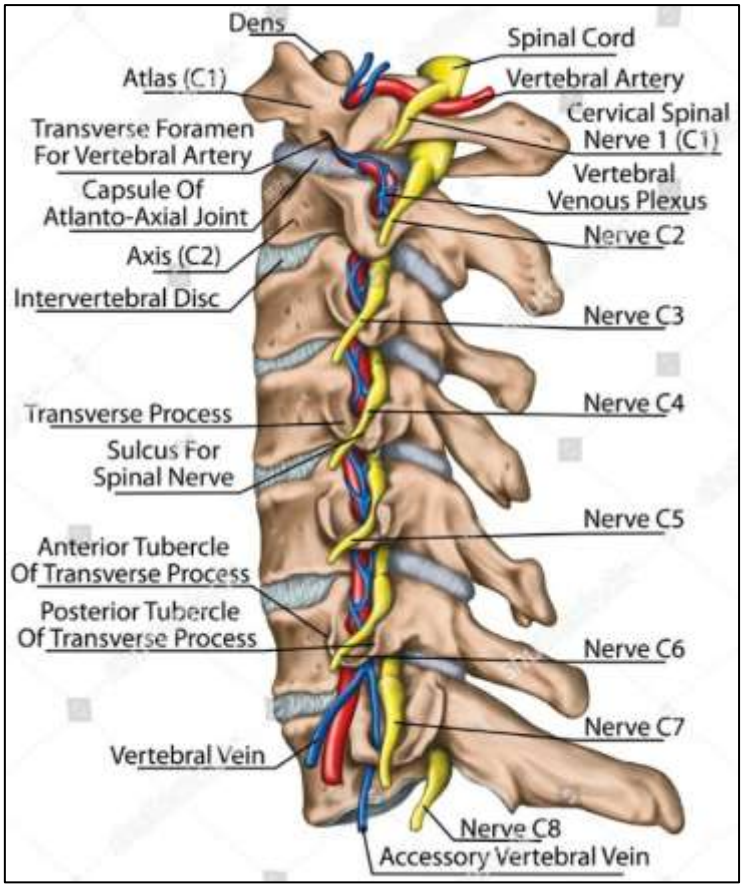

(2)

(A) **T**
(B) **T**
(C) **T**
(D) **T**
(E) **F**

In addition: zygomaticotemporal artery (maxillary) and posterior auricular artery (ECA). in short, it is anastomosis between ICA and ECA.

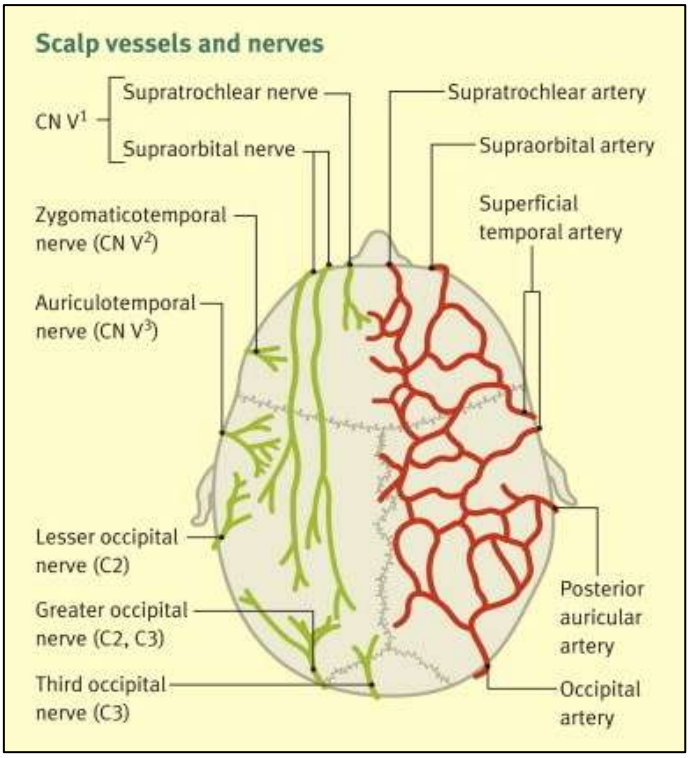

(3)

(A) **F -** The venous sinuses lie between layers of the Dura matter.

(B) **F -** Trochlear, Oculomotor, maxillary, ophthalmic nerves lie in the lateral wall of the cavernous sinus.

(C) **F -** Drain to anterior part of the cavernous sinus.

(D) **T**

(E) **T**

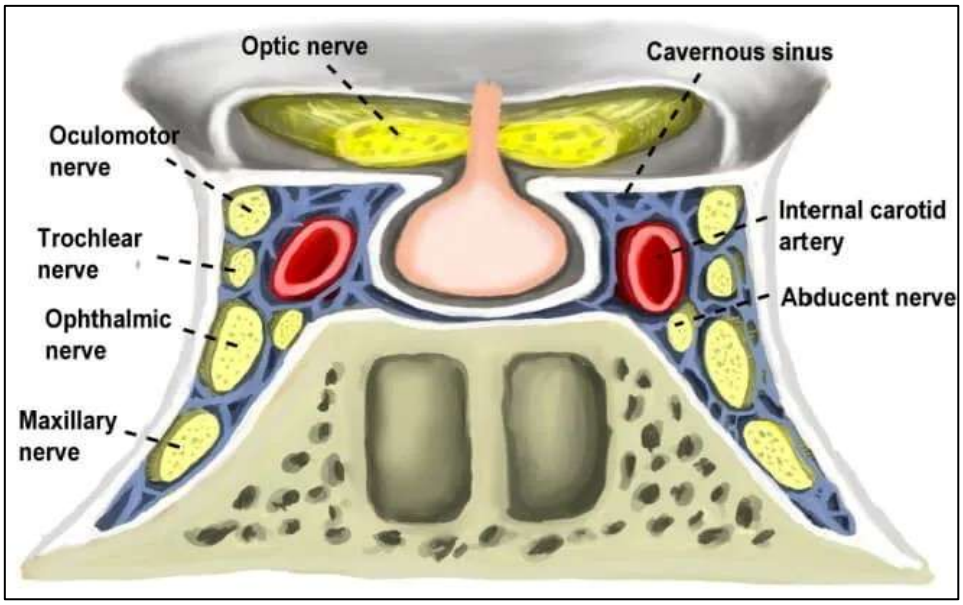

(4)

(A) **F** - Platysma is a thin sheet of muscle lies in the superficial fascia.
(B) **F** - Platysma takes origin from the skin and fascia over the upper parts of pectoralis major and deltoid.
(C) **T** - Nerve supply by the cervical branch of facial nerve.
(D) **F** - Skin laceration over the mandible or upper part of the neck may distort the shape of mouth. (Damage to facial nerve)
(E) **F**

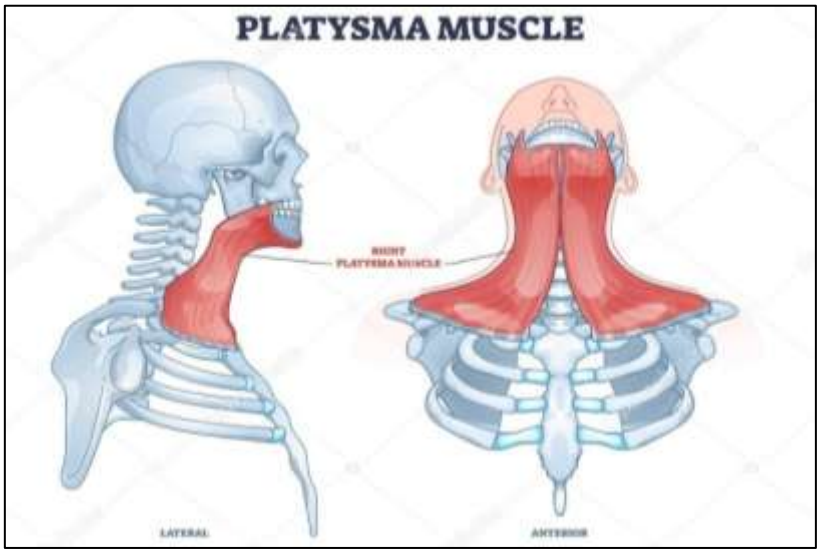

(5)

(A) **F** - Frontal belly has no bony attachment but occipital belly attaches lateral 2/3 of superior nuchal line.
(B) **F** - Derived only from facial neve.
(C) **F**
(D) **T**
(E) **T** - No attachment to external occipital protuberance. Temporal branch supplies the frontal belly. Posterior auricular branch supplies the occipital belly. Occipital bellies are shorter & narrower than frontal bellies.

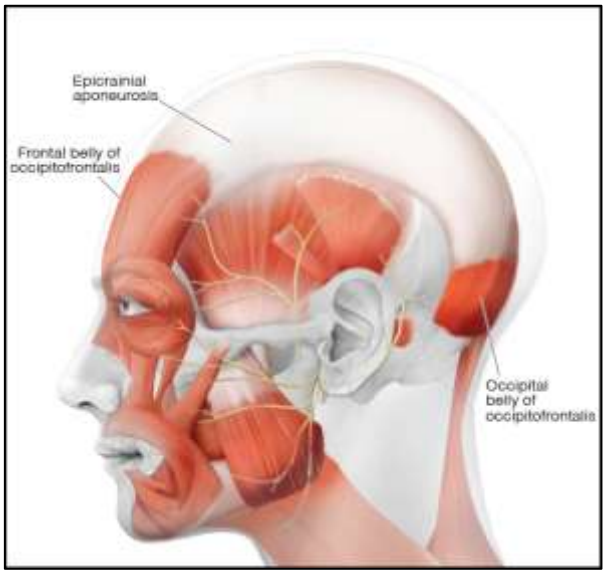

(6)

(A) **T**

(B) **T** - Structures piercing investing fascia → External & anterior jugular vein

(C) **F** - Branches of cervical plexus (all) Lesser occipital, great auricular, transverse cervical, supraclavicular nerves.

(D) **T** - Retro mandibular vein = superficial temporal vein + maxillary vein

- Anterior branch drains to → facial vein → internal jugular vein
- Posterior branch drain to → external jugular vein → subclavian vein

(E) **F** - The external jugular vein runs superficial to sternocleidomastoid within the superficial fascia, not separated from it by deep cervical fascia (except at its terminal point where it pierces the investing layer)

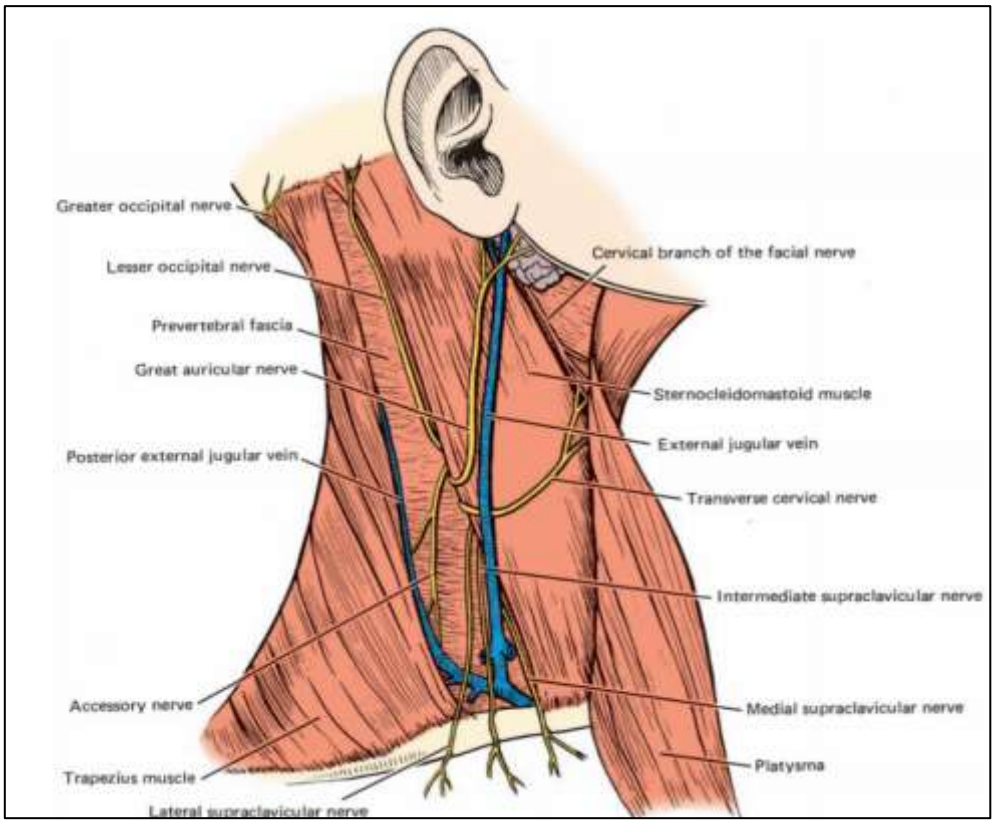

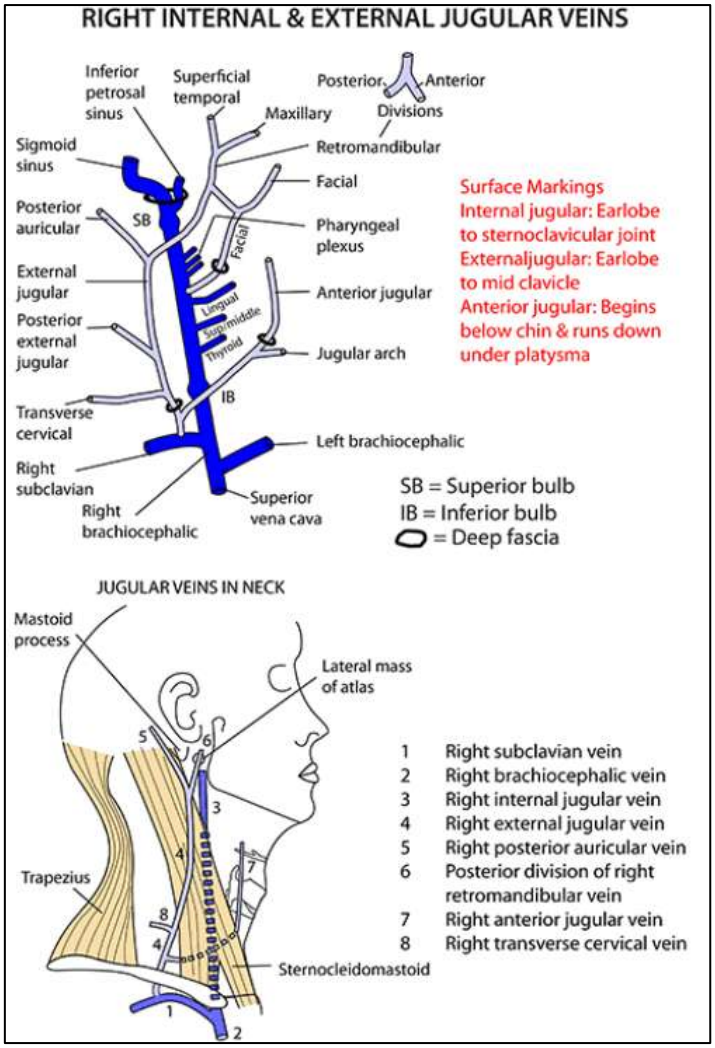

(7)

(A) **F**

(B) **F** - Pretracheal fascia blends with carotid sheaths.

(C) **F** - Pretracheal fascia.

(D) **T**

(E) **F** - Anterior longitudinal ligament of T4.

A firm, tough membrane that lies in front of the prevertebral muscles Superiorly-fixed to the cranial base Inferiorly- blends with the endothoracic fascia peripherally and fuses with the anterior longitudinal ligament centrally at approximately the body of T4 Laterally-extends over scalenus anterior, scalenus medius and levator scapulae.

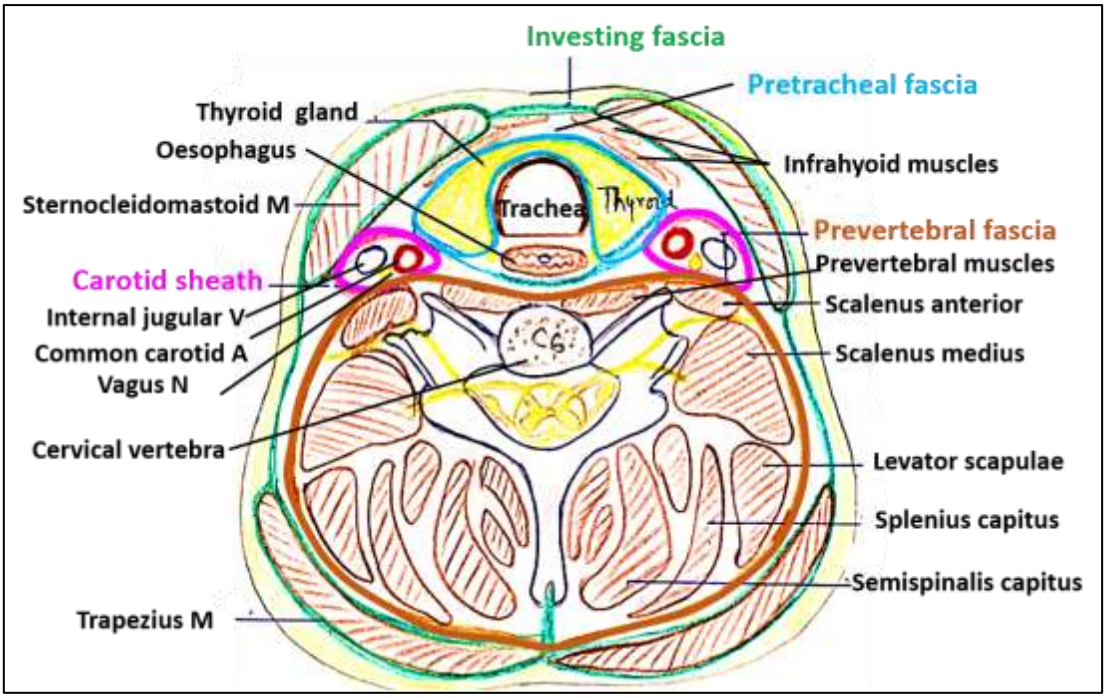

(8)

(A) **T**

(B) **T -** To allow internal jugular vein to expand with blood flow.

(C) **F** - common and internal carotid arteries only.

(D) **F** - Phrenic nerve is posterior to carotid sheath in prevertebral compartment.

(E) **T** - Sympathetic chain lie behind carotid sheath and in front of prevertebral fascia.

An areolar tissue covering that surrounds - Carotid arteries (common and internal), Internal jugular vein & Vagus nerve. Thin where it overlies internal jugular vein. Attached to the base of the skull at the margins of the carotid canal. Continued downward to the aortic arch. Cervical sympathetic trunk related posteriorly.

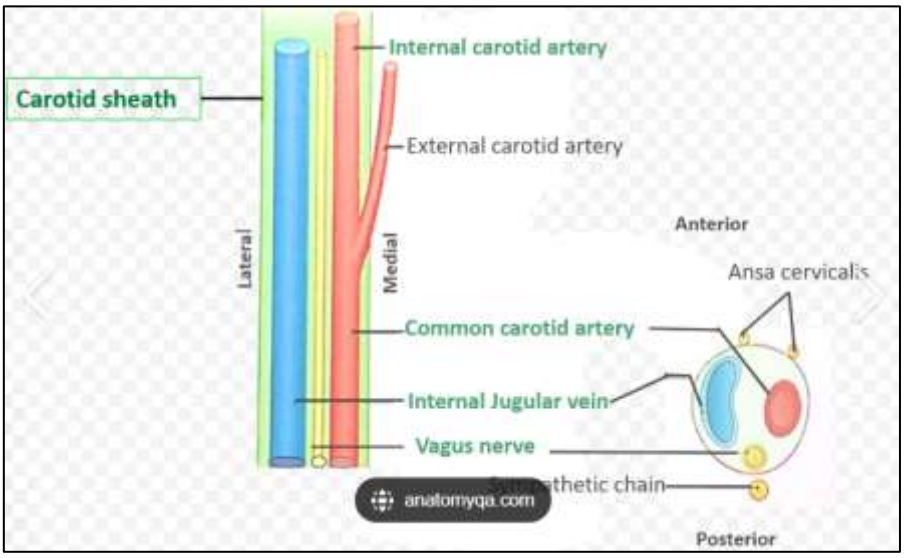

(9)

(A) **F** - The trigeminal nerve does not pass through the temporal bone. Its ganglion lies in Meckel's cave near the petrous apex, but it is not transmitted by the temporal bone.

(B) **T** - The facial nerve passes through the internal acoustic meatus and facial canal within the temporal bone.

(C) **T** - It passes through the internal acoustic meatus in the petrous part of the temporal bone.

(D) **T** - A branch of the facial nerve; it arises in the facial canal and passes through the temporal bone.

(E) **F** - It exits the skull via the jugular foramen (shared by temporal and occipital bones), but it is not considered to be transmitted by the temporal bone itself.

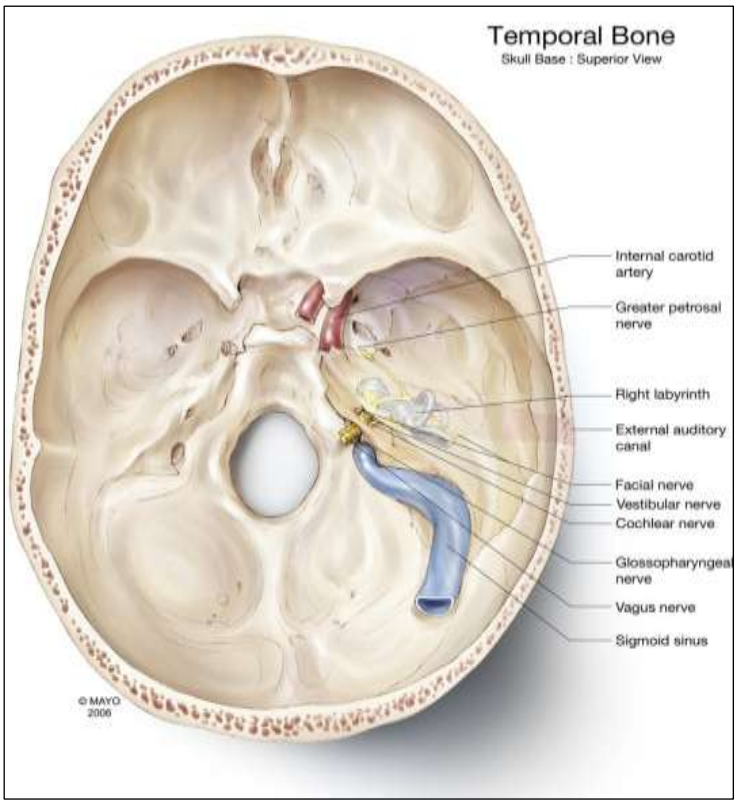

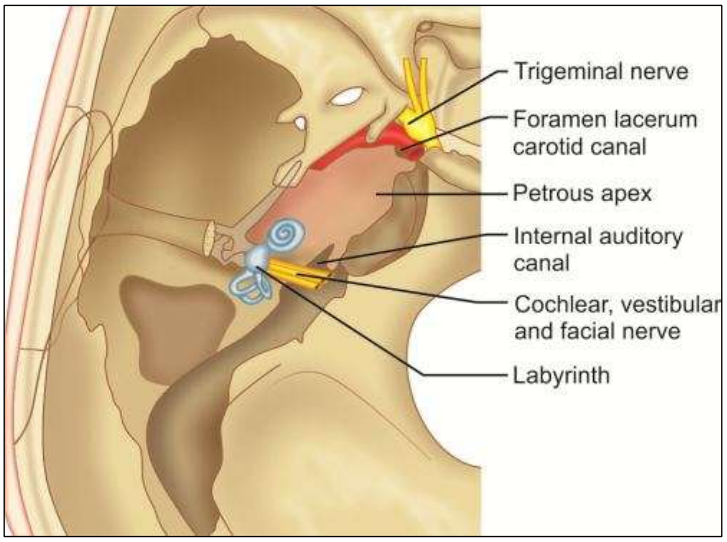

(10)

(A) **T** - The common carotid artery divides into external and internal carotid arteries within the carotid triangle.

(B) **F** - It contains branches of external carotid artery except posterior auricular artery & terminal branches.

(C) **T** - The hypoglossal nerve crosses both internal and external carotid arteries in the carotid triangle.

(D) **F** - The anterior jugular vein lies in the anterior triangle near the midline, not in the carotid triangle.

(E) **T** - A branch of the superior laryngeal nerve; it descends in the carotid triangle close to the superior thyroid artery.

Contents of carotid triangle: -

Vessels

- Bifurcation of common carotid artery
- Branches of external carotid artery except posterior auricular artery and terminal branches
- Lingual, facial and superior thyroid veins

Nerves

- Hypoglossal nerve
- Internal and external laryngeal nerves
- Superior root of ansa cervicalis

Lymph

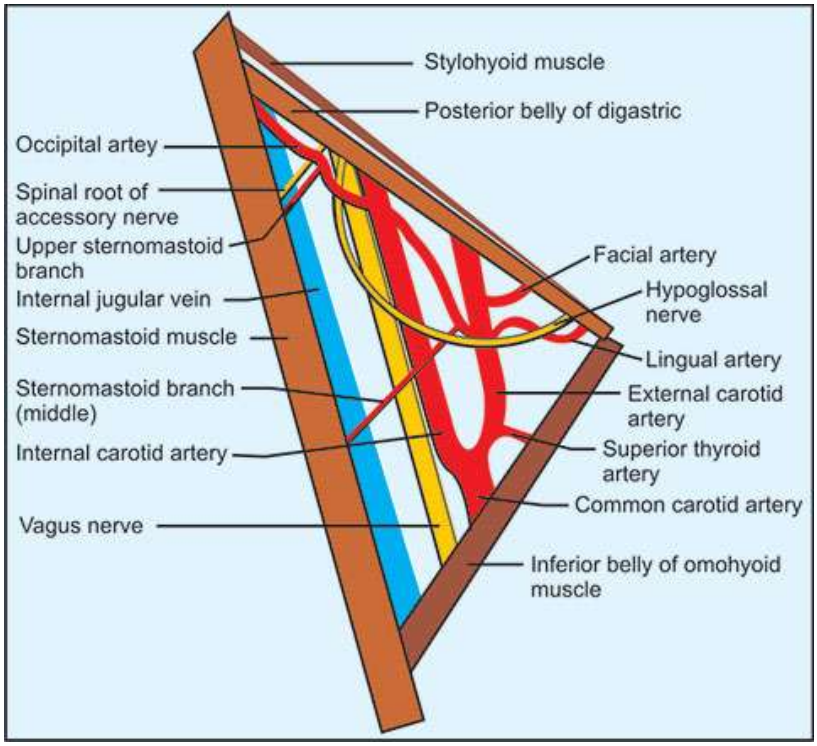

(11)

(A) **T**
(B) **F**
(C) **F**
(D) **F**
(E) **T**

Contents of posterior triangle:

- Terminal part of external jugular vein
- Transverse cervical artery
- 3rd part of subclavian artery
- Spinal accessory nerve
- Subclavian vein
- Inferior belly of omohyoid

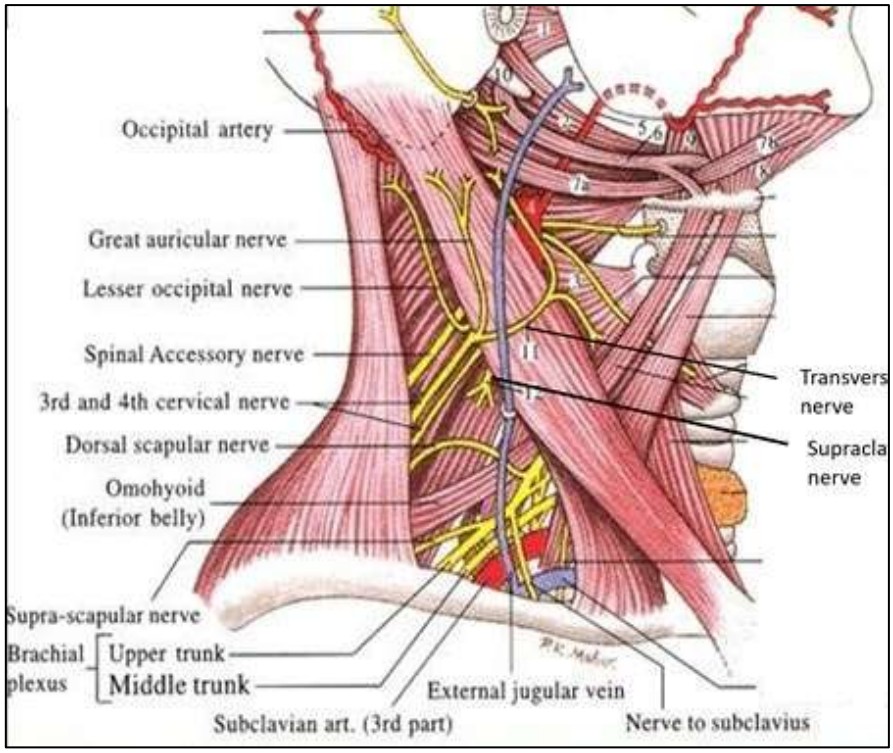

(12)

(A) **T** - Apex (towards laterally) is the zygomatic process of maxilla.

(B) **T -** The posterior wall is formed by the infra temporal surface of the maxilla: it contains alveolar canals that may produce ridges in the sinus and that also conduct the posterior superior alveolar vessels and nerves to the molar teeth.

(C) **T -** The roof of the sinus forms the major part of the fl oor of the orbit. It contains the infraorbital canal.

(D) **T** - To infundibulum that opens to middle meatus via hiatus semilunaris.

(E) **F** - Only first molar and second premolar.

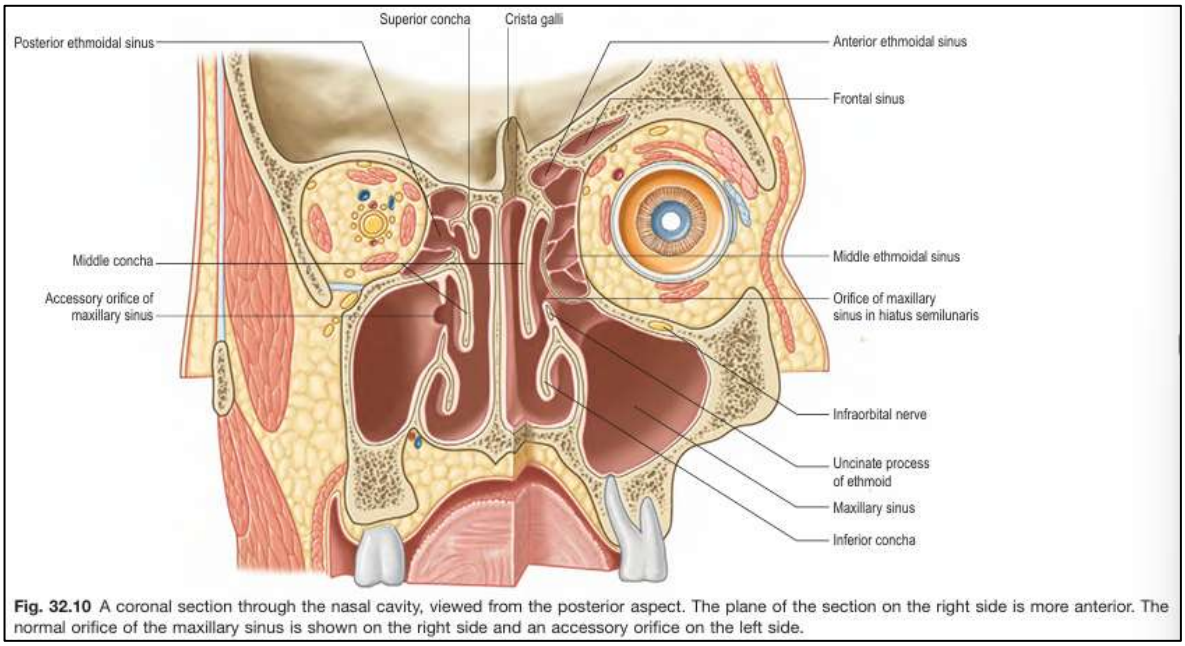

Fig. 32.10 A coronal section through the nasal cavity, viewed from the posterior aspect. The plane of the section on the right side is more anterior. The normal orifice of the maxillary sinus is shown on the right side and an accessory orifice on the left side.

(13)

(A) **F** - The vestibule is lined by stratified squamous epithelium with vibrissae, sebaceous and sweat glands.

(B) **F** - It lies above the superior concha.

(C) **T**

(D) **T** - It develops after birth and becomes radiologically visible around 5–6 years. Spread is more commonly from the frontal sinus to the orbit. Frontal and maxillary sinuses do not directly communicate.

(E) **F**

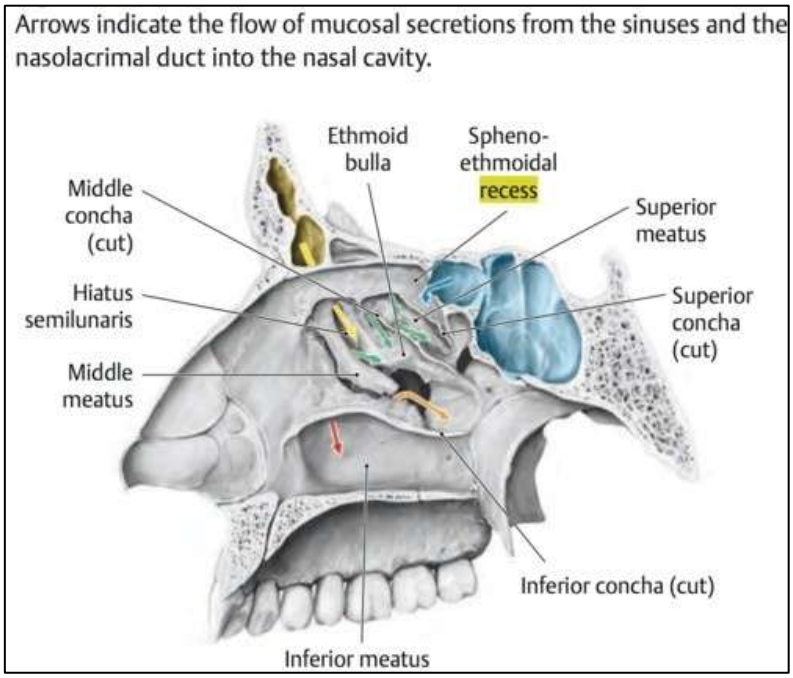

(14)

(A) **F** - To the sphenoethmoidal recess.

(B) **T**

(C) **F** - Anterior to ethmoidal bulla.

(D) **F** - To the middle meatus through the frontonasal duct.

(E) **F** - Hiatus semilunaris is in the middle meatus.

Nasolacrimal duct → inferior nasal meatus under inferior conchae

Frontonasal duct → middle meatus

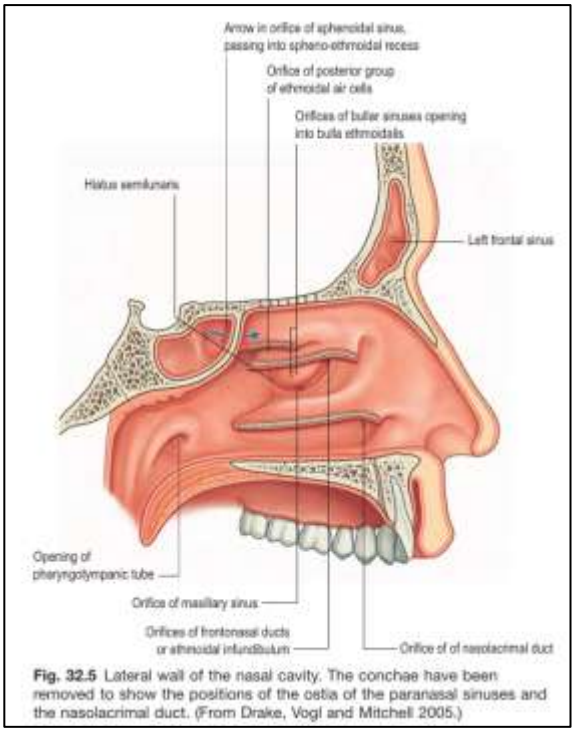

Fig. 32.5 Lateral wall of the nasal cavity. The conchae have been removed to show the positions of the ostia of the paranasal sinuses and the nasolacrimal duct. (From Drake, Vogl and Mitchell 2005.)

(15)

(A) **T**
(B) **T**
(C) **T**
(D) **T**
(E) **F**

Roof - orbital plate of frontal bone, lesser wing of sphenoid
Floor – Maxilla, Zygomatic bone
Medial wall – frontal process of maxilla, Lacrimal bone, orbital plate of ethmoid, body of sphenoid
Lateral wall – greater wing of sphenoid, frontal process of zygomatic bone

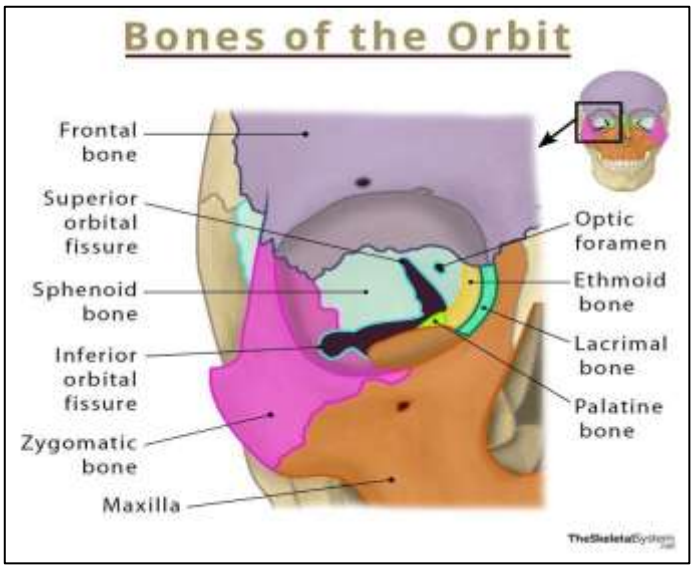

(16)

(A) **T** - Cornea is avascular; it gets nutrition from aqueous humor and tears.
(B) **T** - Optic disc (blind spot) is part of the retina where optic nerve fibers exit.
(C) **T** - Aqueous humor drains via trabecular meshwork - sinus venosus sclera (canal of Schlemm).
(D) **F** - Dilator pupillae is supplied by sympathetic nerves. (Parasympathetic supplies sphincter pupillae.)
(E) **T** - CN III carries parasympathetic fibers (via Edinger–Westphal nucleus to ciliary ganglion) to, sphincter pupillae, ciliary

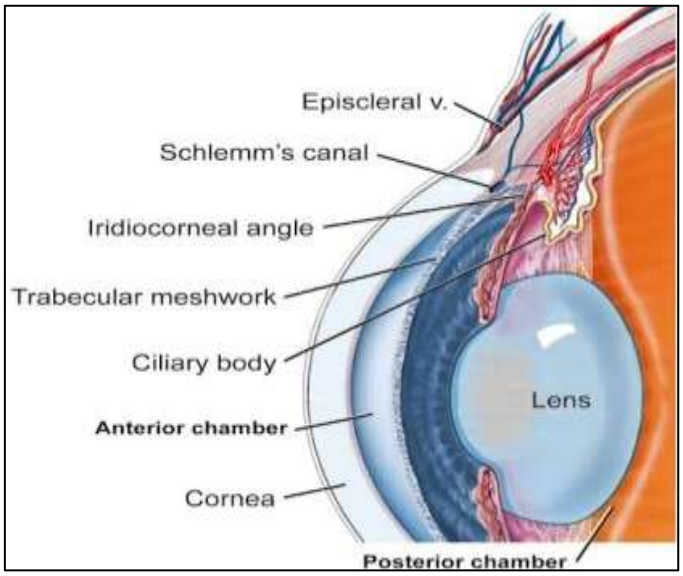

(17)

(A) **T** - completely avascular.
(B) **T**
(C) **T** - Ectoderm + mesoderm
(D) **T**
(E) **F** - Pigmented cells present in the iris.

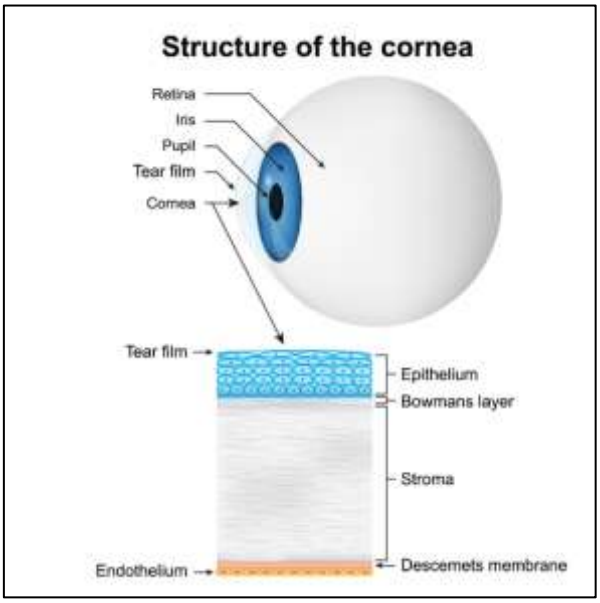

(18)

(A) **F** - Superior oblique muscle rotates eyeball so that cornea looks downward and laterally.
(B) **F** - Lateral rectus is supplied by abducent nerve.
(C) **T** - All recti attach anterior to the equator. Both oblique muscles insert posterior to the equator on the sclera.
(D) **T** - Oblique muscles act most effectively when the eye is adducted.
So, to test,
Superior oblique - look medially then down
Inferior oblique - look medially then up
(E) **F** - The 4 recti arise from a common tendinous ring. Superior oblique arises from sphenoid bone and inferior oblique arises from the floor of the orbit.

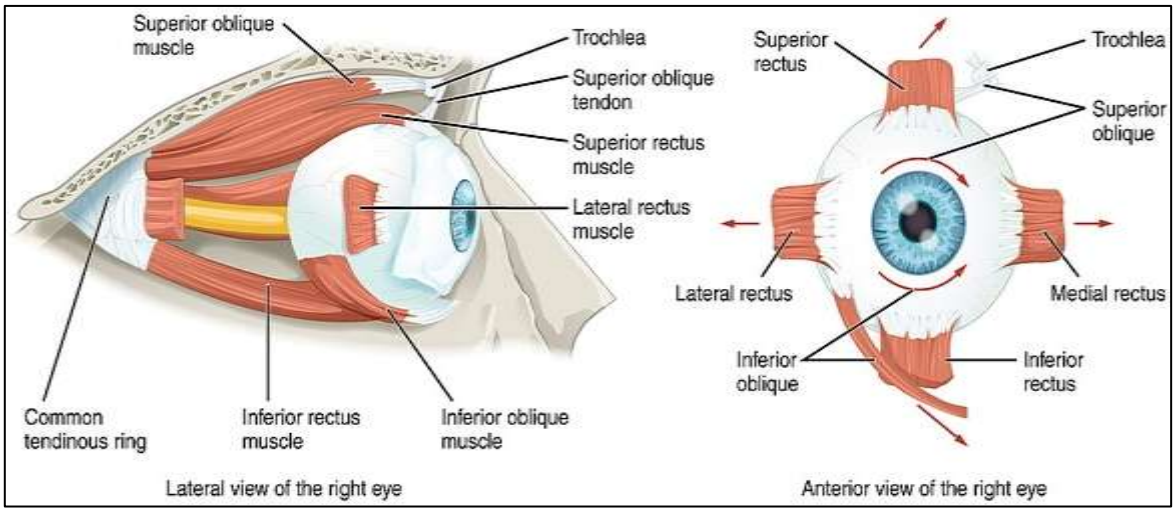

(19)

(A) **F**
(B) **T**
(C) **T**
(D) **F**
(E) **F**

Oculomotor nerve supplies,

- Superior rectus
- Inferior rectus
- Medial rectus
- Inferior oblique
- Levator palpebrae superioris (skeletal/voluntary part)
- Parasympathetic fibers to sphincter pupillae & ciliary muscle (via ciliary ganglion)

Superior oblique is supplied by Trochlear nerve (CN IV).
Lateral rectus is supplied by Abducens nerve (CN VI).

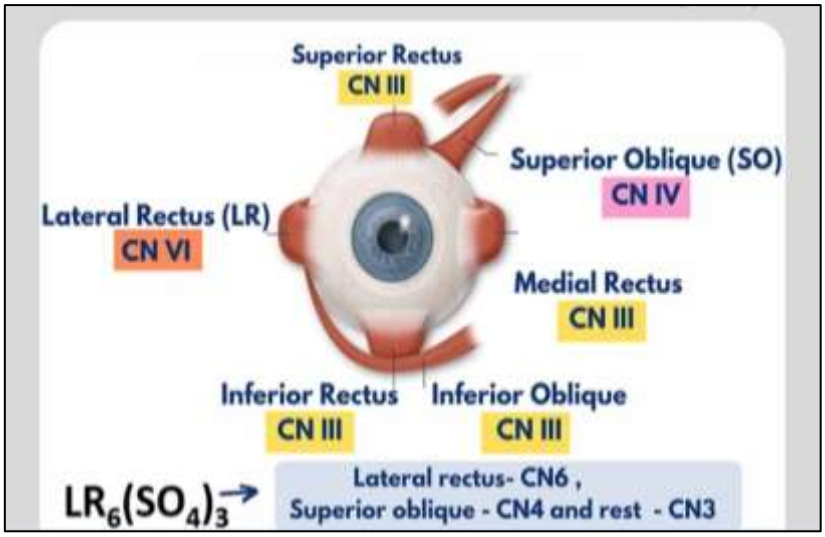

(20)

(A) **F** - Trochlear nerve

(B) **T**

(C) **F**

(D) **T**

SR : elevate/adduct/in torsion

IR : depress/adduct/extorsion

SO : depress/abduct/in torsion

IO : elevate/abduct/extorsion

(E) **F** - Abducent nerve

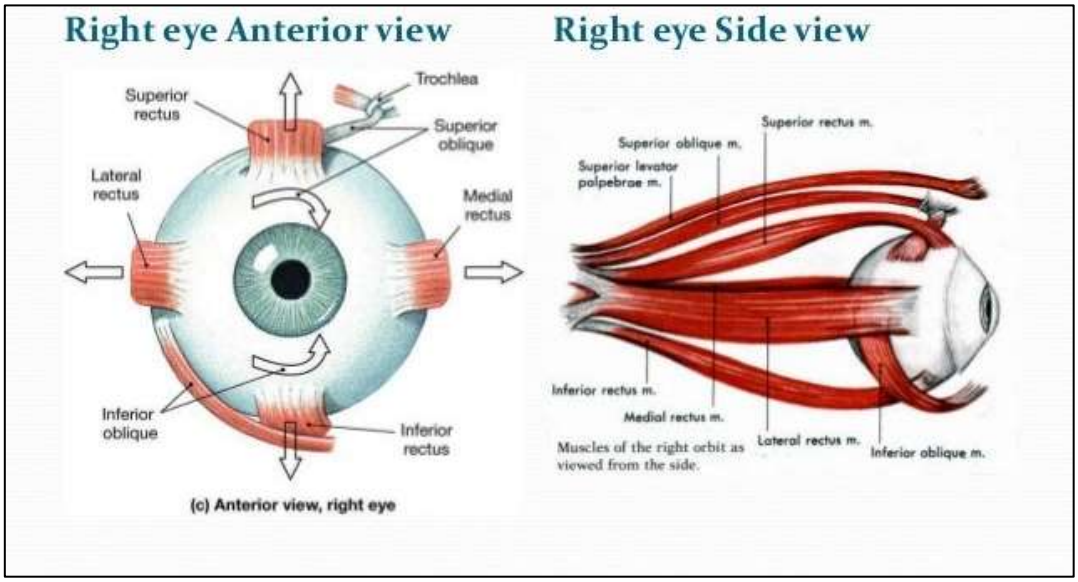

(21)

(A) **T**

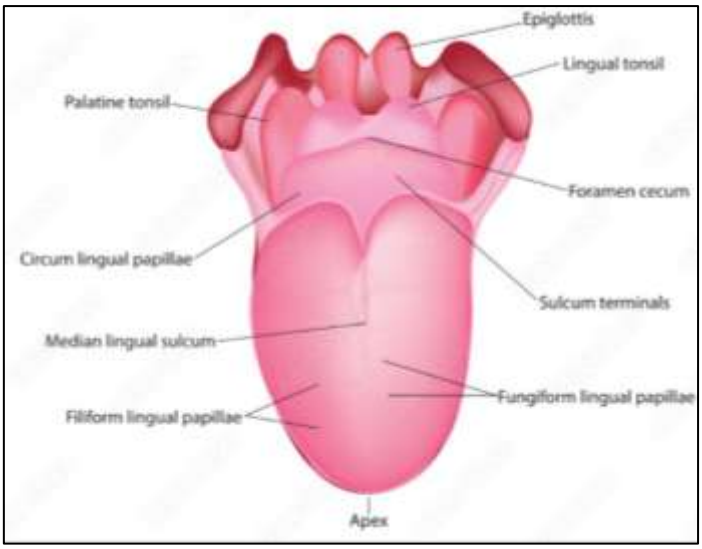

(B) **T** - All muscles except palatoglossus is from migrating myotomes.

(C) **F** – Palatoglossus is supplied by vagus nerve.

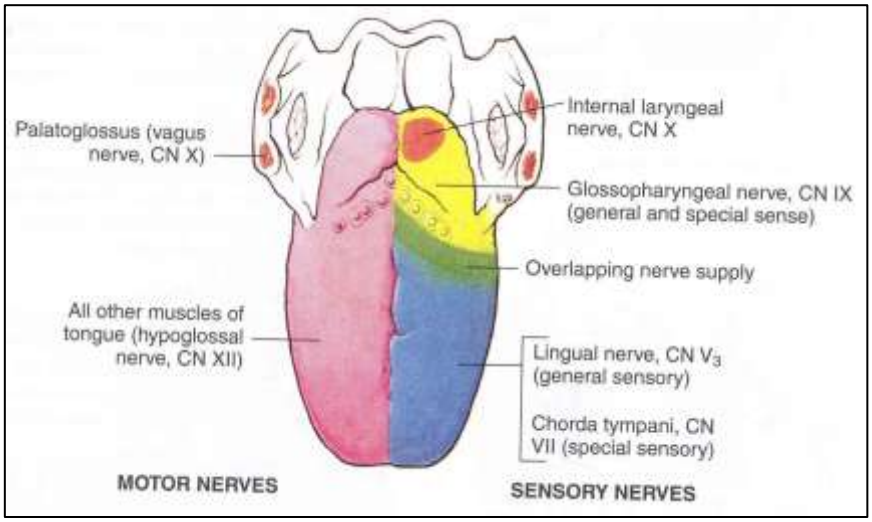

(D) **F** - In front of.

(E) **T** - To superior mental spines.

(22)

(A) **T** - The tip of the tongue drains bilaterally to submental lymph nodes, so spread can cross the midline.

(B) **T** - Glossopharyngeal nerve (CN IX) carries both general sensation and taste from the posterior one-third.

(C) **T** - Genioglossus protrudes the tongue and prevents it from falling backward, especially important in airway patency.

(D) **T** - Posterior one-third drains mainly to deep cervical nodes (especially jugulodigastric).

(E) **F** - The deep lingual vein lies superficial on the undersurface of the tongue (visible clinically), not deep.

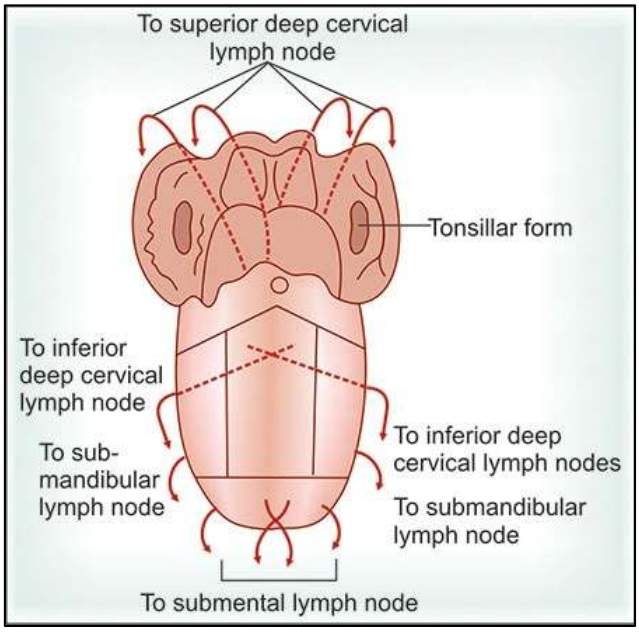

(23)

(A) **F**
(B) **T**
(C) **F**
(D) **T**
(E) **T**

Structures are classically arranged in relation to the common tendinous ring.

Structures OUTSIDE the Common Tendinous Ring

- Lacrimal nerve – branch of ophthalmic division (V_1)
- Frontal nerve – V_1
- Trochlear nerve (CN IV)
- Superior ophthalmic vein
- Recurrent meningeal branch of the lacrimal artery

Structures INSIDE the Common Tendinous Ring

- Superior division of the Oculomotor nerve (CN III)
- Inferior division of Oculomotor nerve (CN III)
- Nasociliary nerve (branch of V_1)
- Abducens nerve (CN VI)
- Sympathetic root to ciliary ganglion (from internal carotid plexus, via nasociliary)

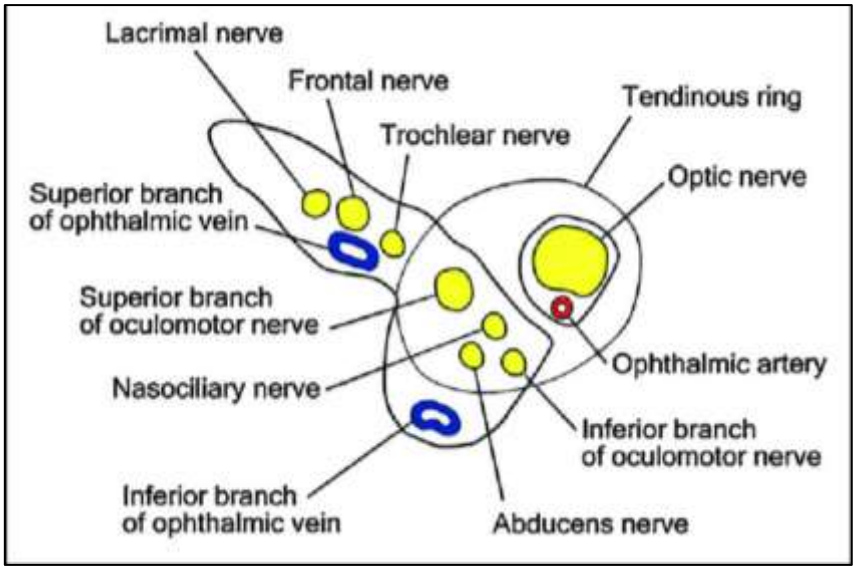

(24)

(A) **T -** By forward & downward rotation of thyroid cartilage at cricothyroid joint.

(B) **F -** Vocalis - shorten and relax vocal ligaments, thereby altering the pitch of voice.

(C) **F -** Thyroarytenoid shortens and relaxes.

(D) **T -** Arey epiglottic muscle → close the laryngeal inlet.

(E) **T -** Only muscle to abduct the vocal folds and open the glottis.

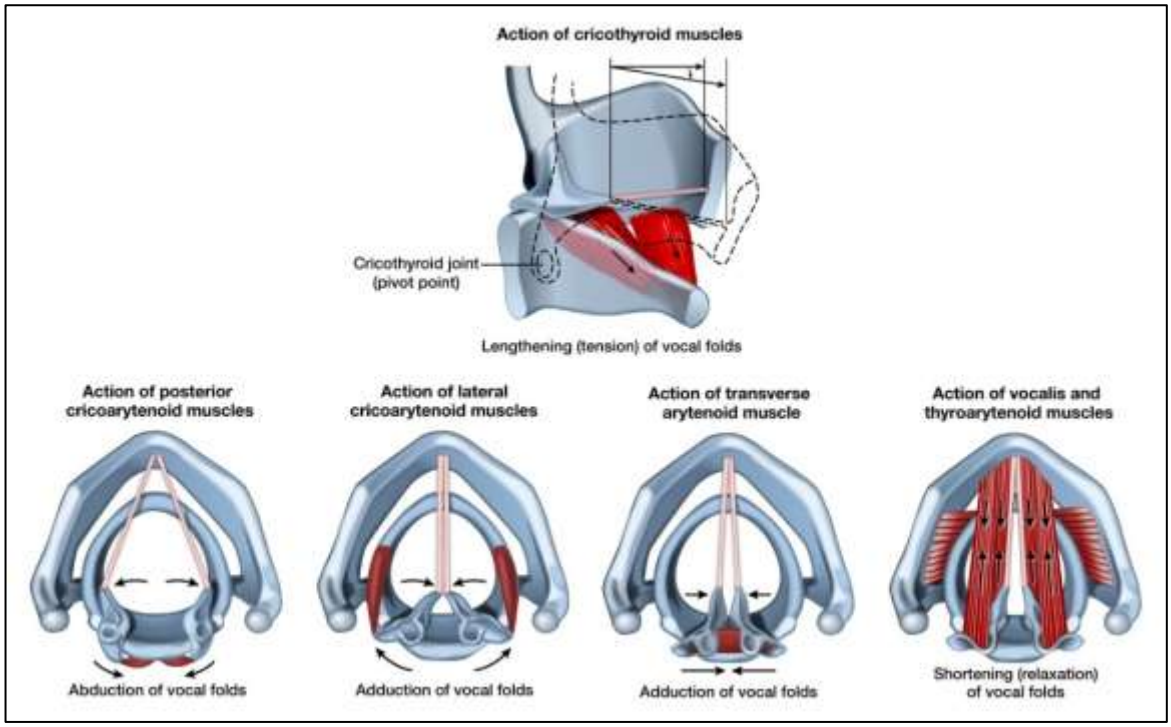

(25)

(A) **F** - Covered by a true & false capsule.

(B) **T**

(C) **F**

(D) **T**

Subclavian → thyrocervical trunk → Inferior thyroid
External carotid → superior thyroid

(E) **T**

Superior thyroid vein → internal jugular vein
Middle thyroid vein → internal jugular vein
Inferior thyroid vein → left brachiocephalic vein

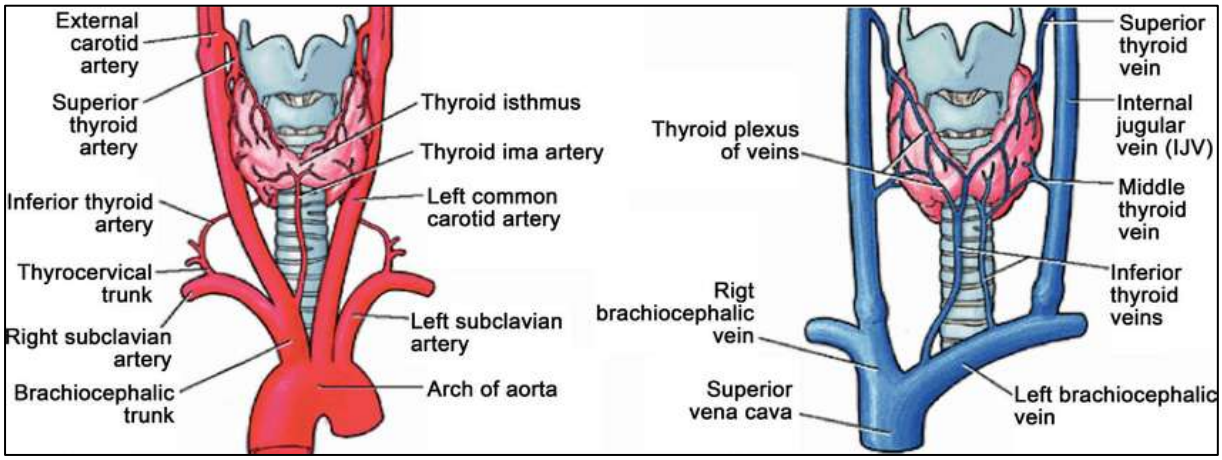

(26)

(A) **F** - It is below the cricoid cartilage.

(B) **F** - The venous plexus lies between the true capsule and the false capsule (pretracheal fascia).

(C) **F** - The superior thyroid artery (from ECA) usually divides into anterior and posterior branches near or within the upper pole of the gland, not well before entering it. Clinically important due to relation with external laryngeal nerve.

(D) **F** - Superior parathyroid gland arises from the 4th pharyngeal pouch. Inferior parathyroid gland arises from the 3rd pharyngeal pouch.

(E) **F** - Thyroid veins drain into,

- Superior thyroid vein drain into Internal Jugular vein.
- Middle thyroid vein drain into Internal Jugular vein.
- Inferior thyroid vein drain into Brachiocephalic vein.

Connection with vertebral venous plexus is not a recognized standard feature.

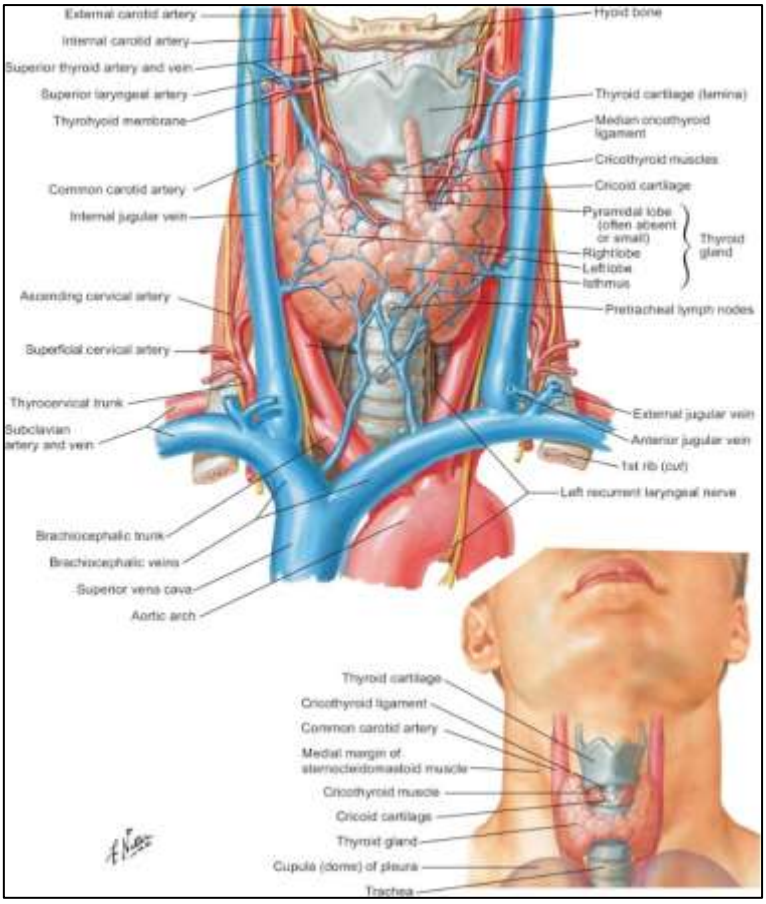

(27)

(A) **F**
(B) **T**
(C) **F**
(D) **T**
(E) **T**

The superior constrictor muscle is a quadrilateral, thin muscle of the upper pharynx that initiates swallowing by narrowing the pharyngeal cavity.

- It originates from the lower part of the medial pterygoid plate, pterygoid hamulus, pterygomandibular raphe, and mandibular mylohyoid line.
- It inserts posteriorly into the median pharyngeal raphe and the pharyngeal tubercle of the occipital bone.

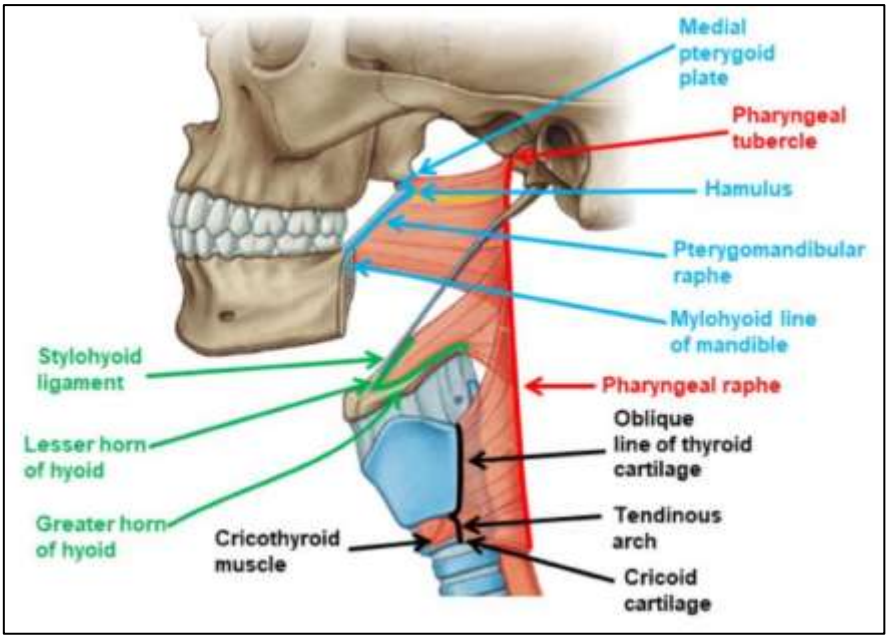

(28) **C**

Wry neck is due to shortening of sternocleidomastoid muscle, head is bent to the affected side and face turns upwards and to the opposite side.

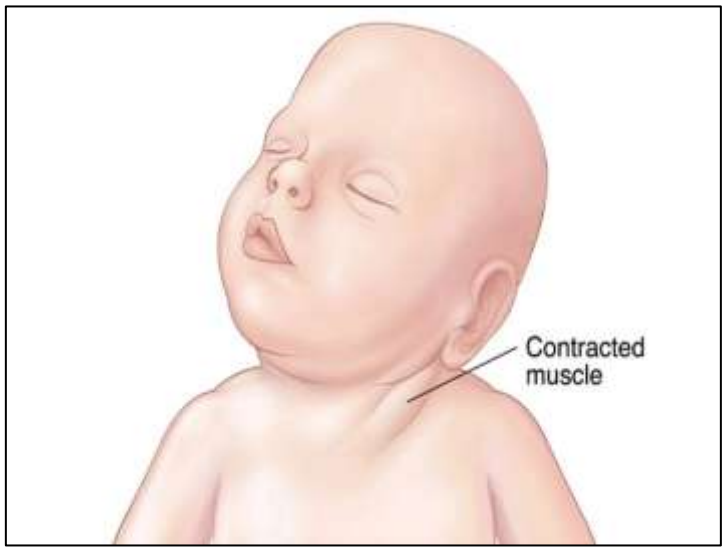

(29) **A**

The adduction of eye of this patient is caused by the unopposed action of medial rectus muscle due to the paralysis of lateral rectus of the left eye.
Lateral rectus is supplied by the abducent nerve.

So, the answer should be left abducent nerve. Since the other movements of the eye aren't affected trochlear & oculomotor nerve can be excluded.

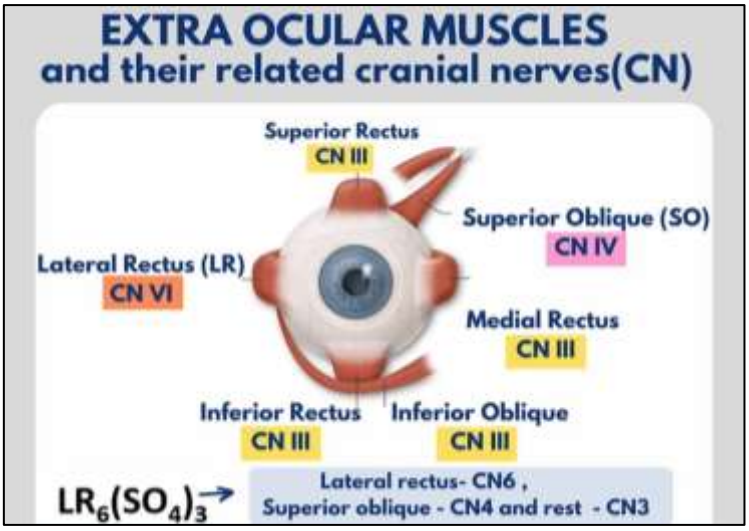

(30) **E**

Near response (Accommodation reflex) consists of 3 components:

- Convergence - contraction of medial recti
- Lens thickening - contraction of ciliary muscle
- Miosis - constriction of pupil

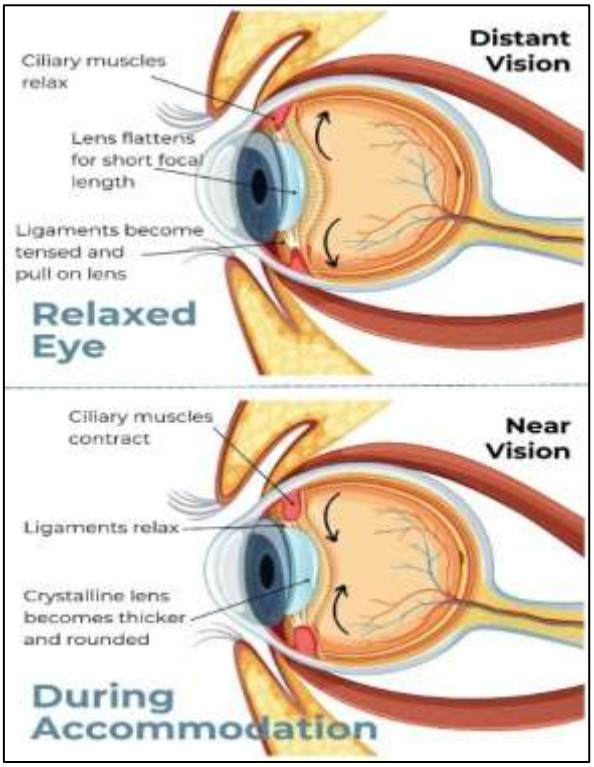

(31) **B**

The inferior thyroid artery and the recurrent laryngeal nerve lie close to each other near the thyroid gland. During thyroidectomy, the inferior thyroid artery is ligated away from the gland to preserve the recurrent laryngeal nerve.

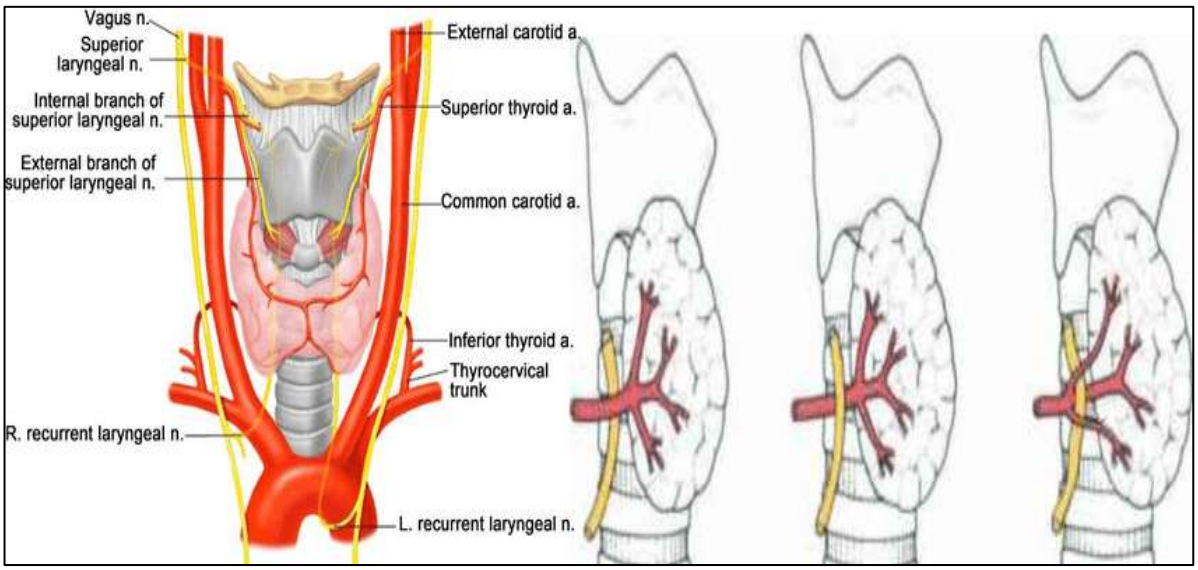

Central Nervous System Practice MCQs Answers

(1)

(A) **F** - Separated from temporal lobe by lateral sulcus, not longitudinal fissure.
(B) **T** - Frontal lobe lesions (especially prefrontal cortex) → personality changes, disinhibition, antisocial behavior**.**
(C) **T** - Contains paracentral lobule on medial surface.
(D) **T** - Broca's area lies in the frontal lobe (dominant hemisphere).
(E) **F** - Not entirely supplied by MCA — ACA also supplies medial frontal lobe**.**

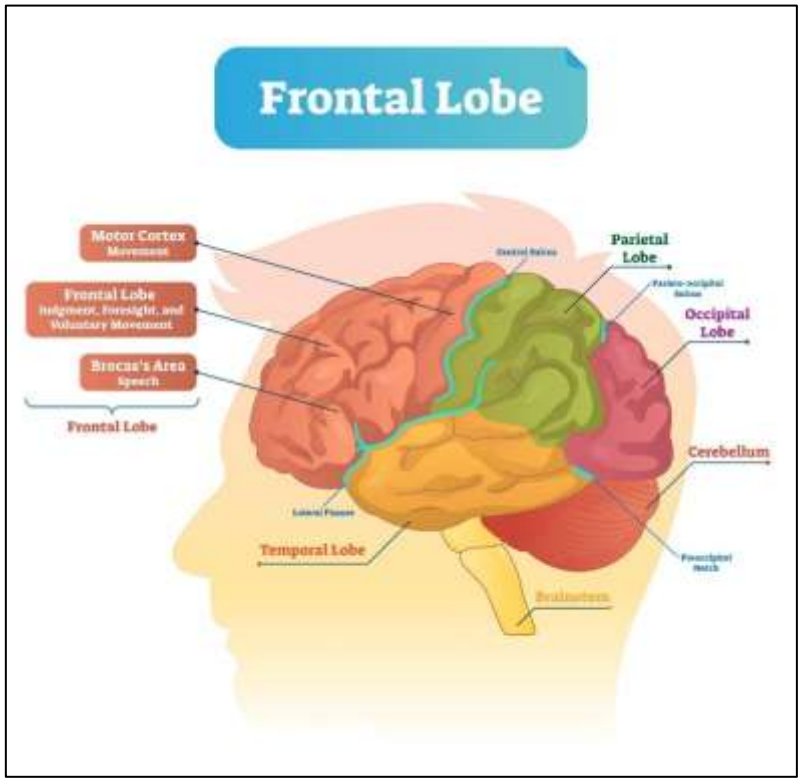

(2)

(A) **F** - The posterior circulation is supplied by two Vertebral arteries. If one is occluded, the other vertebral artery usually compensates, so posterior circulation is not necessarily compromised.
(B) **F** - The posterior circulation is supplied by two Vertebral arteries. If one is occluded, the other vertebral artery usually compensates, so posterior circulation is not necessarily compromised.
(C) **T** - The Middle cerebral artery is a major branch of the Internal carotid artery and is part of the anterior circulation.
(D) **F**- The Posterior communicating artery connects posterior circulation to anterior circulation, not the right and left posterior sides.
(E) **T** - The brainstem receives blood from branches of the Vertebral arteries and Basilar artery.

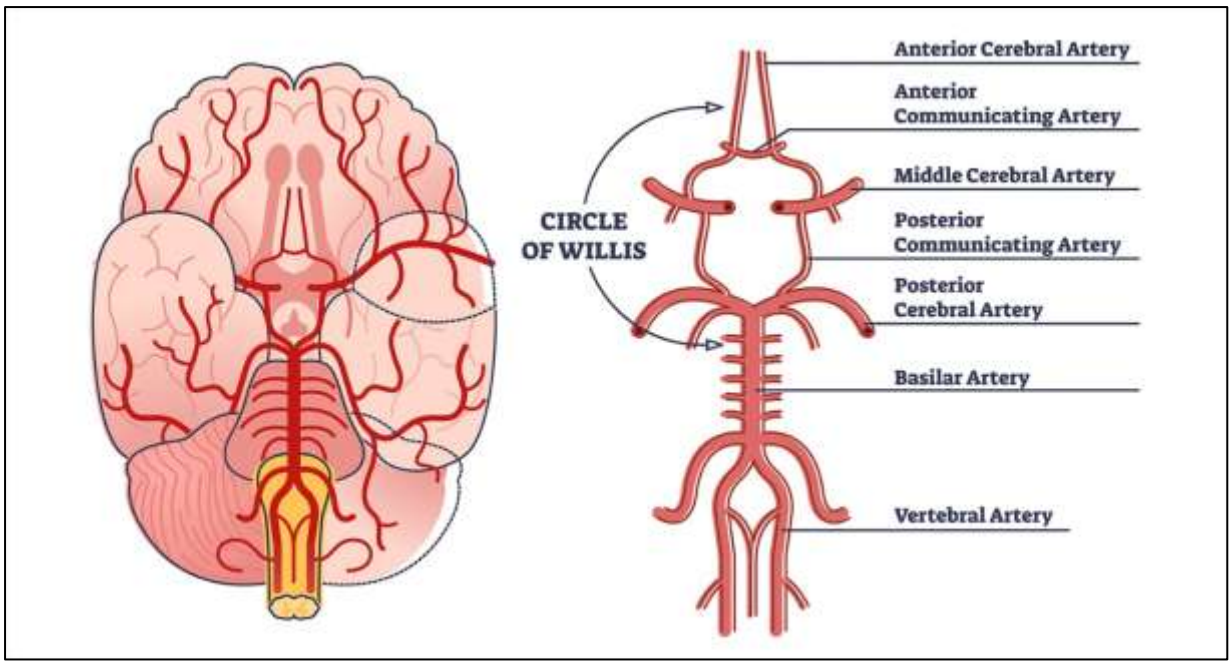

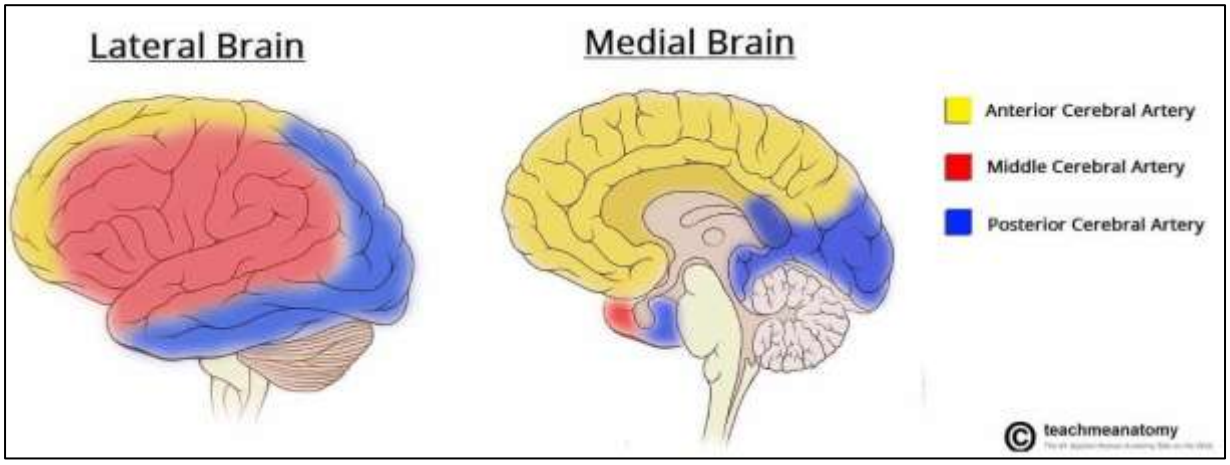

(3)

(A) **F** - The Posterior column of the spinal cord carries fine touch, vibration, and proprioception.

(B) **T**

(C) **F** - The Anterior gray commissure is the crossing point of spinothalamic fibers. The lesion causes bilateral segmental loss of pain and temperature.

(D) **F** - The Anterior limb of the internal capsule mainly contains frontopontine and thalamocortical fibers, not major sensory pathways.

(E) **T**

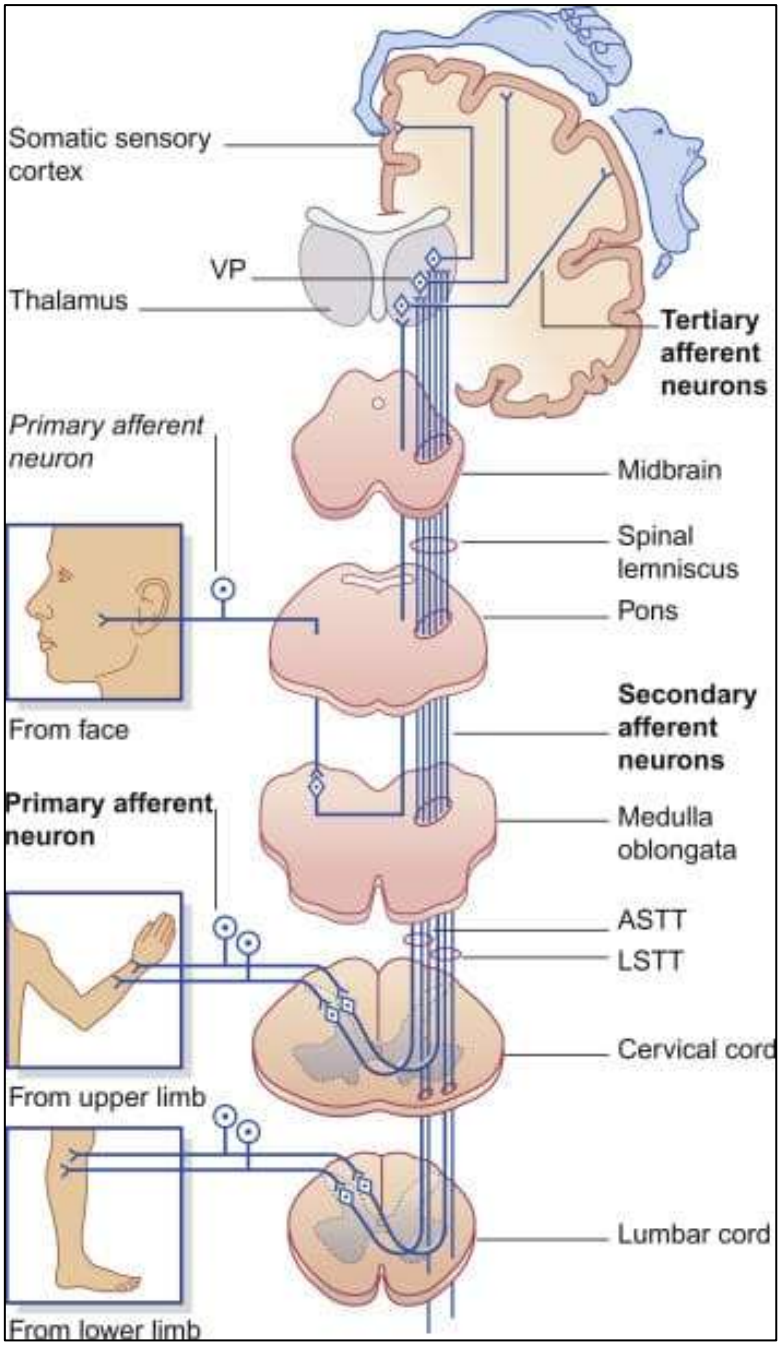

(4)

(A) **F**
(B) **F**
(C) **T**
(D) **T**
(E) **F**

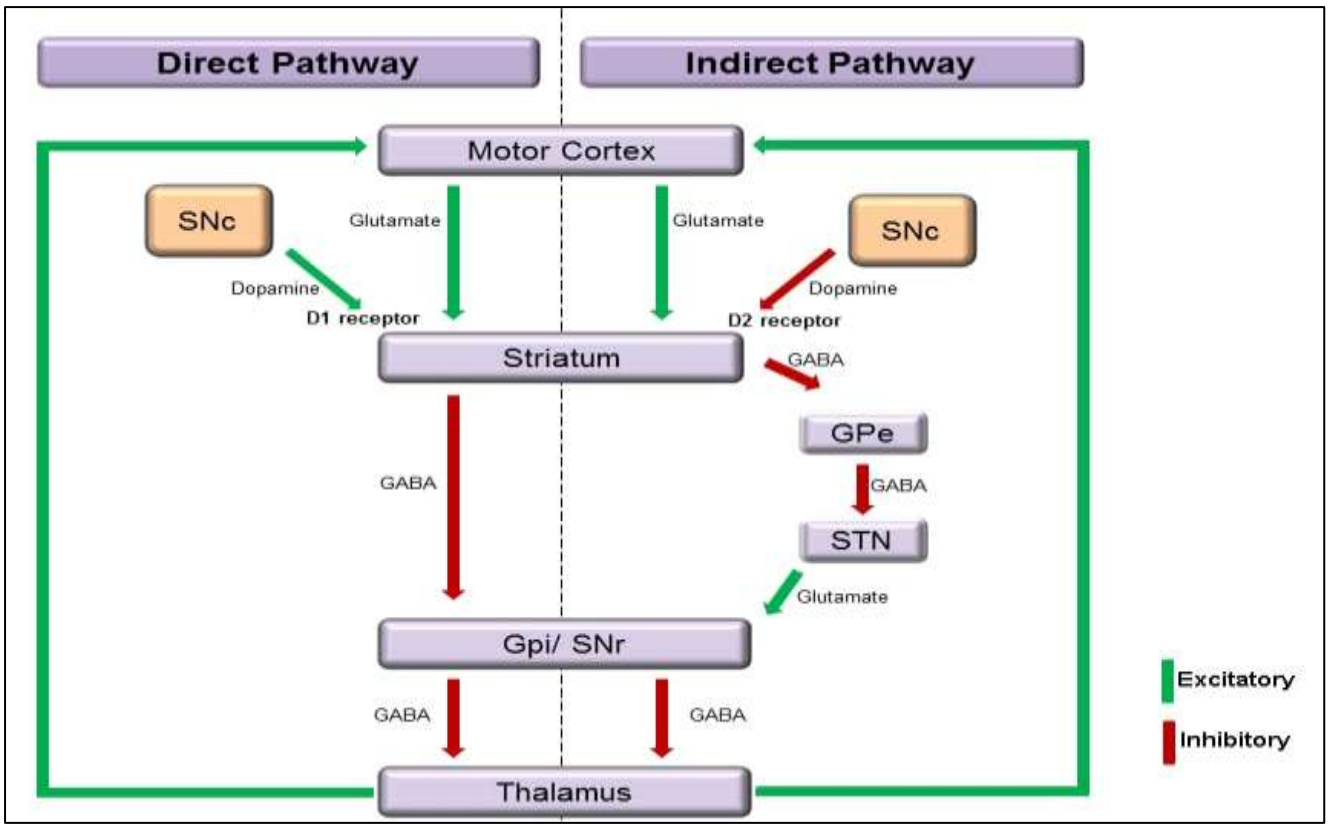
Direct Pathway
Indirect Pathway
Motor Cortex
SNc
Glutamate
Glutamate
SNc
Dopamine
D1 receptor
Dopamine
D2 receptor
Striatum
GABA
GPe
GABA
GABA
STN
Glutamate
Gpi/ SNr
GABA
GABA
Thalamus
Excitatory
Inhibitory

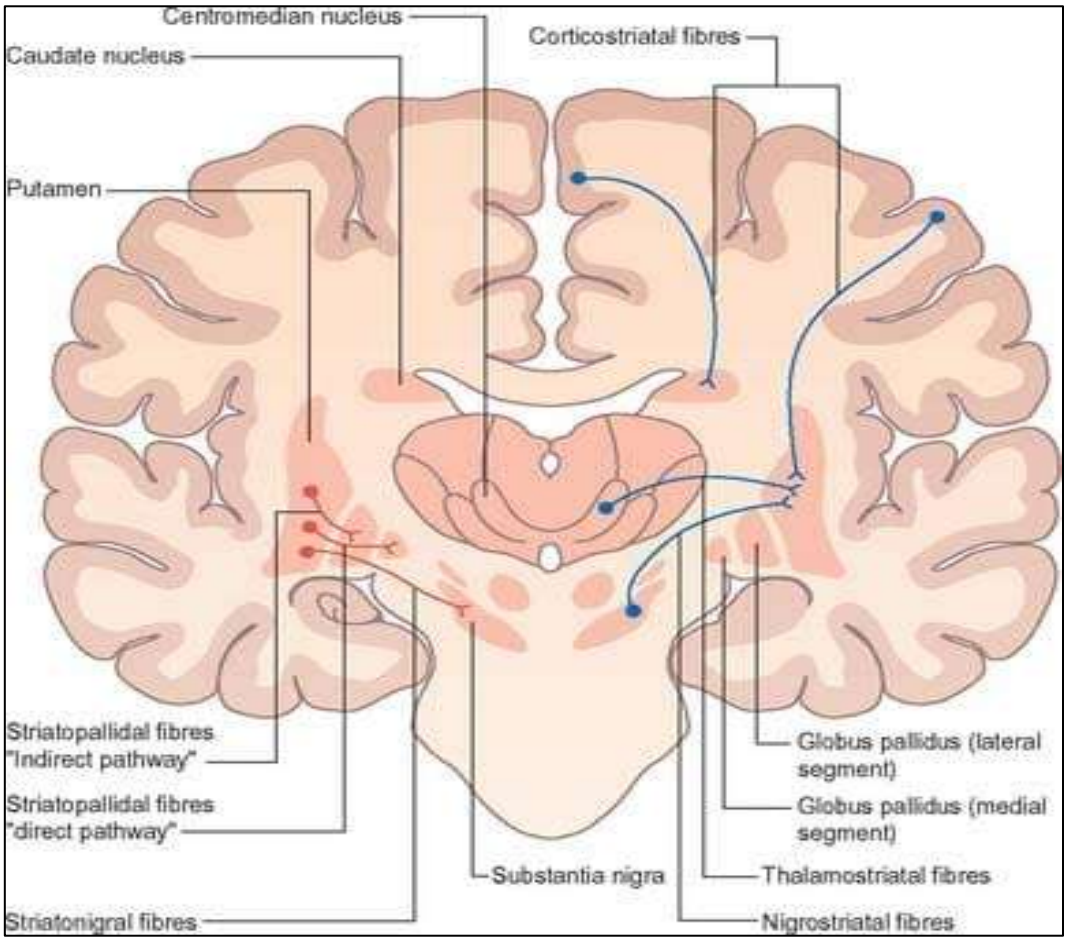
Centromedian nucleus
Caudate nucleus
Corticostriatal fibres
Putamen
Striatopallidal fibres "Indirect pathway"
Striatopallidal fibres "direct pathway"
Striatonigral fibres
Substantia nigra
Globus pallidus (lateral segment)
Globus pallidus (medial segment)
Thalamostriatal fibres
Nigrostriatal fibres

(5)

(A) **T**

(B) **F** - Extends to the S2 vertebral level.

(C) **F** - Project into the dural venous sinuses.

(D) **T**

(E) **T**

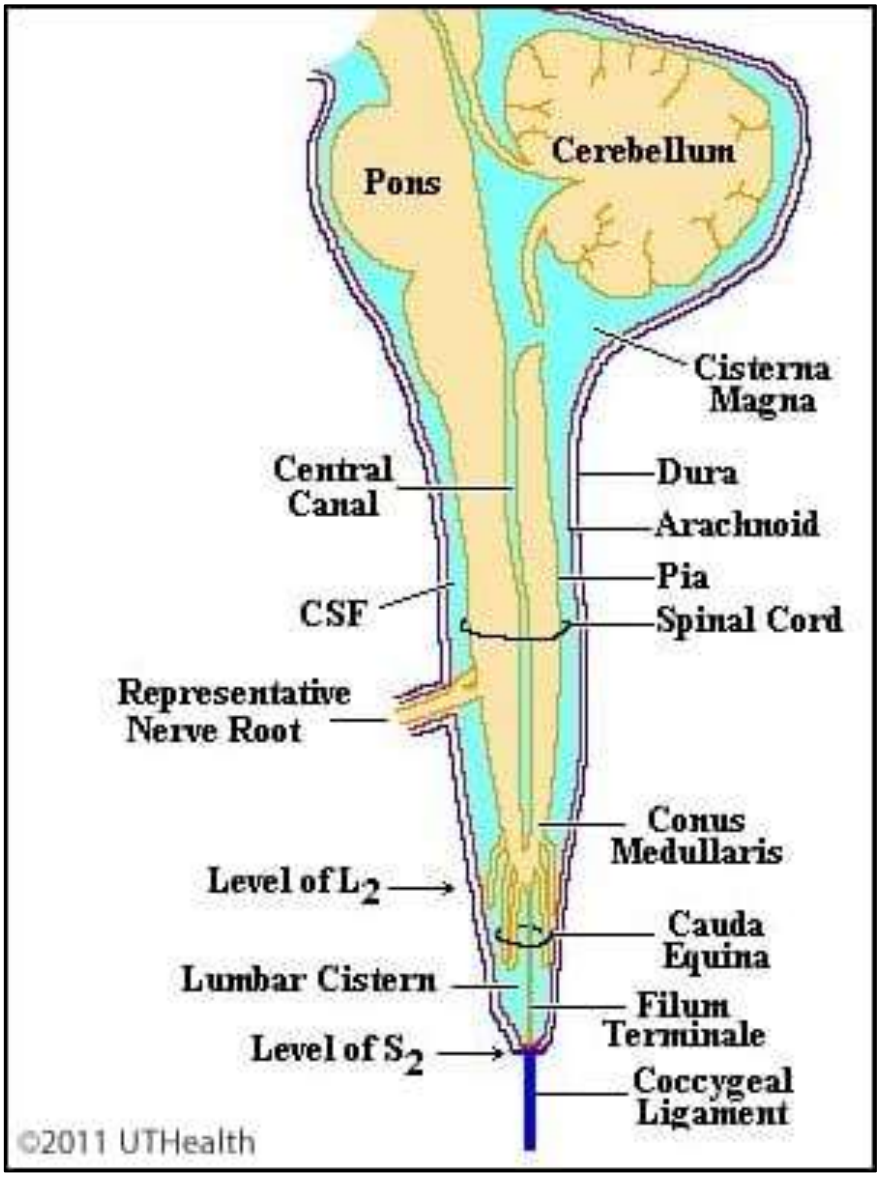

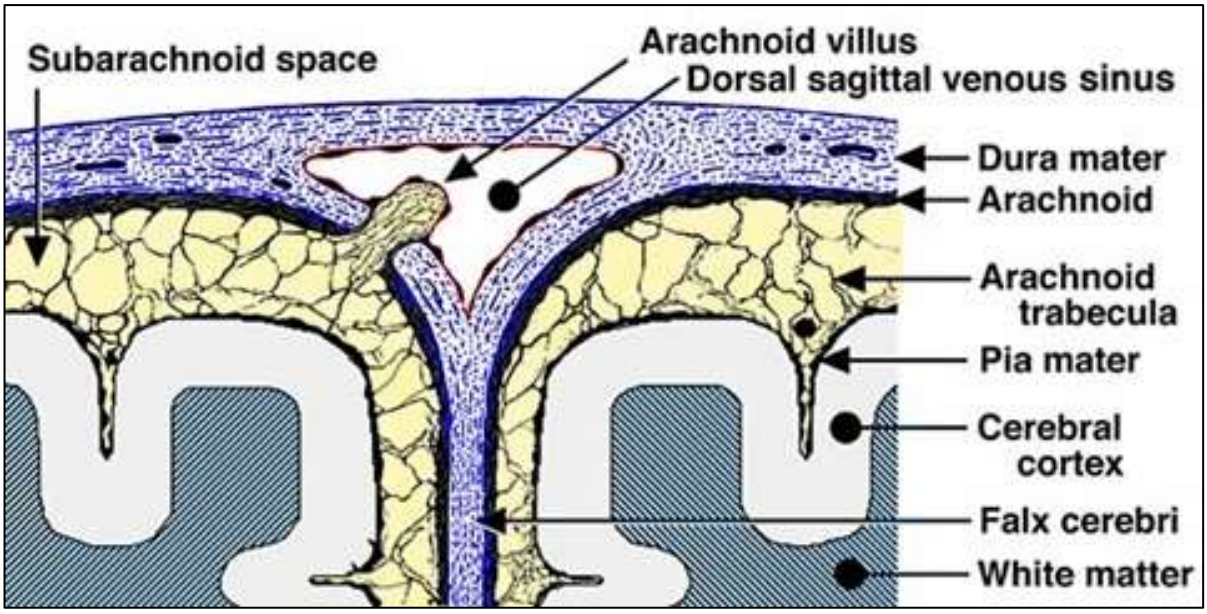

(6)

(A) **T**
(B) **T**
(C) **F** - Mainly connects the two anterior cerebral arteries.
(D) **T**
(E) **T**

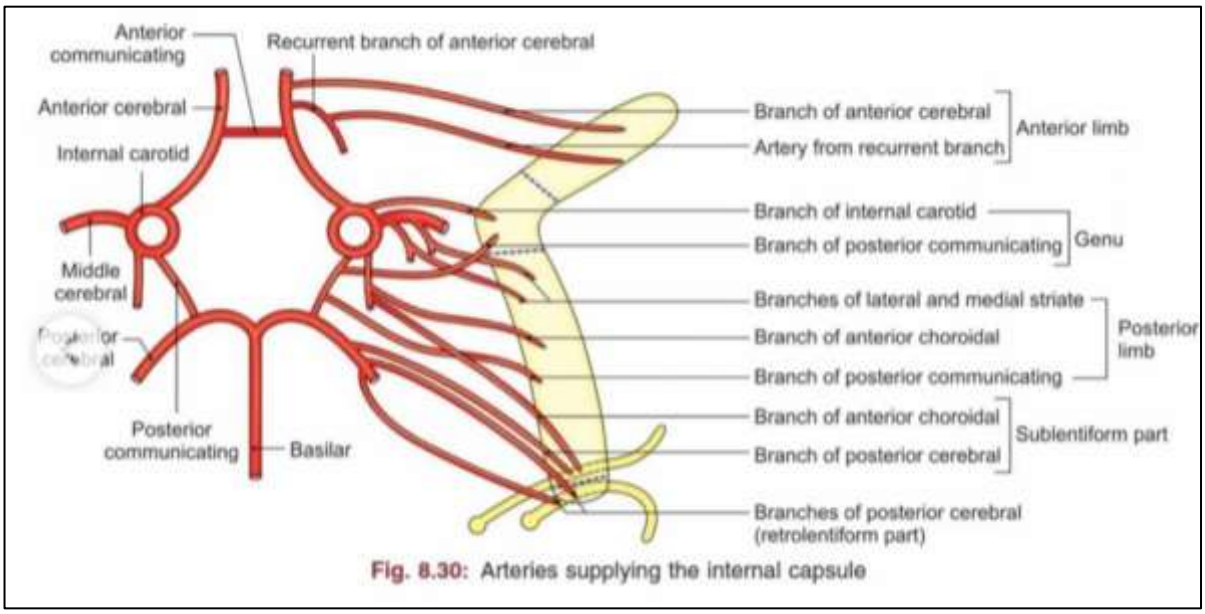

Fig. 8.30: Arteries supplying the internal capsule

(7)

(A) **F** - Thalamus is part of the diencephalon, not the brainstem.
(B) **T** - It consists of multiple nuclei groups (anterior, medial, lateral, etc.).
(C) **F** - Not the main emotional center — that is mainly the limbic system.
(D) **T** - The internal capsule lies lateral to the thalamus.
(E) **T** - It is a major relay station for sensory pathways (except olfactory).

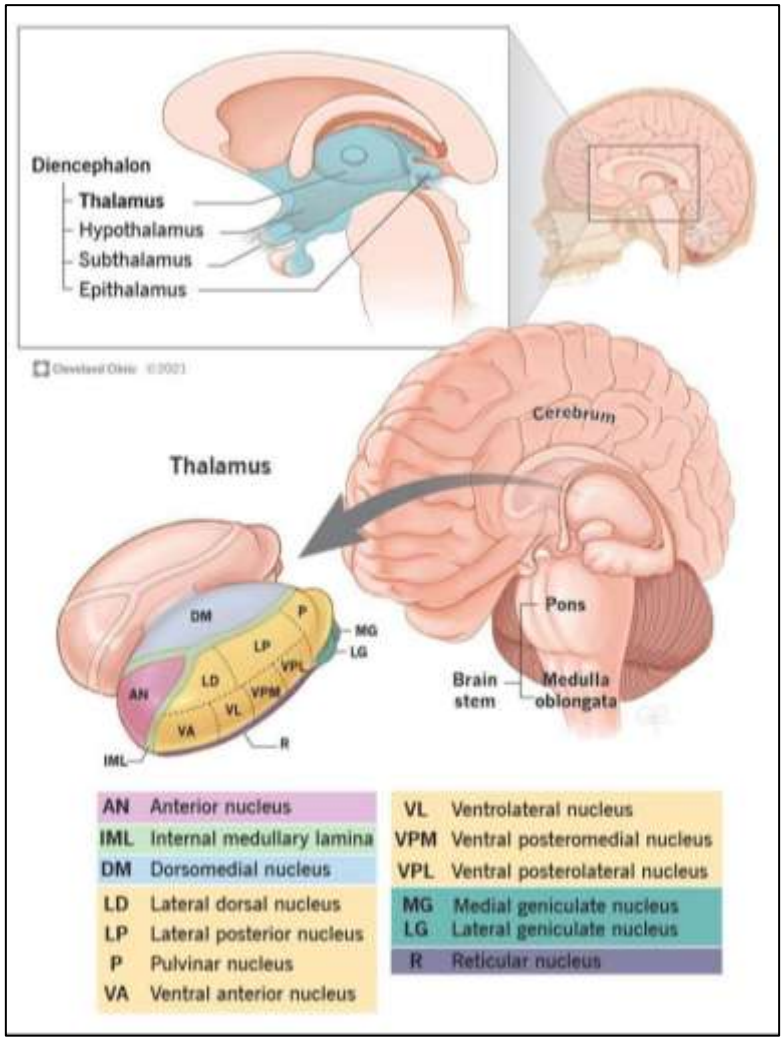

(8)

(A) **T** - The spinal root of the accessory nerve enters the skull through the foramen magnum before exiting via the jugular foramen.
(B) **T** - It exits the skull through the jugular foramen along with the vagus nerve.
(C) **F** - It does not pierce sternocleidomastoid; it supplies it and then crosses the posterior triangle to trapezius.
(D) **T** - It is a pure motor nerve (supplies sternocleidomastoid and trapezius).
(E) **F** - It is not commonly injured in thyroidectomy (more at risk in posterior triangle surgeries, e.g. lymph node biopsy.

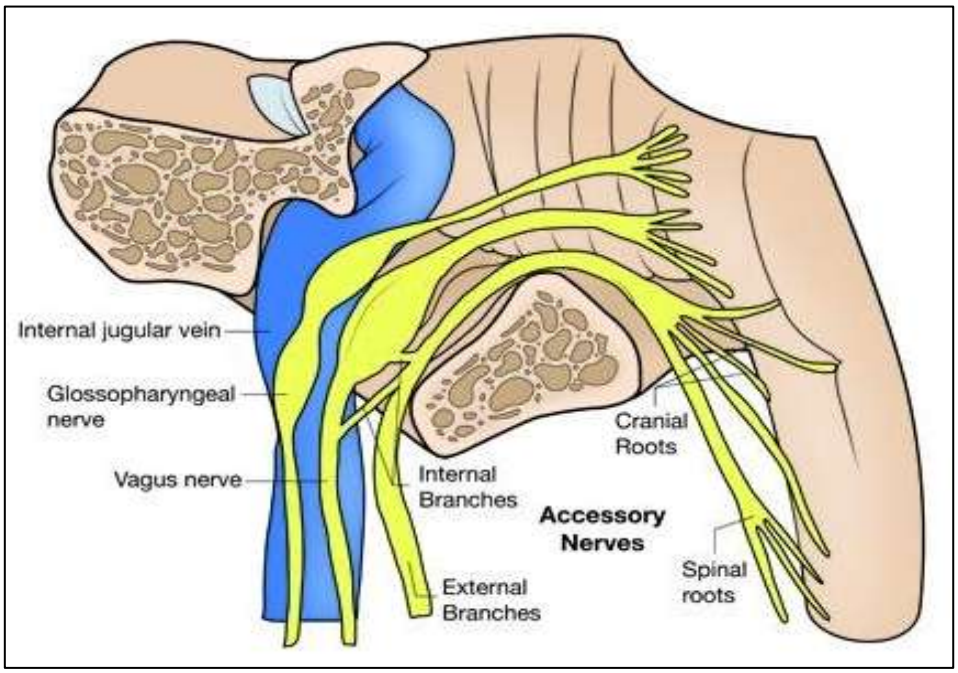

(9) **C**

The pterion is the weak junction of frontal, parietal, temporal, and sphenoid bones. Deep to it runs the anterior branch of the Middle meningeal artery. A blow here commonly tears this artery causing arterial extradural haemorrhage.

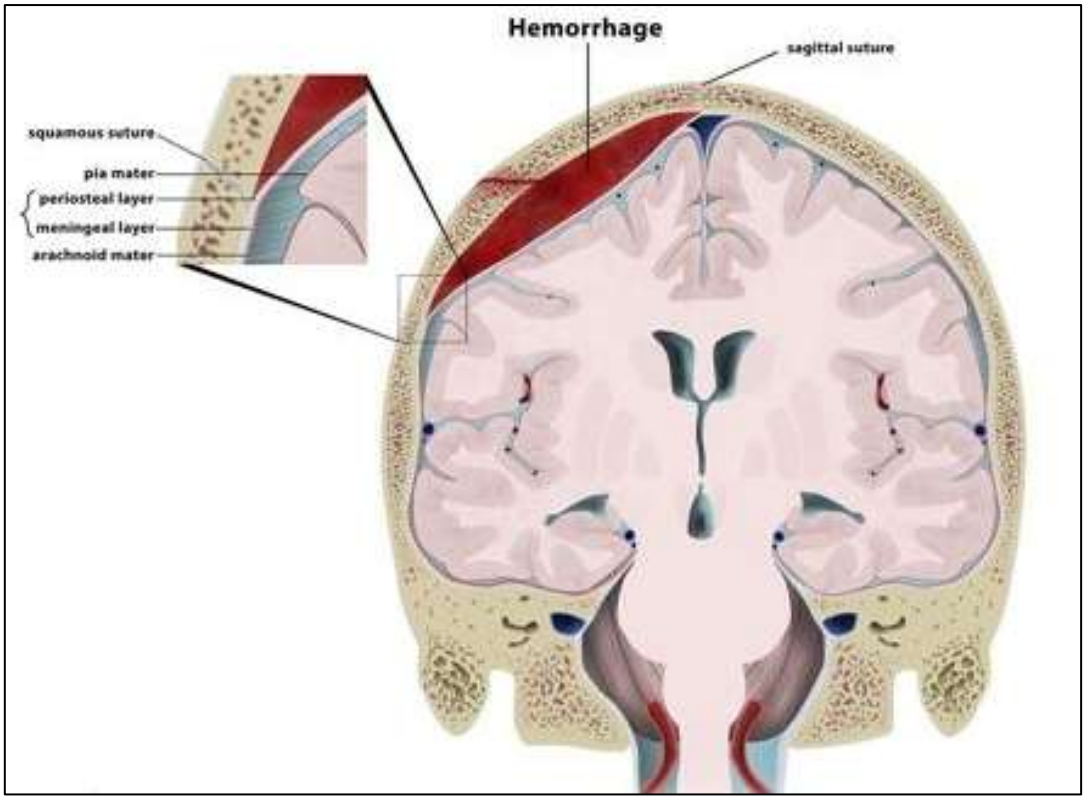

(10) **B**

Facial nerve paralysis with hearing loss suggests a lesion where both CN VII and CN VIII are affected together. These two nerves pass through the internal auditory meatus, so a lesion here can damage both. Therefore, the most likely site of injury is the internal auditory meatus.

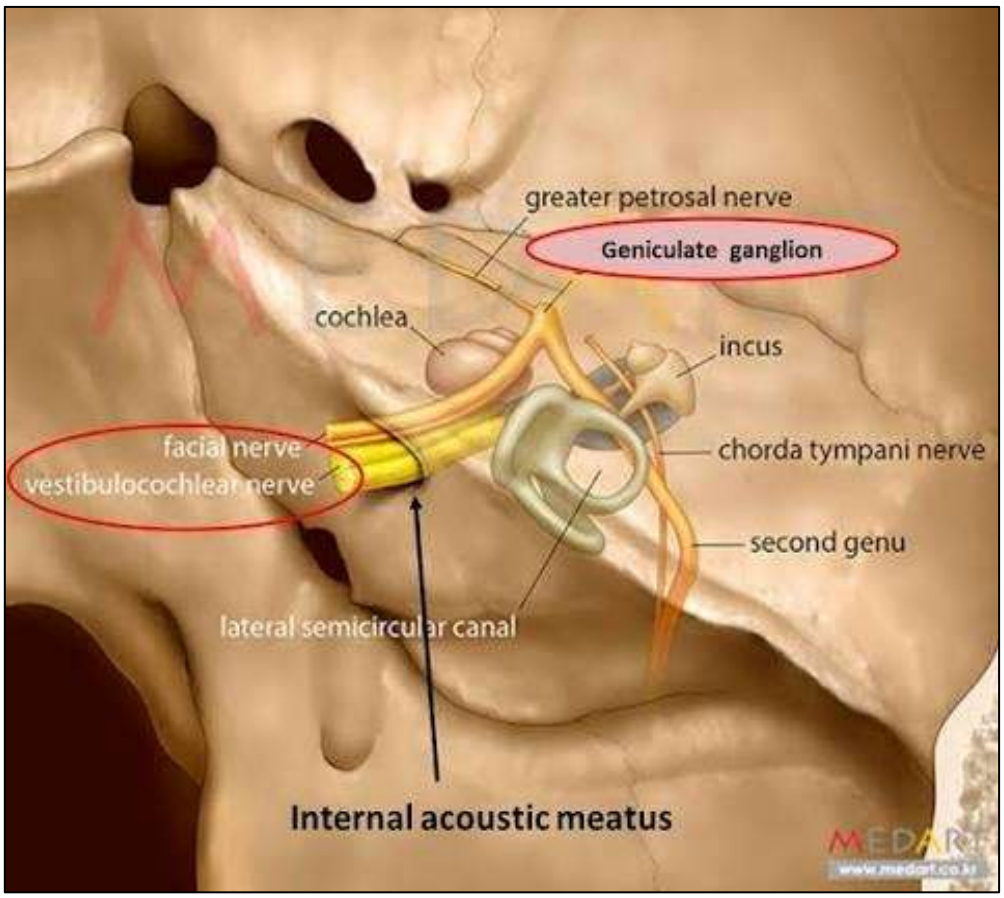

Lower Limb Practice MCQs Answers

(1)

(A) **F**
(B) **F**
(C) **F**
(D) **F**
(E) **T**

Coccyx can be felt at the lower end of the vertebral column in the midline (especially in thin individuals).

Ischial spine is not externally palpable. It can only be felt per vaginally or per rectally, not on surface examination.

Anterior superior iliac spine (ASIS) is generally not palpable. Unlike the ASIS, which is easily felt, Anterior inferior iliac spine lies deeper.

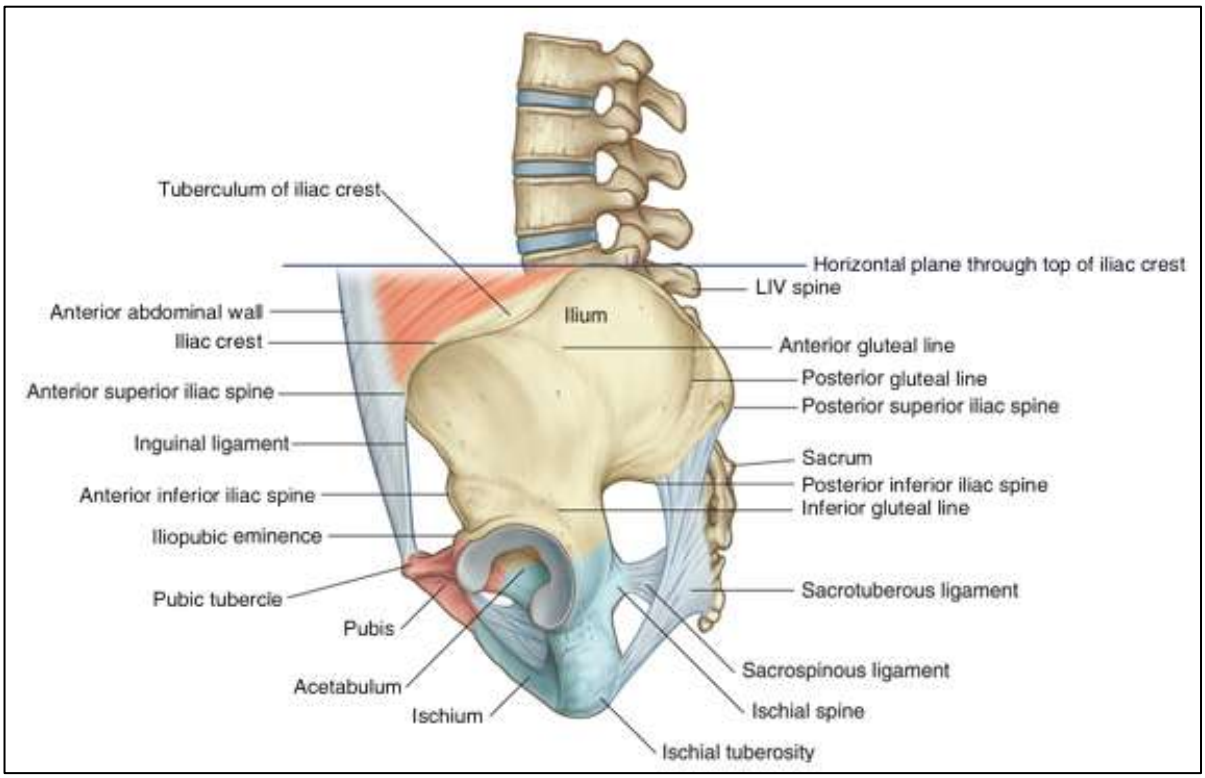

(2)

(A) **T** - Femur is the largest bone of the body.
(B) **T** - Damage to the neck of femur can cause avascular necrosis (due to disruption of retinacular branches of medial circumflex femoral artery).
(C) **T** - Fracture of the distal end of the femur tears the popliteal artery.
(D) **T** - Popliteal pulse is difficult to feel in the popliteal fossa. (deeply placed & requires knee flexion)
(E) **F** - Femoral artery lies over the femoral head region indirectly, separated by structures; clinically compressed against superior pubic ramus, not directly on head.

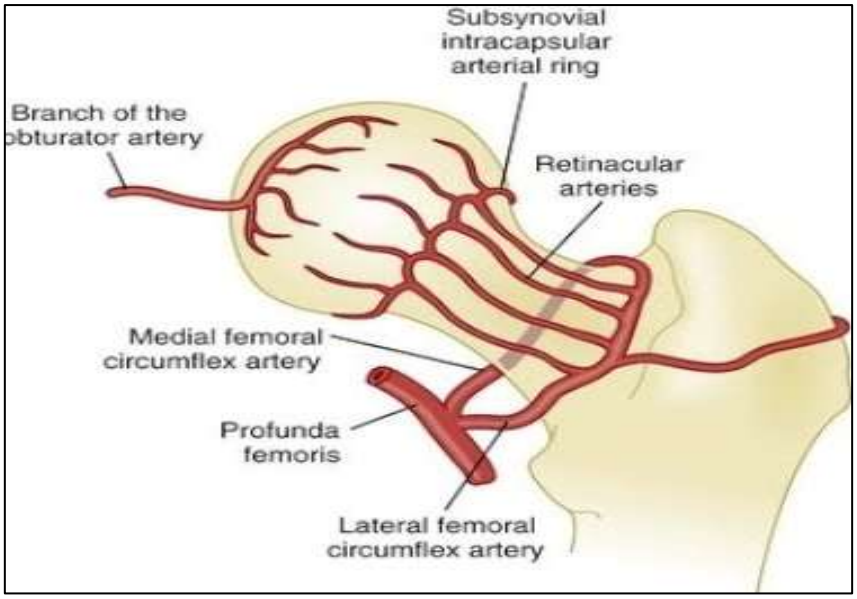

(3)

(A) **T** - Floor is mainly adductor longus & magnus.
(B) **T** - Roof is sartorius.
(C) **F** - Femoral vein is medial to artery.
(D) **F** - Iliotibial tract exists laterally.
(E) **F** - Gracilis is supplied by obturator nerve.

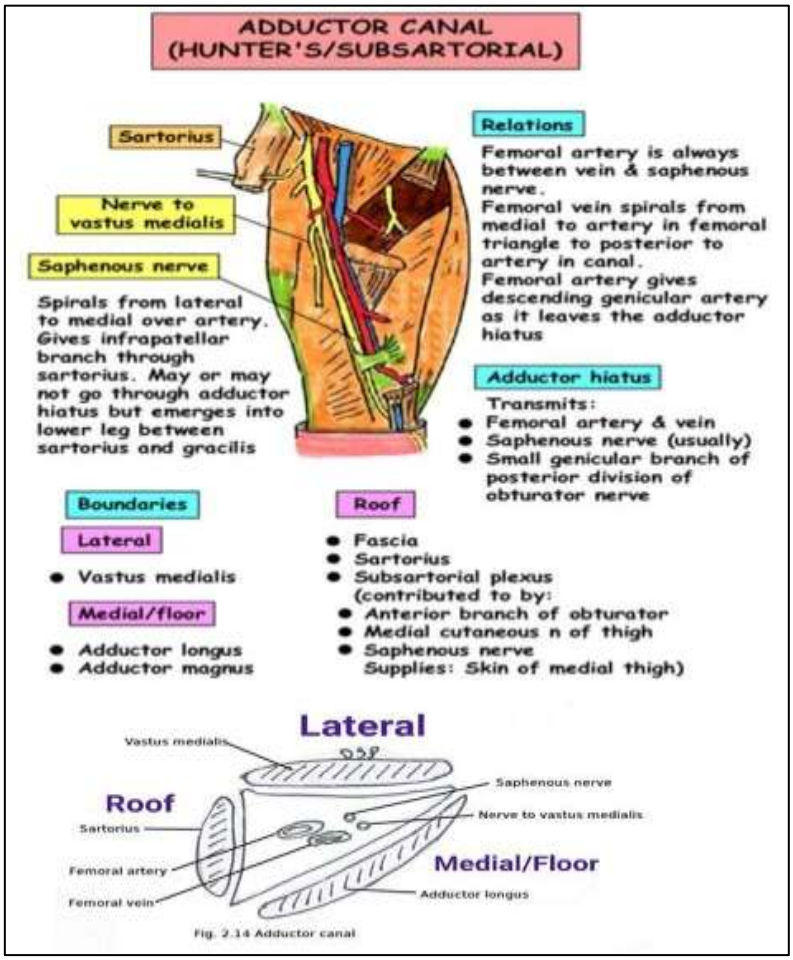

(4)

(A) **T** - Pierced by perforating branches of profunda femoris.
(B) **T** - Has adductor hiatus for femoral vessels.
(C) **T** - Extends hip (hamstring part).
(D) **F** - Sciatic nerve lies posterior to it.
(E) **F**

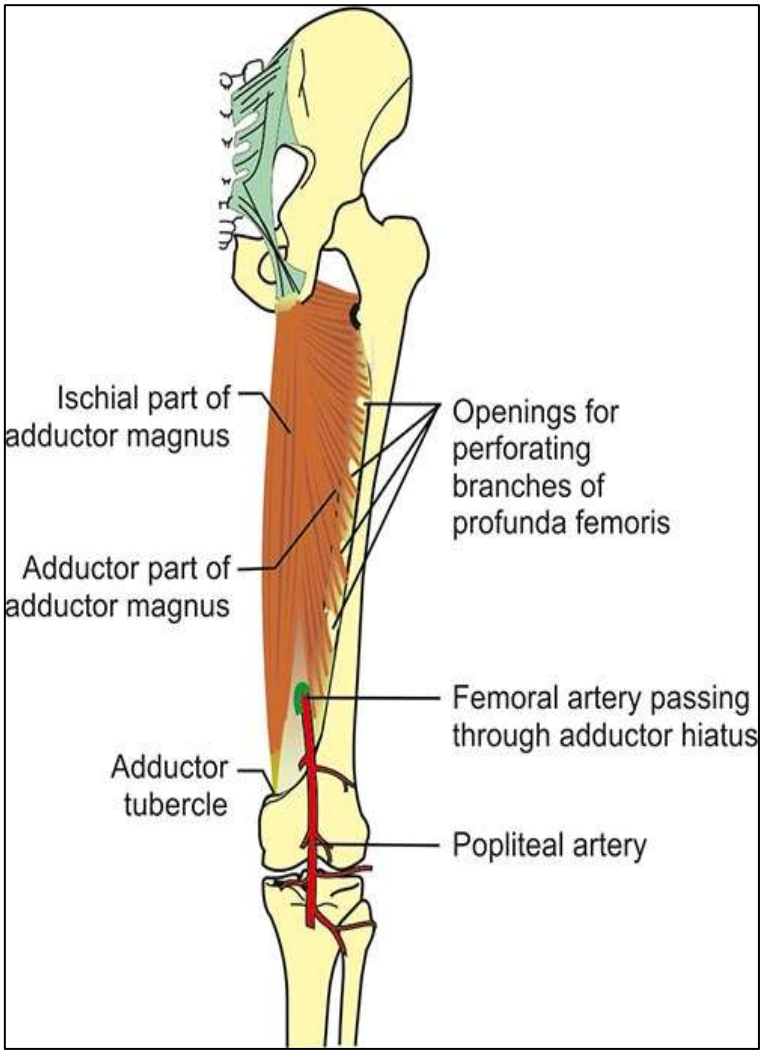

(5)

(A) **F**
(B) **T**
(C) **F**
(D) **T**
(E) **T**

Rectus femoris muscles,

- Semitendinosus
- Semimembranosus
- Biceps femoris

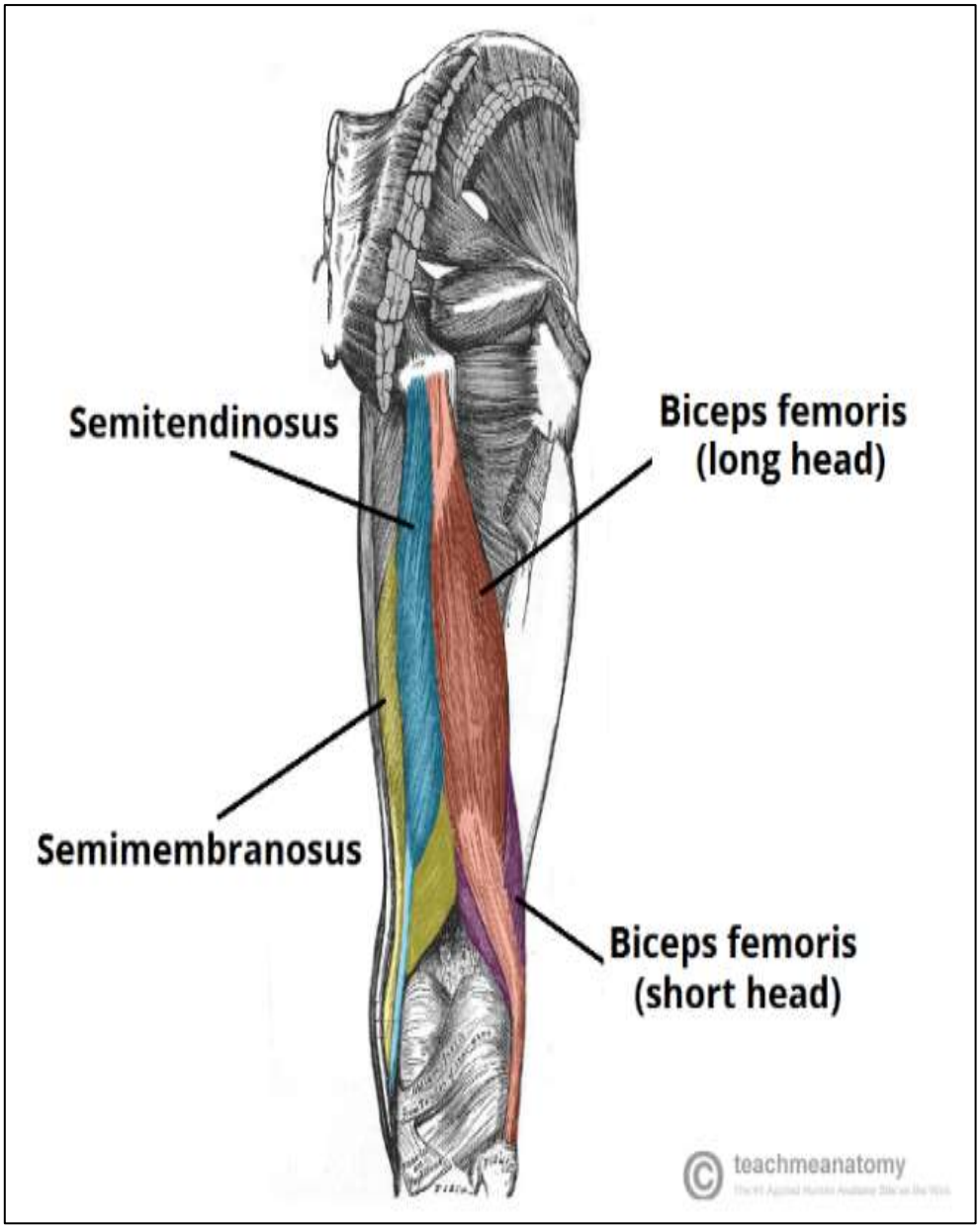

(6)

(A) **T**
(B) **T**
(C) **F**
(D) **F**
(E) **T**

The posterior tibial artery lies posterior to the medial malleolus.
Dorsalis pedis may be congenitally absent → not always pathological.

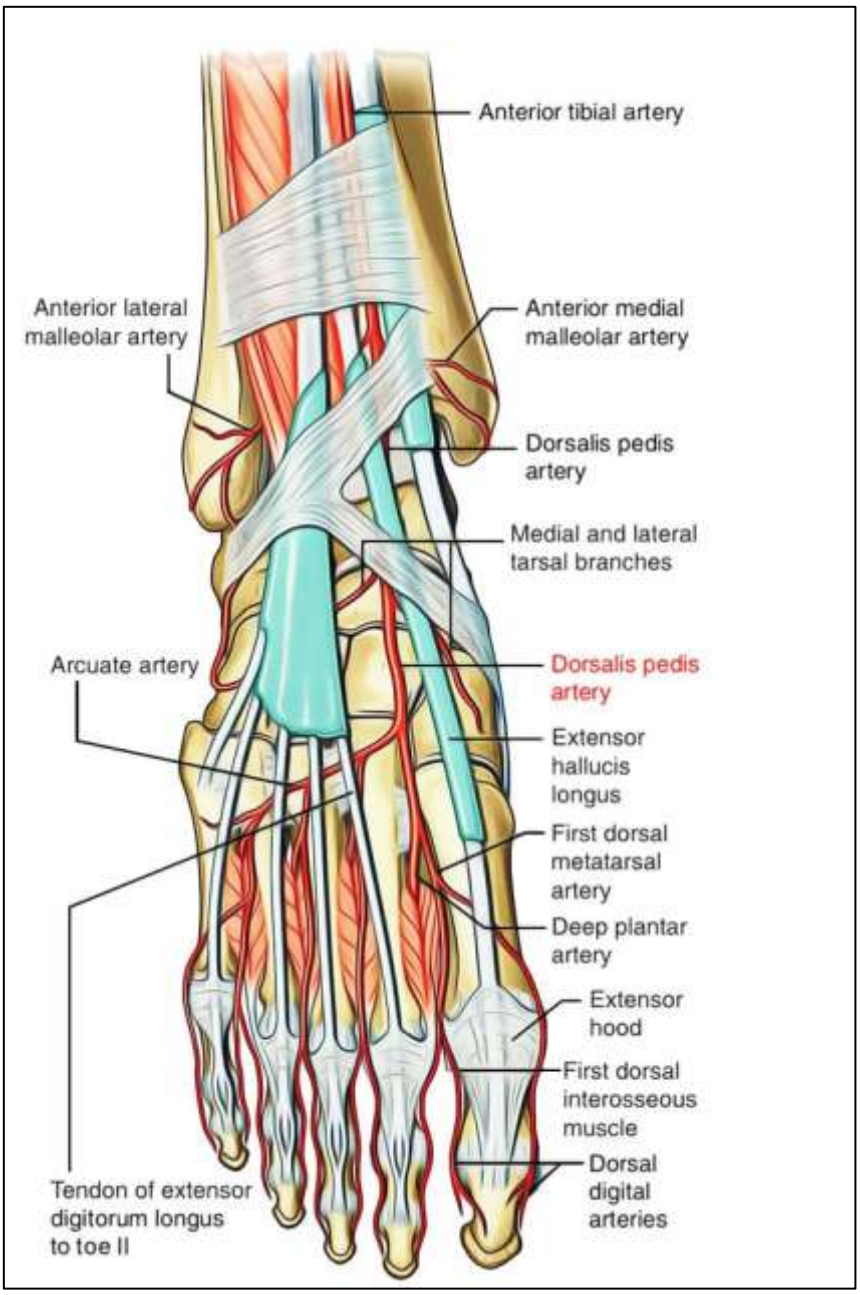

(7)

(A) **T**
(B) **T**
(C) **T**
(D) **F**
(E) **T**

Medial arch stability = spring ligament (passive) + tibialis posterior (dynamic) + plantar aponeurosis (tie beam).
Long plantar ligament mainly supports lateral arch.

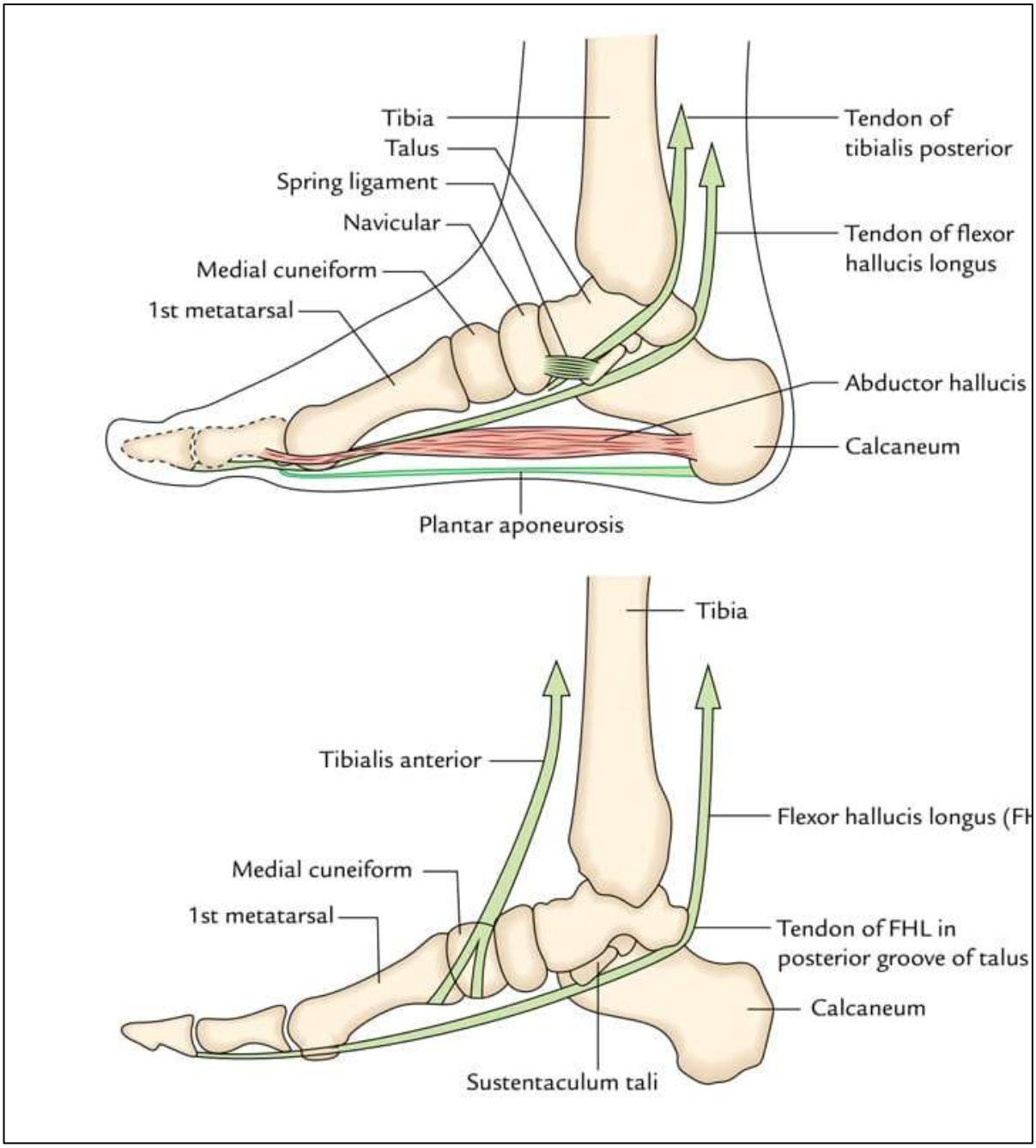

(8)

(A) **T**
(B) **T**
(C) **T**
(D) **F**- Higher than lateral arch, not flatter.
(E) **T**

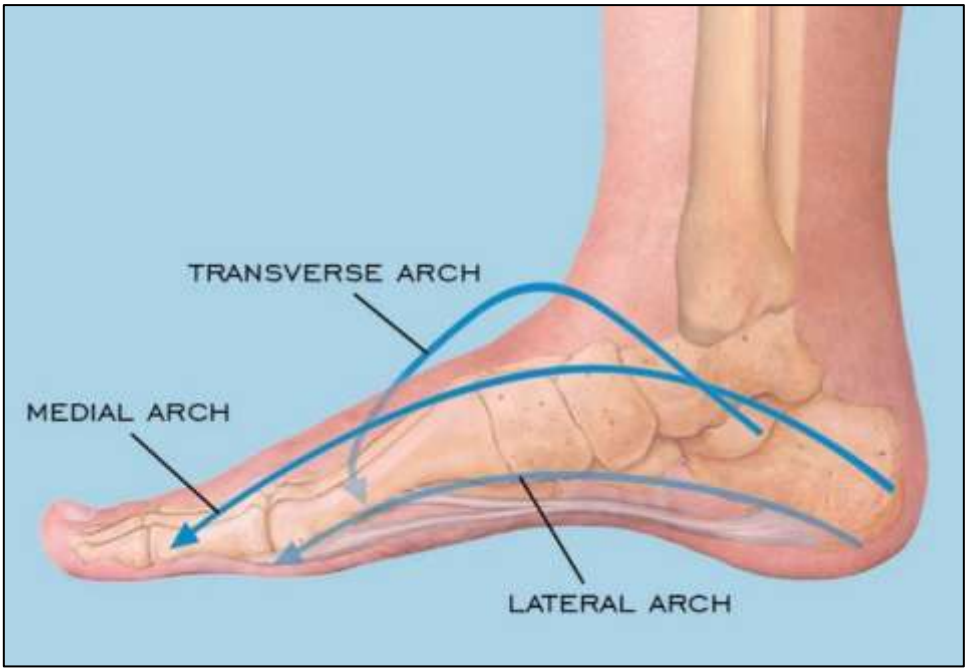

(9)

(A) **T**
(B) **T**
(C) **T**
(D) **T**- Lower than medial arch, not higher.
(E) **F**

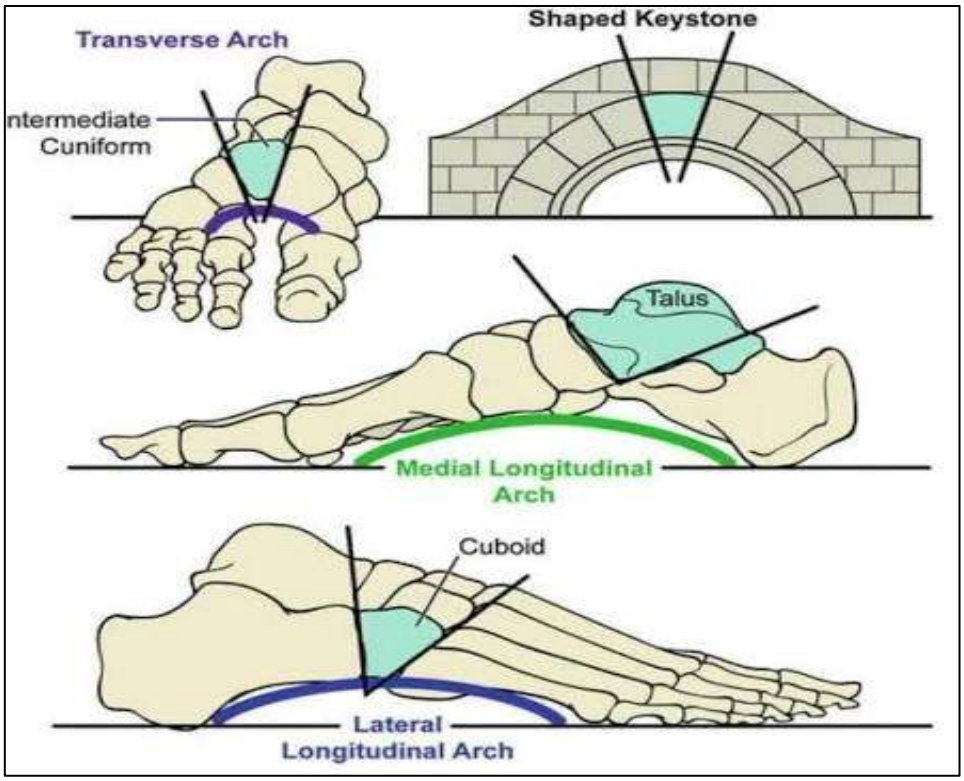

(10) **D**

Improper injection in the gluteal region can injure the sciatic nerve, leading to hamstring weakness (knee flexion) and foot drop due to involvement of its branches (tibial and common peroneal nerves).

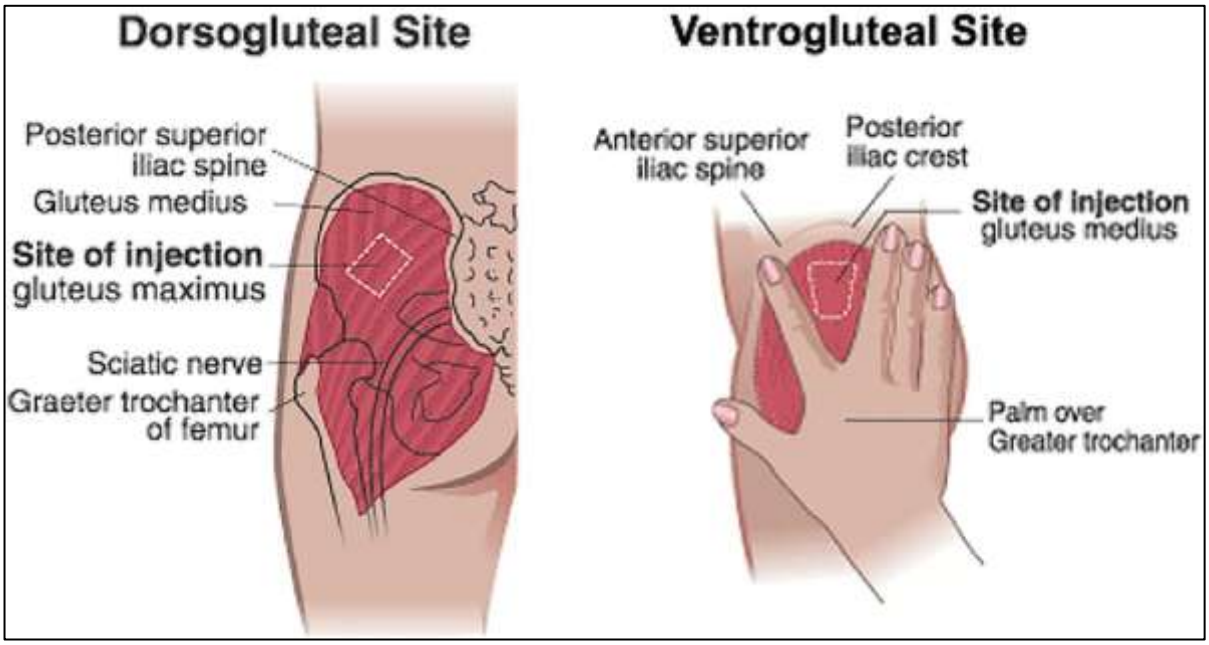

(11) **D**

The head of the femur is mainly supplied by retinacular arteries (branches of the medial circumflex femoral artery) that run along the neck of the femur.

- A subcapital fracture occurs just below the head and disrupts these vessels most severely, cutting off blood supply, leading to avascular necrosis (AVN).
- Other fractures (like intertrochanteric or subtrochanteric) are extracapsular and usually preserve the blood supply, so AVN is less common.

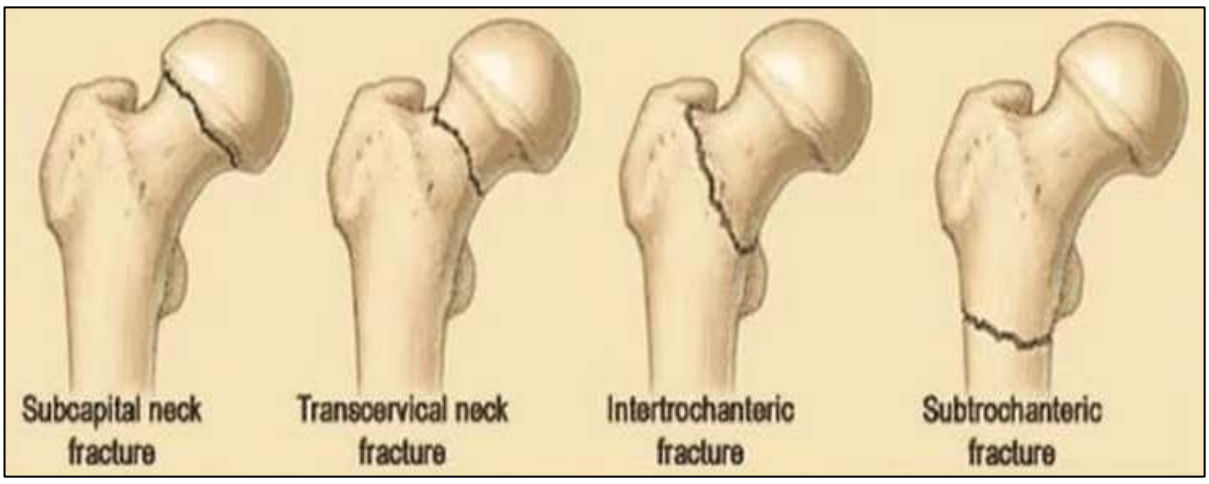

(12) **B**

Pain in the knee with a normal joint strongly suggests referred pain.
The obturator nerve (L2–L4) supplies the medial thigh and also contributes to the hip joint, and its articular branch can refer pain to the knee.
A pelvic inflammatory mass in the iliac fossa can compress the obturator nerve as it runs along the lateral pelvic wall.

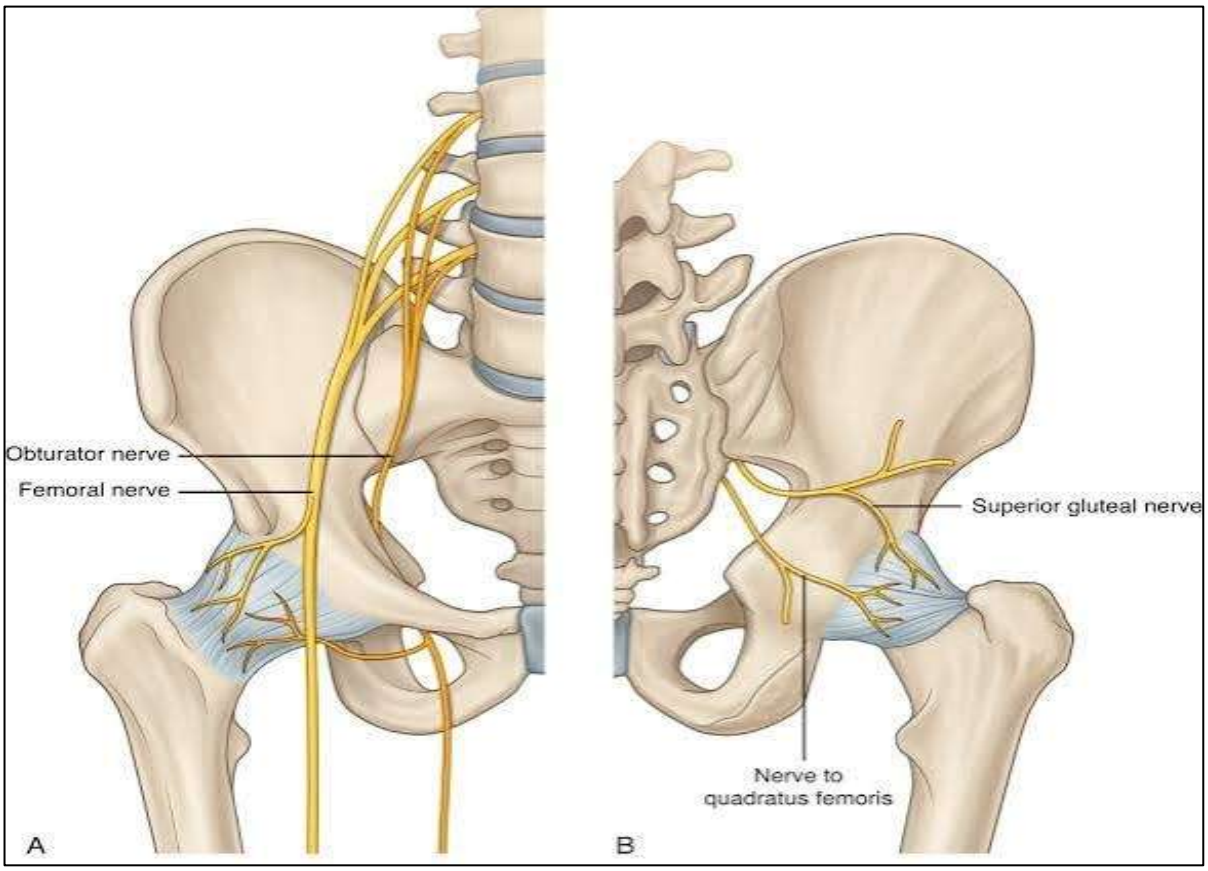

(13) **B**

L3 spinal segment injury affects movements mainly supplied by L2–L4.
Ankle plantarflexion is not affected. Supplied mainly S1–S2 (tibial nerve)

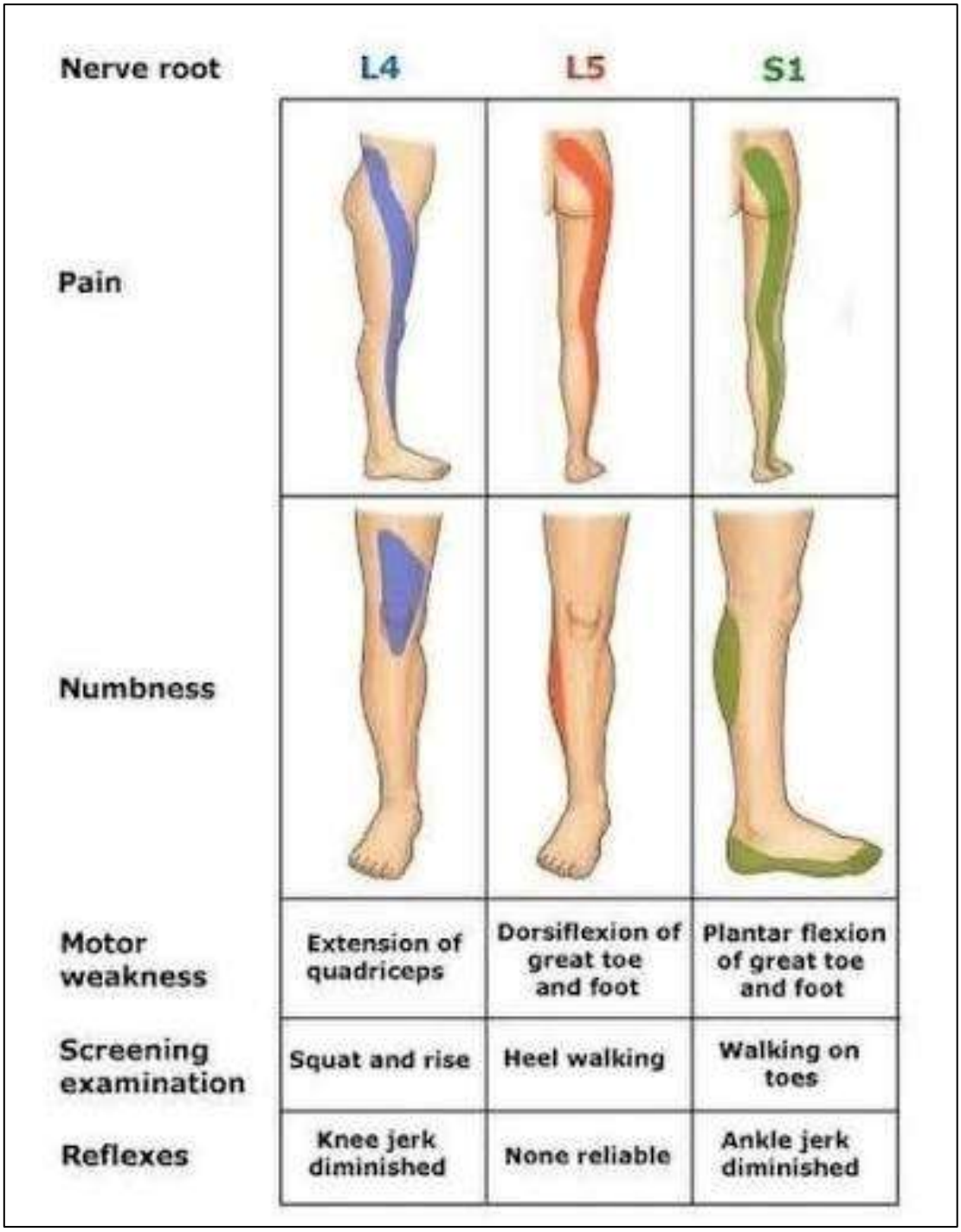

(14) **D**

A retrocecal appendix lies close to the psoas muscle.
Inflammation irritates psoas causes psoas spasm.
So, the patient keeps hip flexed to reduce pain. Pain increases on hip extension, known as the classic psoas sign.

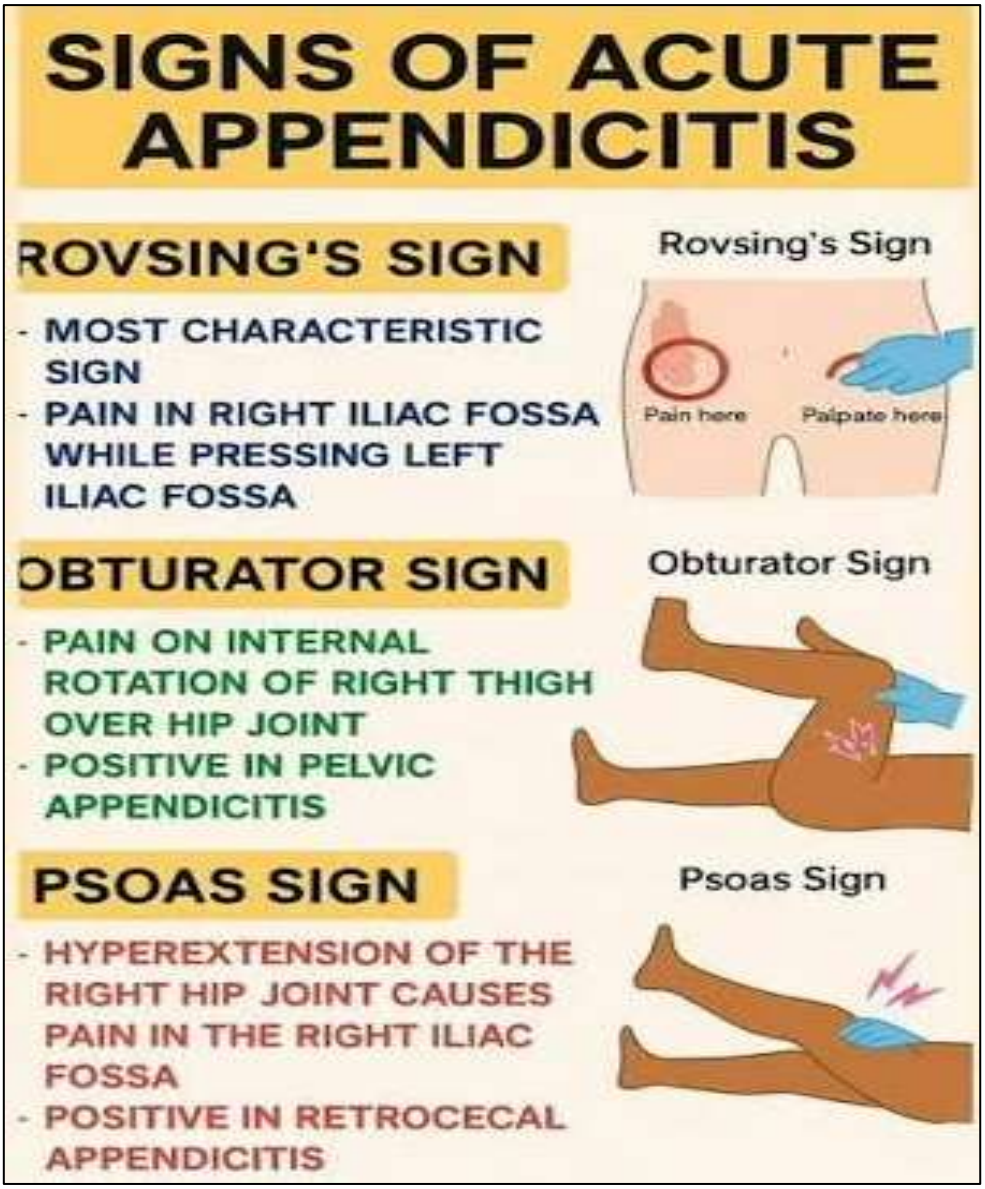

(15) **B**

The medial meniscus is more commonly injured because it is firmly attached to the tibial collateral ligament, making it less mobile and more prone to injury during rotational forces.

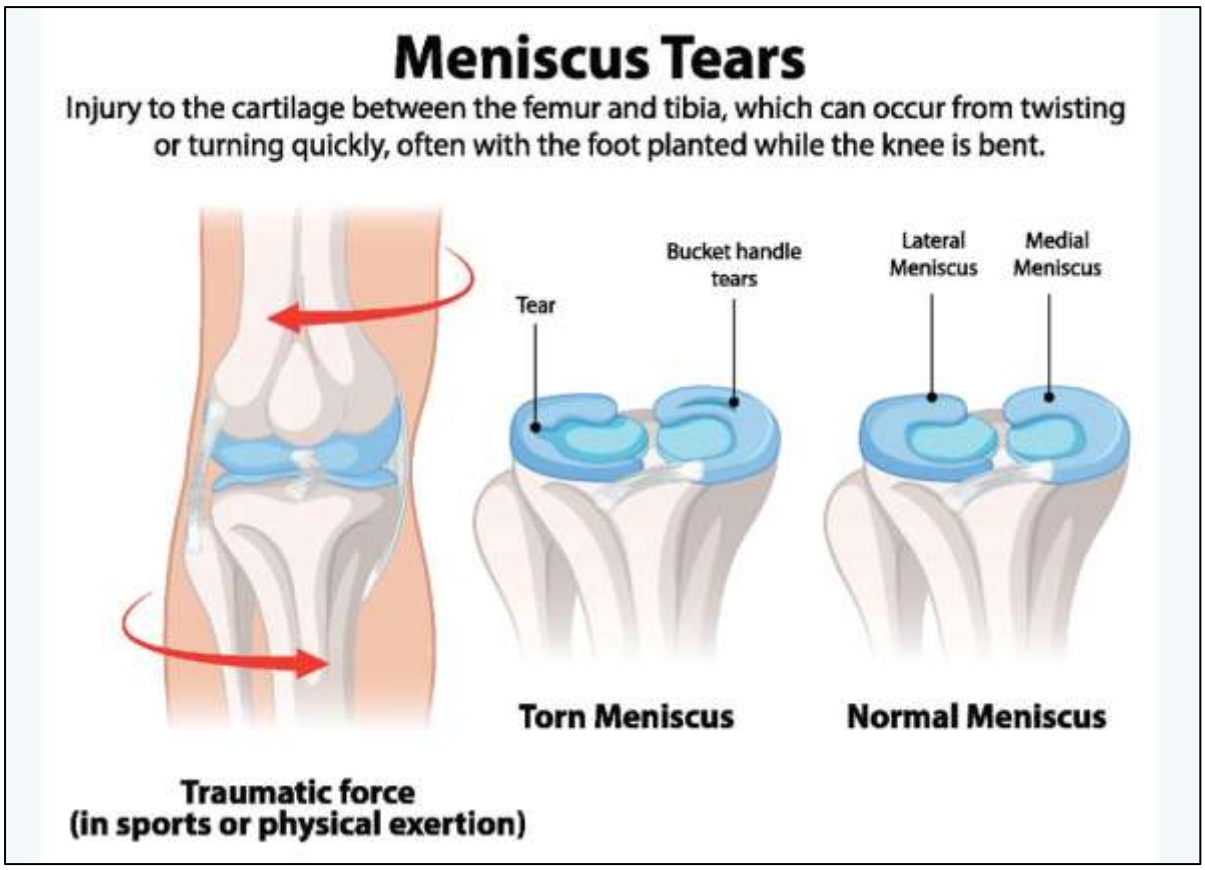

(16) **C**

The main neurovascular structures in the popliteal fossa are arranged from superficial to deep as:

Nerve → Vein → Artery (NVA)

Thus, the tibial nerve is the most superficial major structure and most at risk during posterior knee procedures.

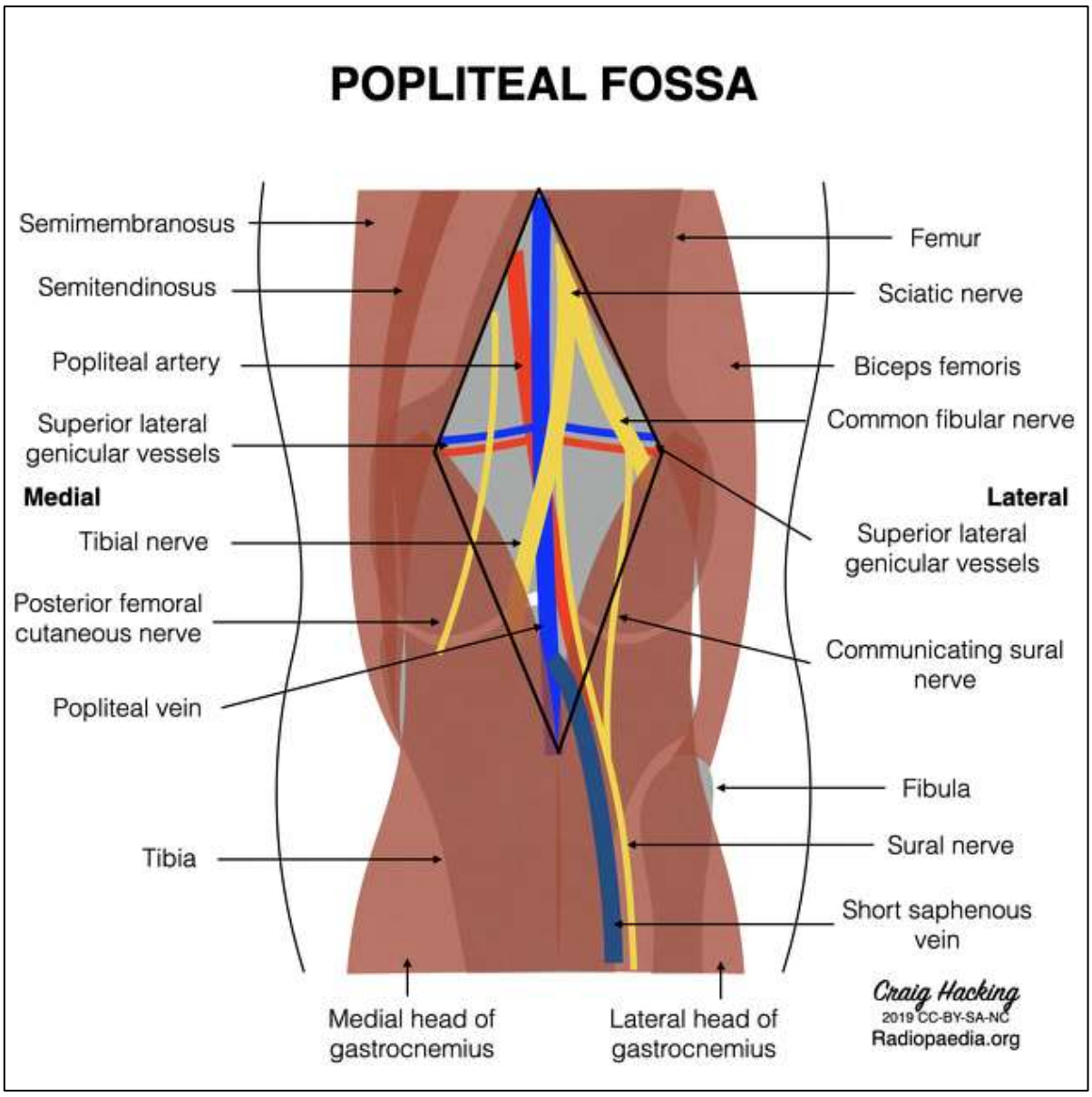

(17) **B**

Achilles tendon rupture → loss of plantarflexion + positive Thompson test.
Gastrocnemius and soleus insert via this tendon into calcaneus.
Plantaris is vestigial and weak.



(18) **C**

Tarsal tunnel syndrome = compression of tibial nerve under flexor retinaculum.
Symptoms affect plantar aspect.
Mnemonic: Tom, Dick And Very Nervous Harry.

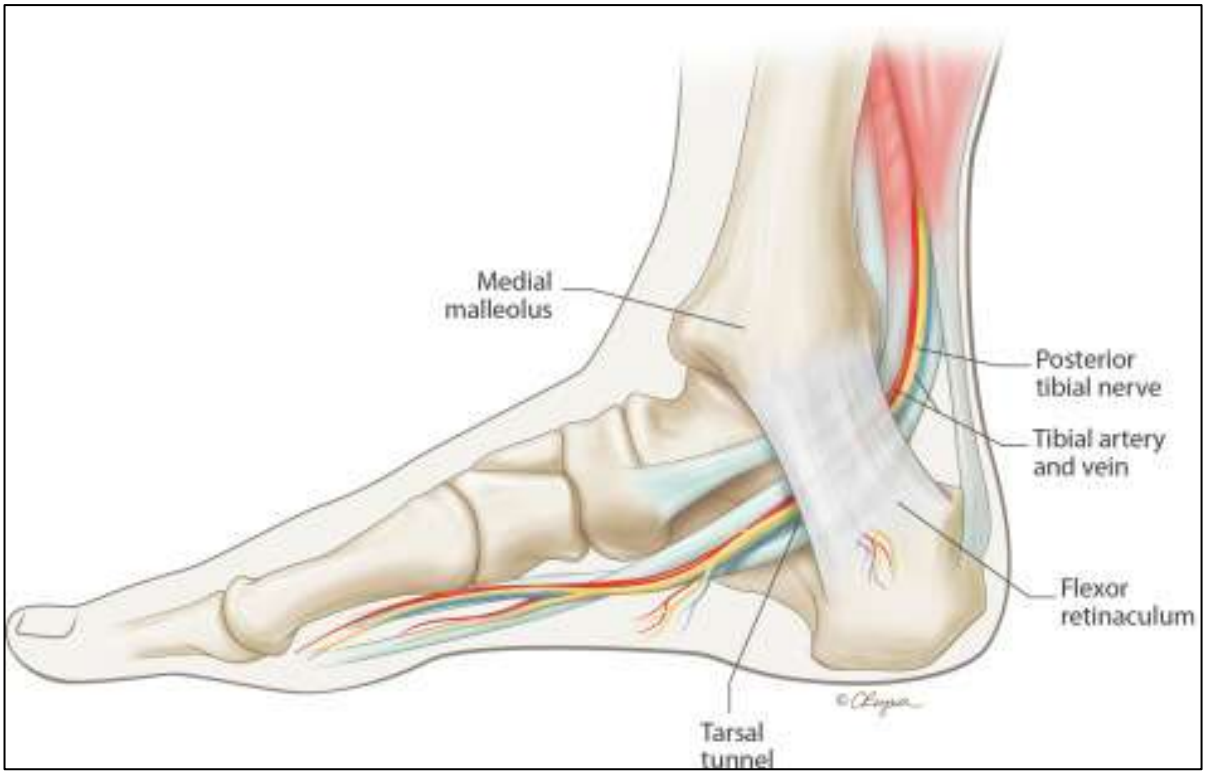

(19) **D**

Common peroneal nerve winds around fibular neck → vulnerable.
Injury → foot drop (loss of dorsiflexion) + sensory loss over dorsum.

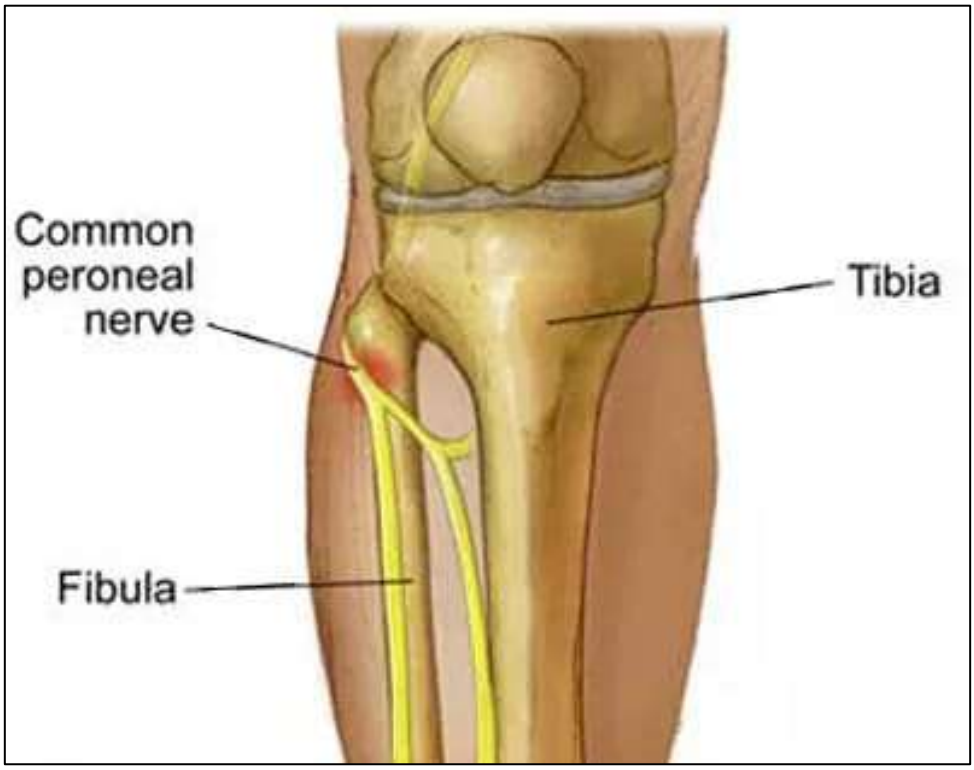

BATCH 02 – SEMESTER 03 SMALL GROUP DISCUSSIONS (SGDs) WITH ANSWERS

SGD 01 – Skull, Cervical spine & Anatomy of Neck Movements MCQs

(1) True or False regarding cervical vertebra?

(A) It is characterized by having foramen transversarium.
(B) They all have bifid spines.
(C) Third cervical is atypical.
(D) Seventh vertebral foramen traverse the vertebral vein.
(E) Head rotation occurs between the first and second vertebra.

(2) True or False regarding movements of the neck?

(A) Flexion and extension of the head occur mainly at the atlanto-occipital joint.
(B) Rotation of the head takes place primarily at the atlanto-axial joint.
(C) Lateral flexion of the neck is produced by unilateral contraction of sternocleidomastoid.
(D) Bilateral contraction of sternocleidomastoid produces extension of the head.
(E) Intervertebral joints between cervical vertebrae contribute to all movements of the neck.

(3) True or False regarding scalp?

(A) Most superficial layer is thin skin.
(B) Occipitofrontalis is attached to aponeurosis.
(C) Bleeding under the aponeurosis can give lead to black eye.
(D) Scalp veins communicate with dura venous sinuses.
(E) Scalp wounds gape when they are parallel to aponeurotic fibers.

(4) True or False regarding the skull?

(A) The skull is divided into neurocranium and viscerocranium.
(B) The neurocranium is formed by eight bones.
(C) All bones of the skull develop by intramembranous ossification.
(D) Sutures of the skull are examples of fibrous joints.
(E) The mandible is the only movable bone of the skull.

(5) True or False regarding C8 spinal nerve?

(A) It lies between intervertebral foramina of C7 and C8.
(B) It gives somatic Motor supply to Pronator Quadratus.
(C) It gives somatic Sensory for Middle Finger.
(D) It Carries Sympathetic fibers to hand
(E) It forms middle trunk of brachial plexus.

(6) True or False regarding typical cervical vertebra?

(A) It has a smaller body having anterior posterior diameter greater than transverse diameter.
(B) Superior facet directed downwards and backwards.
(C) It has spine directed downwards and backwards.
(D) Vertebral canal is circular.
(E) It has foramen transversarium.

(7) True or False about typical cranial vertebral joint?

(A) It allows rotator movements.
(B) Articular capsule plays a major role in point stability.
(C) It is separated from neural canal by transverse ligament.
(D) It is a cartilaginous joint.
(E) Always atlas moves with the skull with the movements.

(8) Which bones form the base of the middle cranial fossa?

(A) Frontal bone
(B) Sphenoid bone
(C) Occipital bone
(D) Parietal bone
(E) Temporal bone

(9) True or False regarding the fractures of the skull?

(A) 'Pond fracture' occurs in infant's skull.
(B) Fractures of the anterior cranial fossa may lead to anosmia.
(C) Cerebrospinal rhinorrhea and epistaxis results from the fracture of the anterior cranial fossa.
(D) Fractures of the middle cranial fossa are more common than fractures in the other fossae.
(E) A black eye is not necessarily indicative of an anterior fossa fracture.

(10) A young man had a skull fracture involving the posterior cranial fossa. What is the most likely to be damaged? (SBR)

(A) Abducens nerve in the cavernous sinus.
(B) Cranial nerve VII entering the internal auditory meatus.
(C) Mandibular nerve entering the foramen ovale.
(D) Oculomotor nerve in the cavernous sinus.
(E) Nerve of the pterygoid canal.

SGD 01 – Skull, Cervical spine & Anatomy of Neck Movements MCQs Answers

(1)

(A) **T -** Cervical vertebrae are characterized by the presence of a foramen transversarium.

(B) **F -** Not all cervical vertebrae have bifid spines; C1 and C7 are non-bifid.

(C) **F -** The third cervical vertebra (C3) is a typical cervical vertebra.

(D) **T -** The foramen transversarium of C7 usually transmits the vertebral vein (the artery commonly does not pass through it).

(E) **T -** Rotation of the head occurs at the atlanto-axial joint (C1–C2).

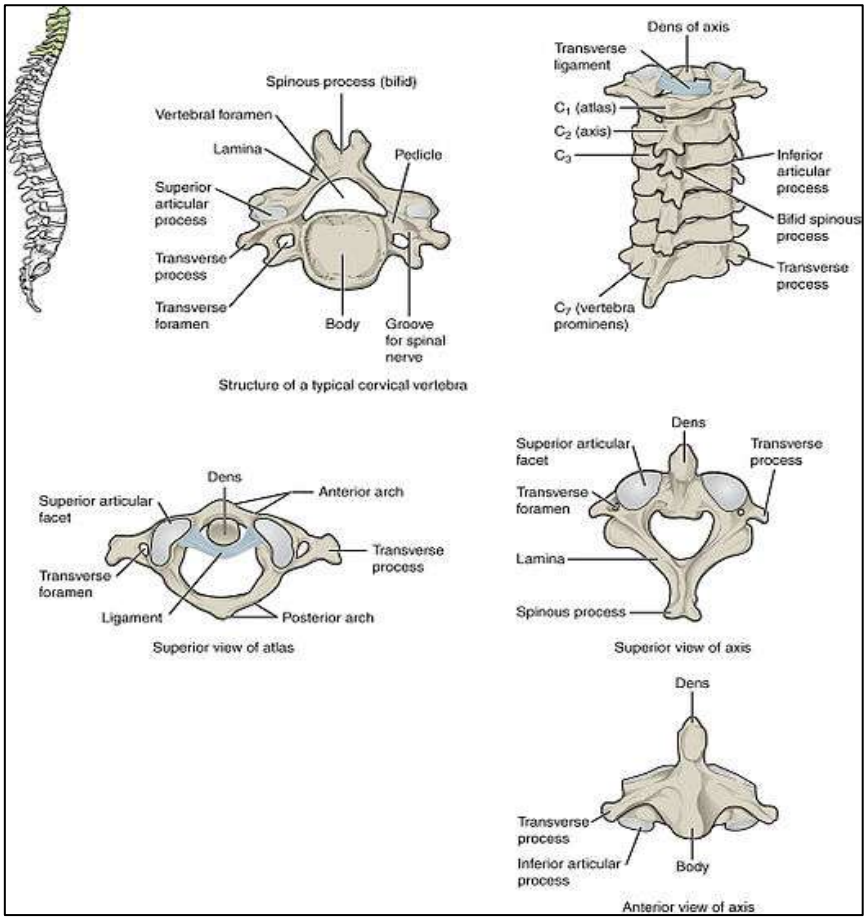

(2)

(A) **T -** The atlanto-occipital joints permit nodding movements of the head, producing flexion and extension.

(B) **T -** The atlanto-axial joint allows the atlas to rotate around the dens of the axis, accounting for the chief movement of head rotation.

(C) **T -** Unilateral contraction of sternocleidomastoid bends the neck to the same side, producing lateral flexion.

(D) **F-** Bilateral contraction of sternocleidomastoid causes flexion of the neck; extension is produced mainly by posterior neck muscles.

(E) **T -** Flexion, extension, lateral flexion, and rotation of the neck are aided by movements at the intervertebral joints of the cervical spine

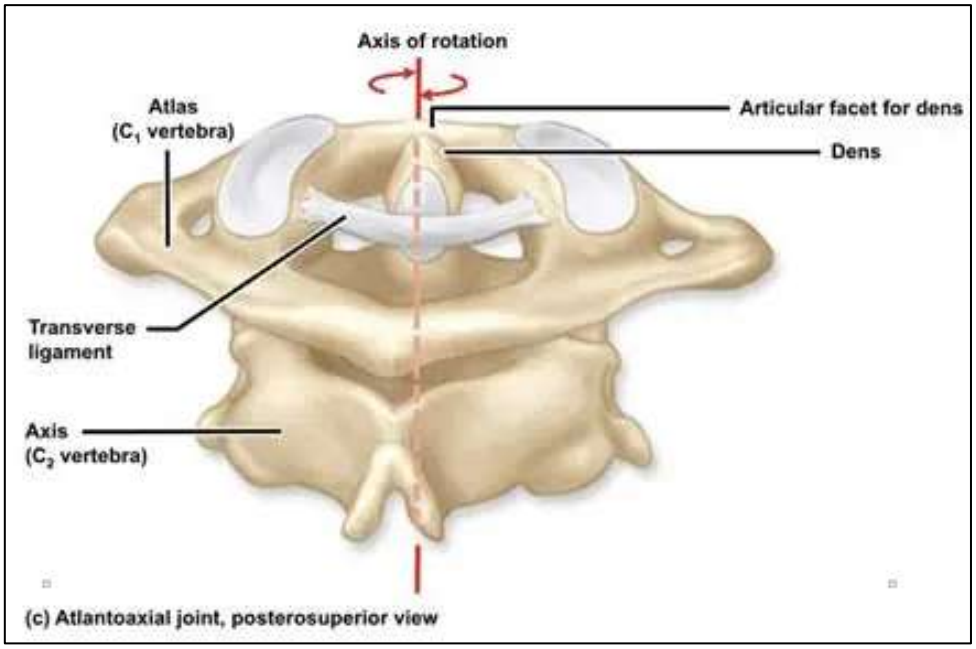

(3)

(A) **F** - Scalp skin is the thickest skin in the body.
(B) **T** - Aponeurosis of scalp.
(C) **T** - Aponeurosis countinous with frontalis → frontalis countinous with orbicularis occuli and skin.
(D) **T** - Through diploic veins.
(E) **F** - They gape if they're perpendicular.

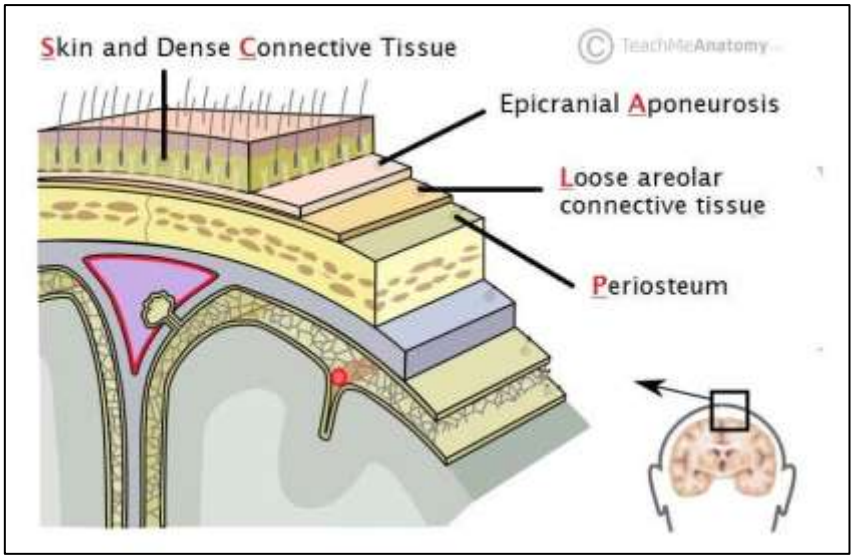

(4)

(A) **T -** The skull consists of the neurocranium, which encloses the brain, and the viscerocranium, which forms the facial skeleton.

(B) **T -** The neurocranium includes frontal (1), parietal (2), temporal (2), occipital (1), sphenoid (1), and ethmoid (1) bones.

(C) **F -** Most skull bones develop by intramembranous ossification, but some (e.g., base of skull) develop by endochondral ossification.

(D) **T -** Skull sutures are fibrous joints that allow growth of the skull during childhood and become immobile in adults.

(E) **T -** The mandible moves at the temporomandibular joint, making it the only freely movable bone of the skull.

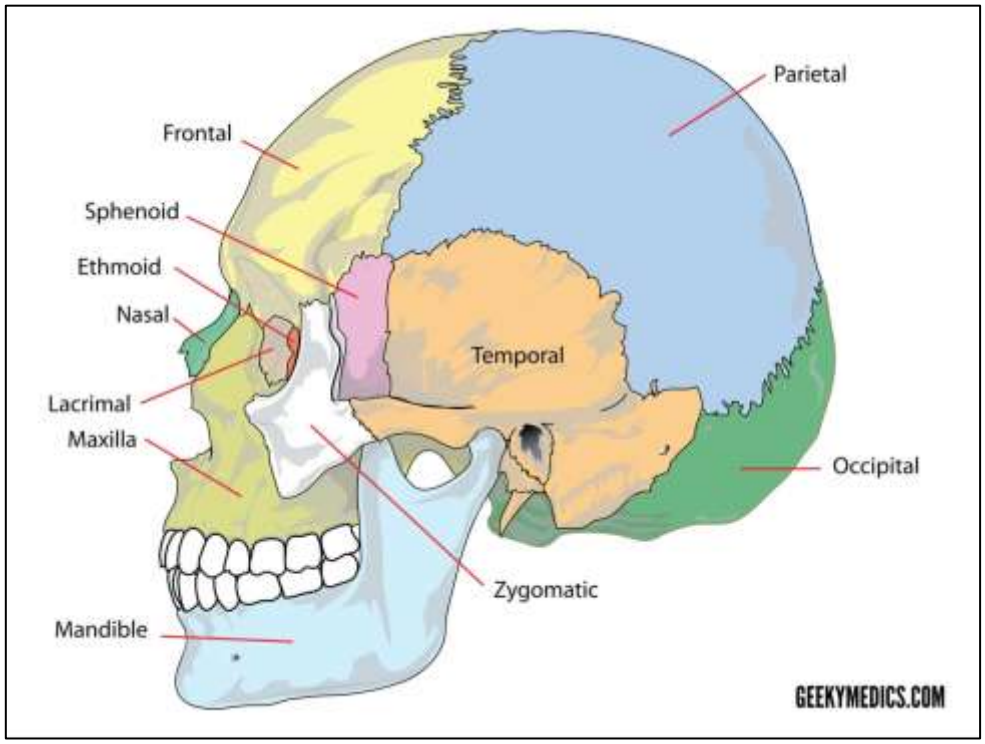

(5)

(A) **F -** Between C7 & T1.

(B) **T -** C7,C8 (pronation) & C6 (supination).

(C) **F -** Dermatome of the middle finger is C7.

(D) **F -** Parasympathetics have a craniosacral outflow and the sympathetics have a thoracolumbar outflow.

(E) **F** - Usually by C7.

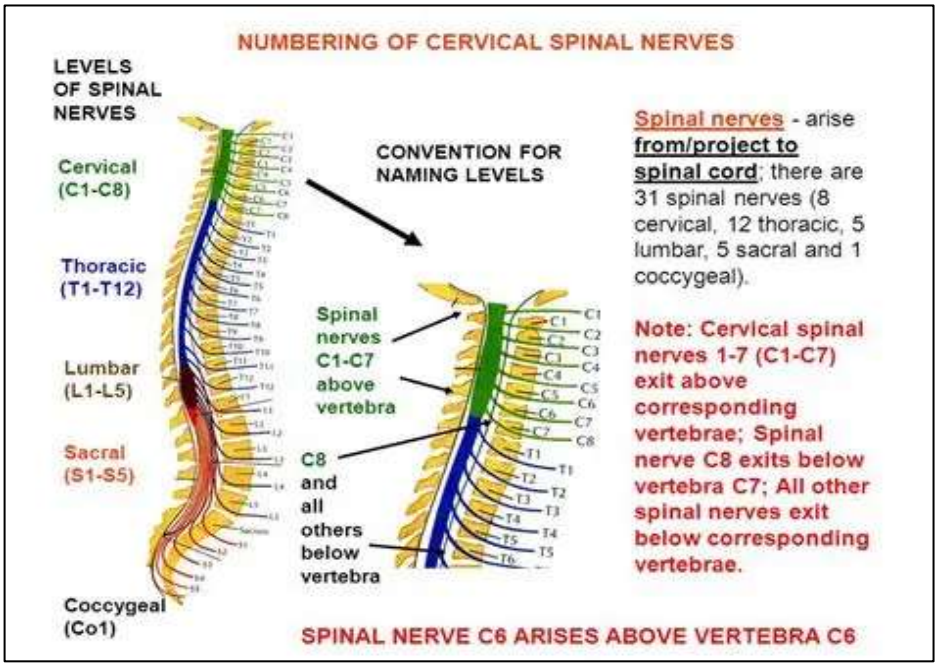

(6)

(A) **F** - Transverse axis of the vertebral body is the long axis.
(B) **F** - Superior facet directed upward and backward.
(C) **F** - Spine of thoracic vertebrae is long & directed downward and backward but in cervical vertebrae it is short and bifid.
(D) **F** - Has a triangular vertebral canal.
(E) **T** - All seven cervical vertebrae have foramen transversarium.

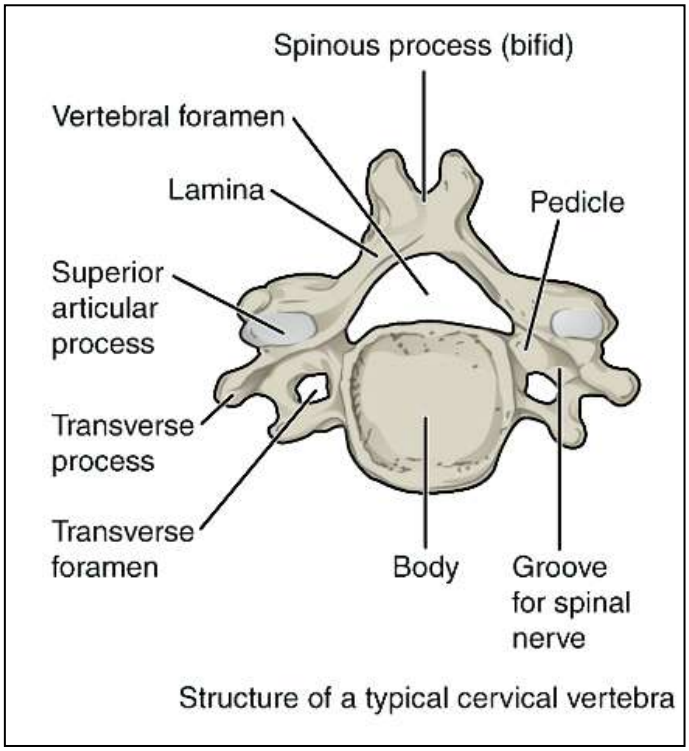

(7)

(A) **F** - The joints between the second to fifth cervical vertebrae allow flexion, extension, lateral flexion, and some rotation.
(B) **F** - Capsule of joint between articular processors are lax.
(C) **F** - Statement is true to atlanto axial joint which is separated from neural canal by transverse ligament but it is not typical joint.
(D) **T** - Joints between vertebral bodies are secondary cartilaginous.
(E) **F** - When movements of atlanto occipital joint it moves separately.

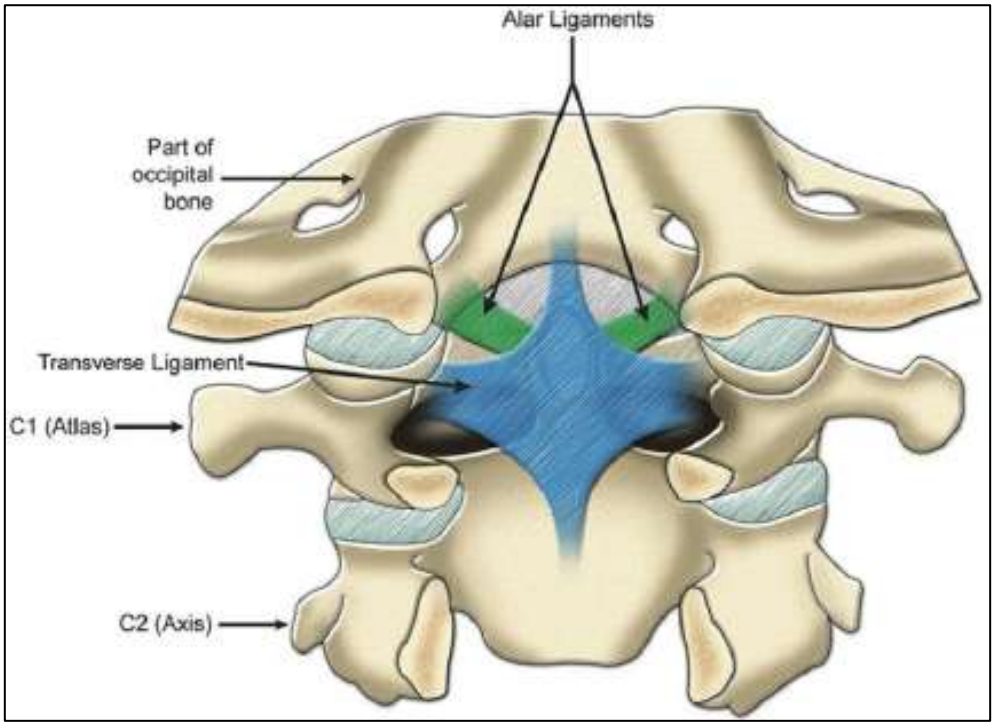

(8)

(A) **F**
(B) **T**
(C) **F**
(D) **F**
(E) **T**

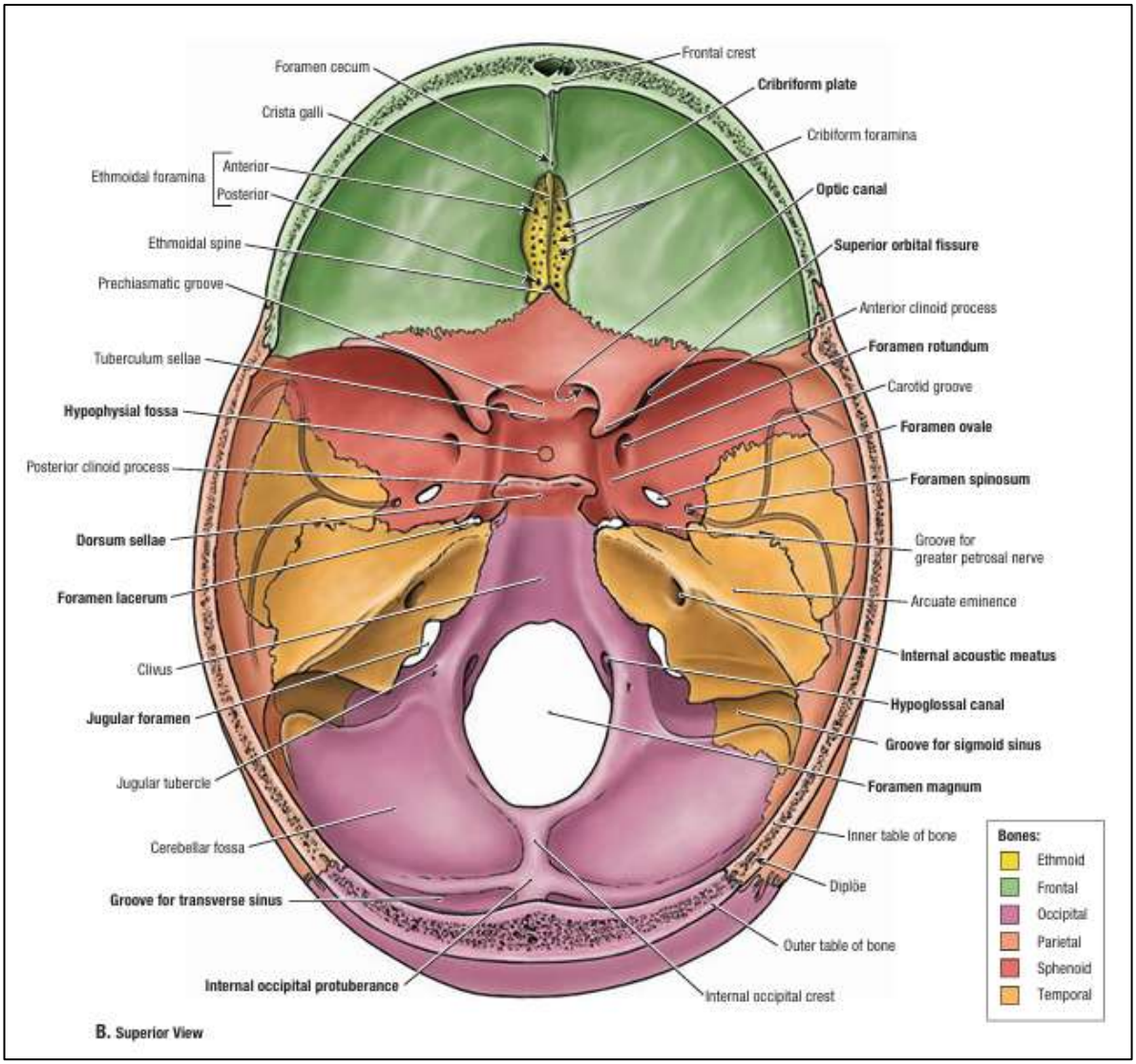

(9)

(A) **T**

(B) **T**

(C) **T**

(D) **T -** In MCF fracture blood and CSF may leak into sphenoidal air sinus and then into nose.

(E) **T -** black eye can occurs due to scalp injury.



(10) B

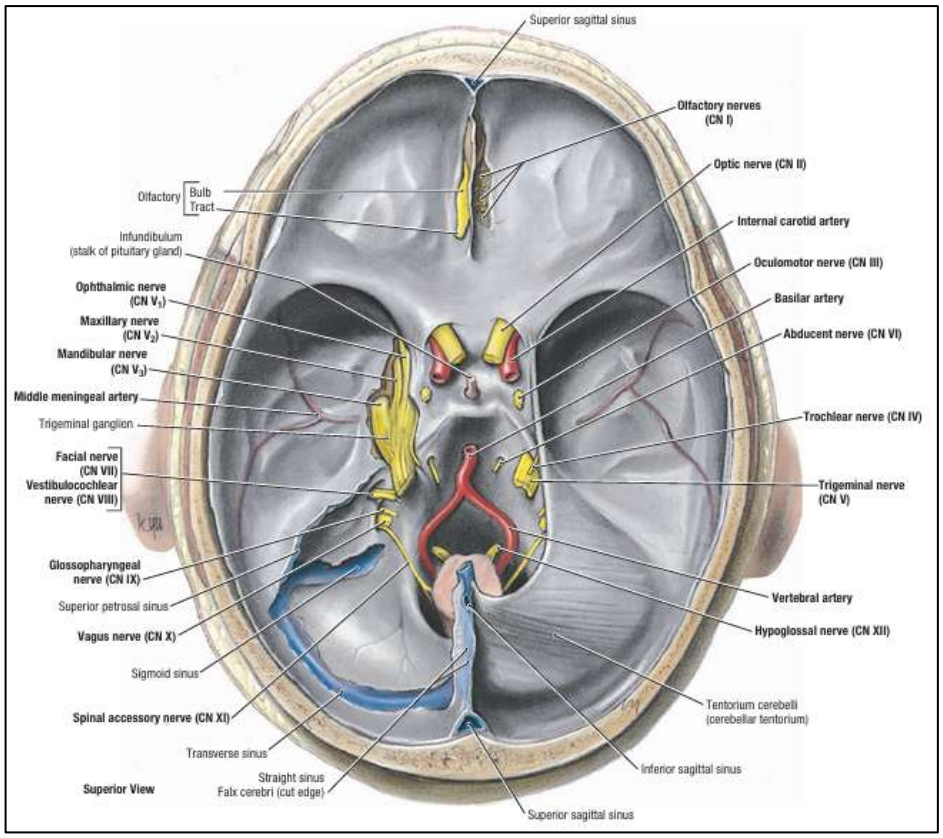

Internal acoustic meatus present in the posterior cranial fossa, therefore 8th cranial nerve entering it can be damaged. Other mentioned structures are likely to damage in injury to middle cranial fossa.

SGD 02 - Arteries, Veins & Lymphatic Drainage of the Head & Neck MCQs

(1) True or False regarding the scalp?

(A) Arteries of the scalp when cut readily close due to the elasticity of the arterial wall.
(B) Scalp is supplied by the internal carotid artery.
(C) Scalp injuries are the most common head injuries that should be treated with sutures.
(D) Superficial infections of the scalp can spread to intracranial venous sinuses via veins.
(E) Lymph from the anterior part of the scalp drains into the parotid lymph nodes.

(2) True or False regarding the scalp?

(A) It bleeds profusely when injured.
(B) Subaponeurotic hemorrhage is confined to bone.
(C) Osteitis and venous sinus thrombosis can be result in from superficial infection of the skull.
(D) Branches of internal and external carotid arteries are anastomosed.
(E) It is the commonest site for sebaceous cysts.

(3) True or False regarding the cavernous sinus?

(A) It has connections on either side around the infundibulum forming a plexus.
(B) It communicates with the internal vertebral venous plexus through the basilar plexus.
(C) It communicates with the deep cerebral veins.
(D) It forms a plexus around the hypophysis.
(E) The endothelium separates its blood from the internal carotid artery.

(4) Which are caused by cavernous sinus thrombosis?

(A) Protrusion of the eye
(B) Ptosis
(C) Papilledema
(D) Medial deviation of the eye ball
(E) Loss of elevation of the eye ball

(5) What are the structures that the lateral wall of the cavernous sinus contains?

(A) Frontal nerve
(B) Abducent nerve
(C) Mandibular nerve
(D) Oculomotor nerve
(E) Trochlear nerve

(6) True or False regarding the arterial supply of the scalp?

(A) Supratrochlear artery is a branch of the ophthalmic artery.
(B) Supraorbital artery supplies scalp up to the vertex.
(C) Superficial temporal artery is a branch of external carotid artery.
(D) Occipital artery supplies the frontal region of scalp.
(E) Posterior auricular artery contributes to scalp supply.

(7) True or False regarding the venous drainage of the scalp?

(A) Scalp veins accompany corresponding arteries.
(B) Supratrochlear vein drains into angular vein.
(C) Superficial temporal vein drains into external jugular vein.
(D) Occipital vein drains into subclavian vein.
(E) Scalp veins communicate with intracranial venous sinuses.

(8) True or False regarding the emissary veins and diploic veins?

(A) Emissary veins connect extracranial veins with dural venous sinuses.
(B) Emissary veins have valves.
(C) Parietal emissary vein connects scalp veins to superior sagittal sinus.
(D) Diploic veins lie in compact bone of skull.
(E) Diploic veins drain into dural venous sinuses.

(9) Which vein is most commonly involved in the spread of scalp infection to the cavernous sinus? (SBR)

(A) External jugular vein
(B) Occipital vein
(C) Angular vein
(D) Posterior auricular vein
(E) Retromandibular vein

(10) A 24-year-old male presents to the emergency department after a blow to the side of the head. He develops a brief loss of consciousness followed by a lucid interval and then rapid neurological deterioration. The injury is most likely associated with fracture at which skull landmark? (SBR)

(A) Asterion
(B) Bregma
(C) Lambda
(D) Pterion
(E) Nasion

SGD 02 - Arteries, Veins & Lymphatic Drainage of the Head & Neck MCQs Answers

(1)

(A) **F**

(B) **T**

(C) **T -** The tension of the epicranialapo neurosis produced by the tone of the occipitofrontalis muscles, is important in all deep wounds of the scalp. If the aponeurosis has been divided, the wound will gape open for satisfactory healing to take place, the opening on the aponeurosis must be closed with sutures.

(D) **T** - Infections of the scalp spreads by the emissary veins, which are valueless, to the skull bones, causing osteomyelitis. Infected blood in the diploid veins may travel by the emissary veins further into the venous sinuses and produce venous sinus thrombosis.

(E) **F** - Anterior part of the scalp and forehead drain into the submandibular lymph nodes.

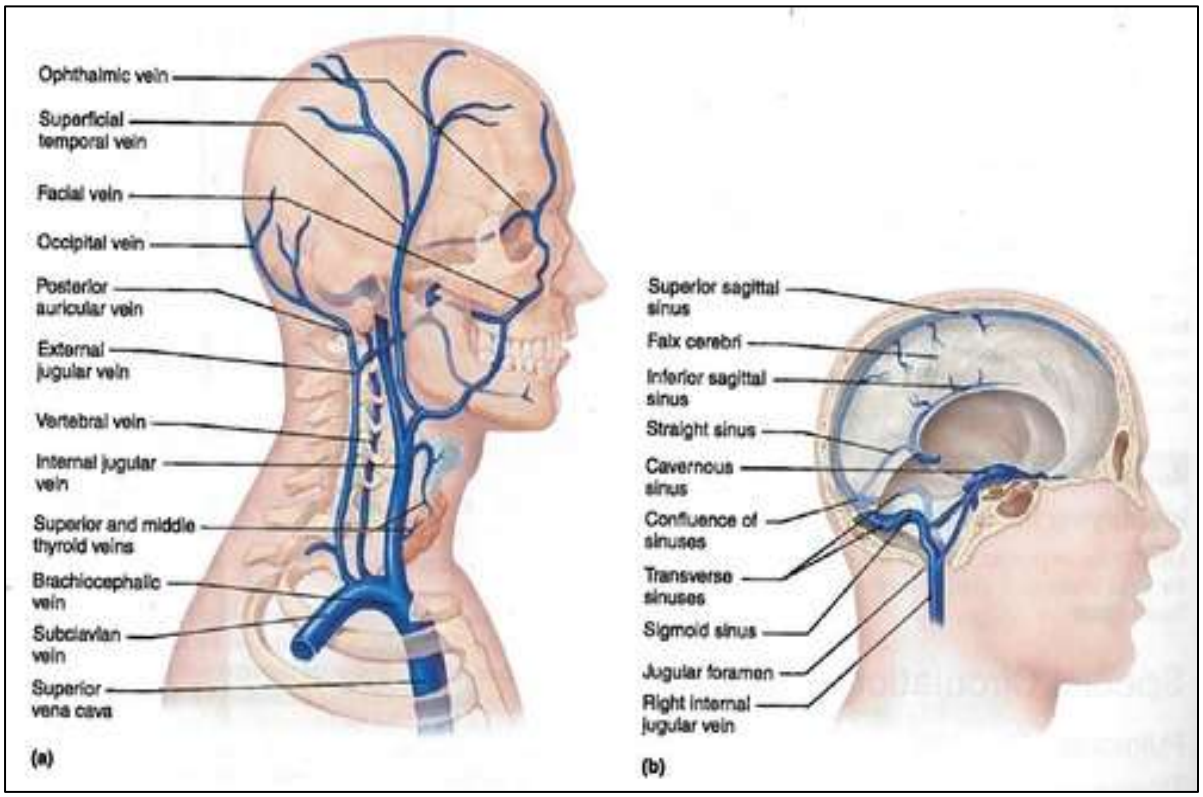

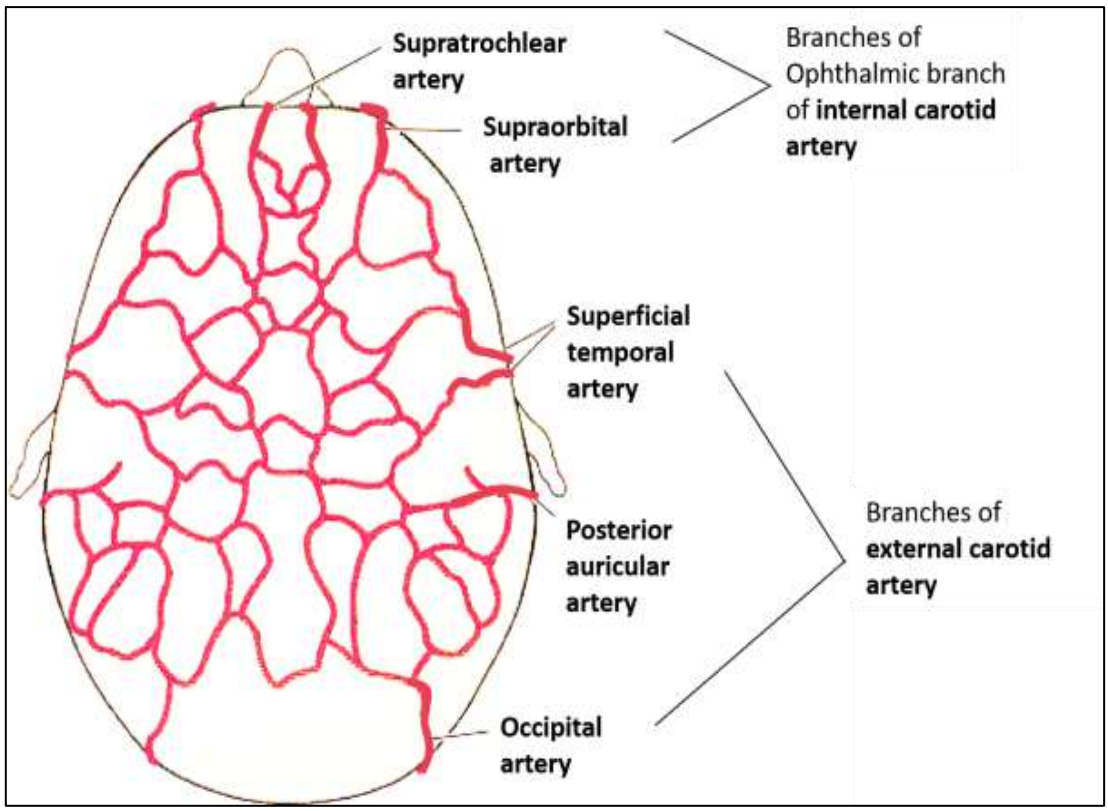

(2)

(A) **T -** The scalp has a rich vascular supply from both internal and external carotid artery branches (above figure).

(B) **F -** A subaponeurotic hemorrhage occurs in the loose areolar tissue layer, which allows blood to spread widely.

(C) **T -** Emissary veins connect superficial scalp veins to the intracranial venous sinuses. Infection can track through these veins, potentially causing osteitis of skull bones and venous sinus thrombosis, especially involving the superior sagittal sinus.

(D) **T -** Scalp circulation shows extensive arterial anastomoses between: Internal carotid: supratrochlear, supraorbital. External carotid: superficial temporal, occipital, posterior auricular

(E) **T -** The scalp contains numerous sebaceous glands and hair follicles, making it a frequent site for sebaceous (epidermoid) cysts.

(3)

(A) **T -** Right and left parts of the cavernous sinus are interconnected by the intercavernous sinus.

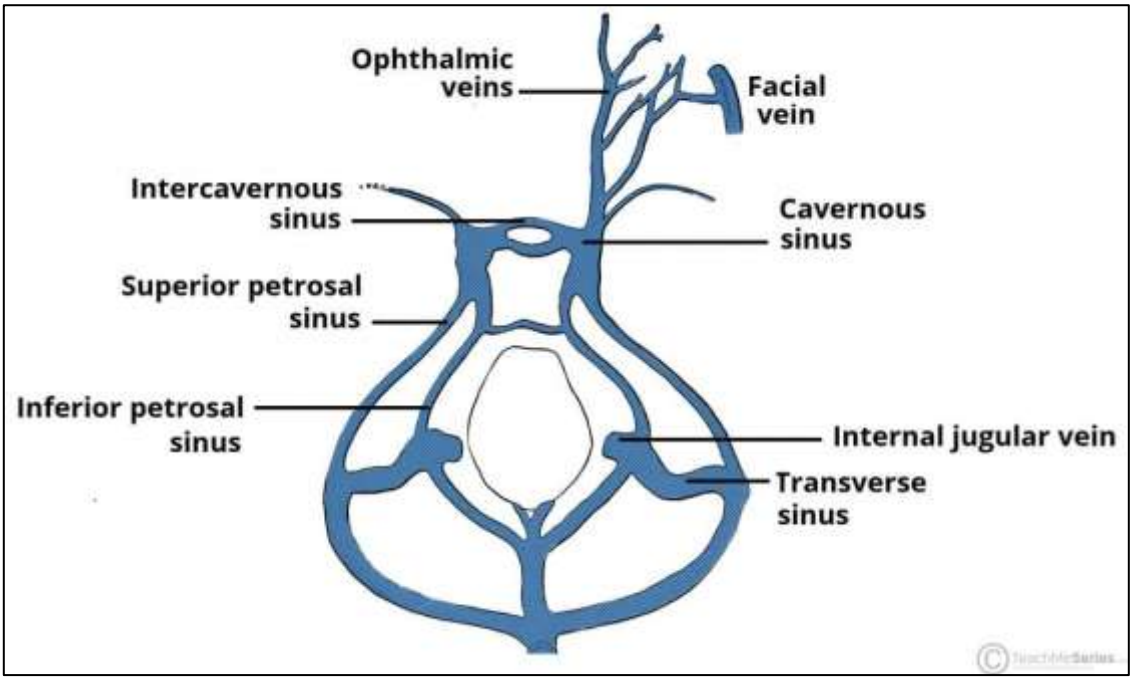

(B) **T**

(C) **F -** Superficial and middle cerebral veins.

(D) **T**

(E) **T**

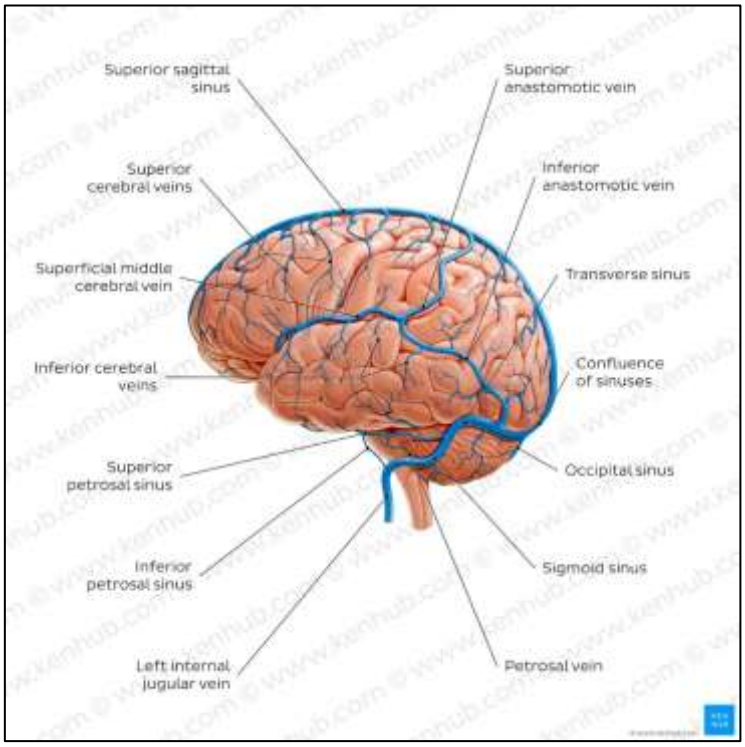

(4)

(A) **T**
(B) **T**
(C) **T**
(D) **T**
(E) **T**

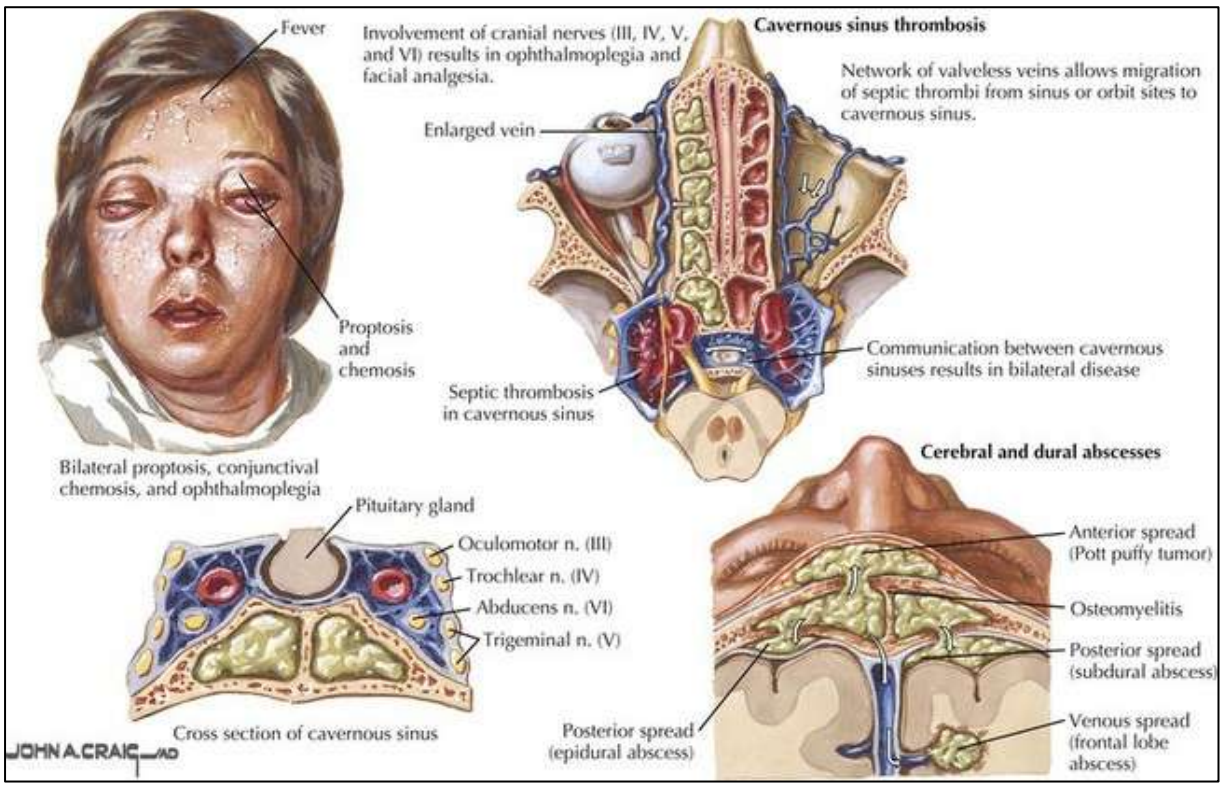

(5)

(A) **F**
(B) **F**
(C) **F**
(D) **T**
(E) **T**

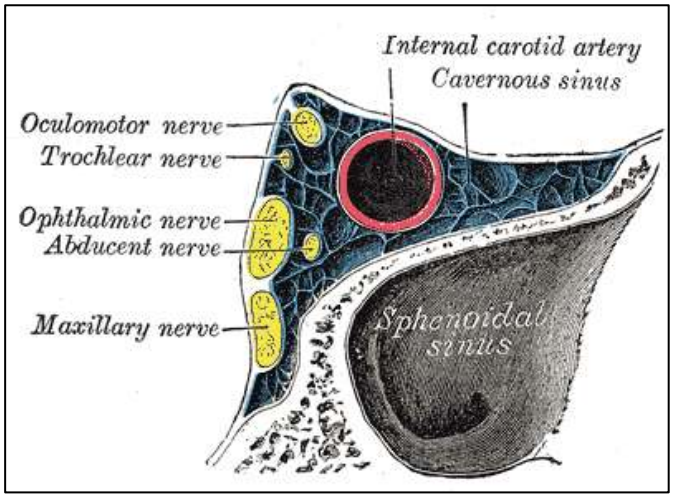

(6)

(A) **T** - Supratrochlear artery arises from ophthalmic artery (ICA) and supplies anterior scalp.
(B) **T** - Supraorbital artery ascends over forehead to reach vertex.
(C) **T -** One of the terminal branches of external carotid artery.
(D) **F** - Occipital artery supplies posterior scalp.
(E) **T** - Supplies area posterior to auricle and adjacent scalp.

(7)

(A) **T -** Veins generally follow arteries in the scalp.
(B) **T -** Angular vein is formed by supratrochlear and supraorbital veins.
(C) **F** - It joins maxillary vein to form retromandibular vein.
(D) **F** - Drains into external jugular or vertebral venous system**.**
(E) **T -** Via emissary veins, important for spread of infection.

For (6) & (7) refer question (1) pictures.

(8)

(A) **T -** They pass through skull foramina.
(B) **F** - They are valveless, allowing bidirectional flow.
(C) **T -** Clinically important route for infection spread.
(D) **F** - They lie in diploë between inner and outer tables.
(E) **T -** Drainage occurs via emissary and meningeal veins

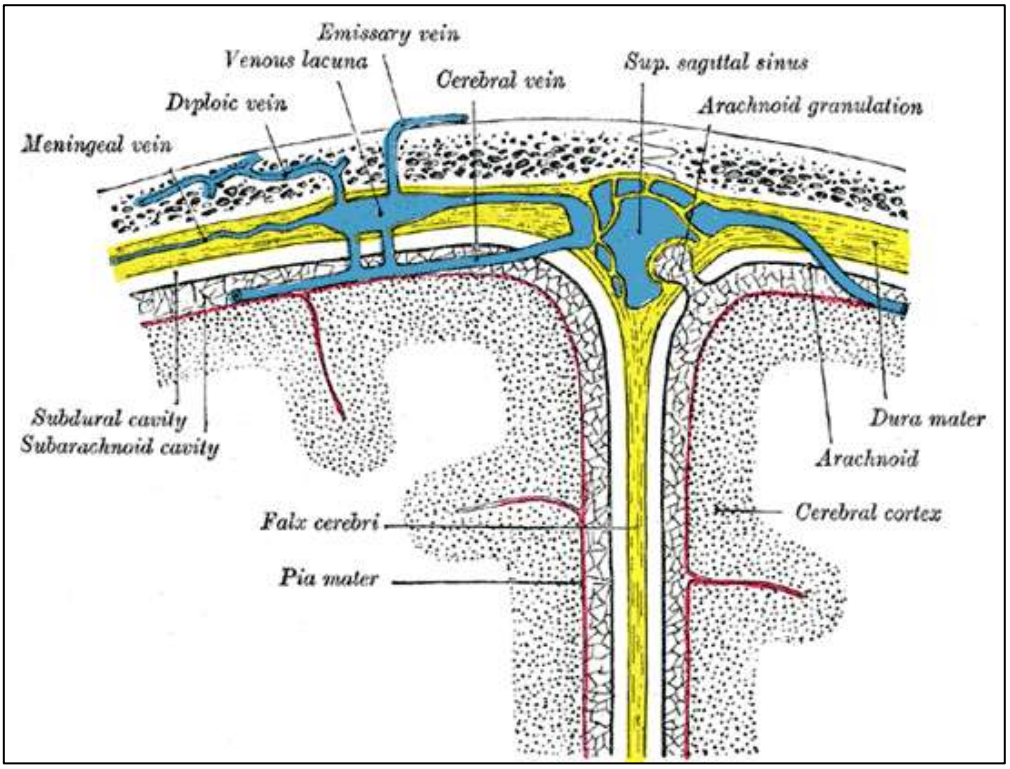

(9) **C**

Angular vein communicates with superior ophthalmic vein, which drains into the cavernous sinus, making it a dangerous route for infection spread.

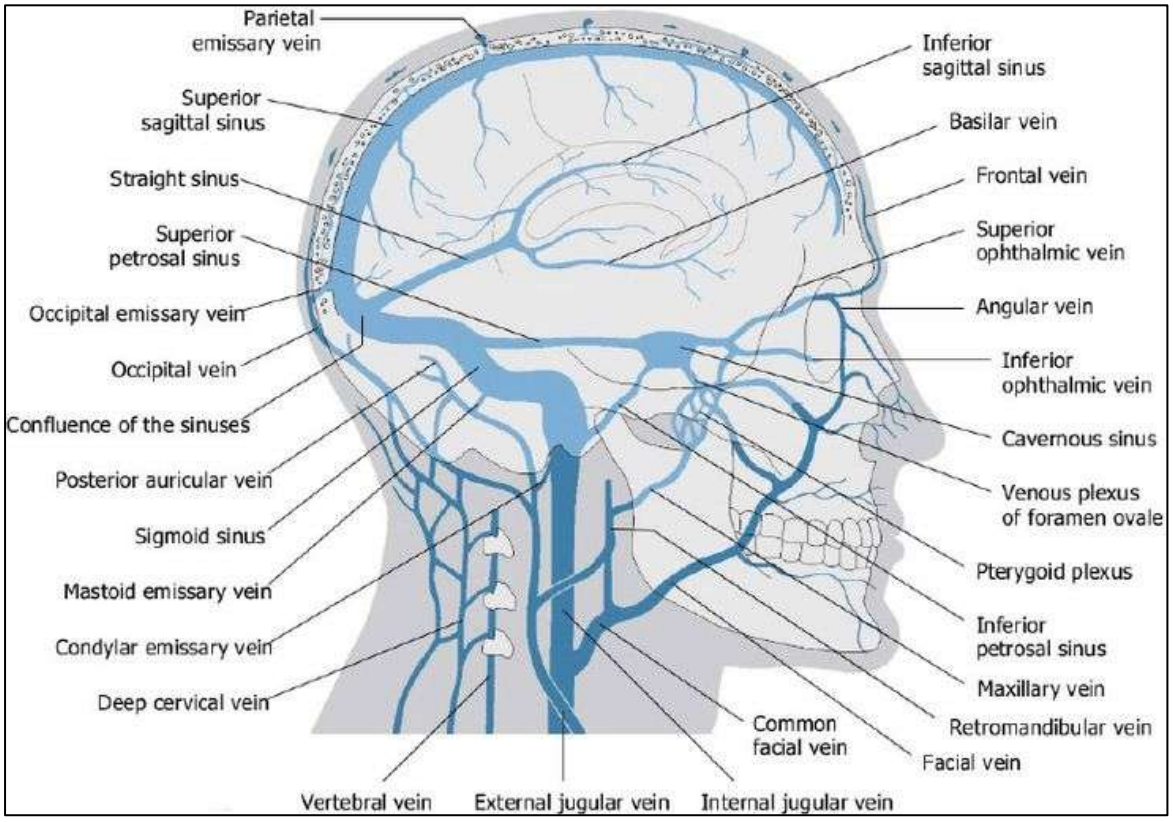

(10) **D**

The pterion is a thin area on the lateral aspect of the skull formed by the junction of the frontal, parietal, squamous temporal, and greater wing of sphenoid bones. It overlies the anterior division of the middle meningeal artery. A fracture at the pterion may rupture this artery, resulting in an extradural (epidural) hematoma, classically presenting with a lucid interval followed by rapid neurological deterioration. Due to this relationship, the pterion is regarded as a clinically dangerous area of the skull.

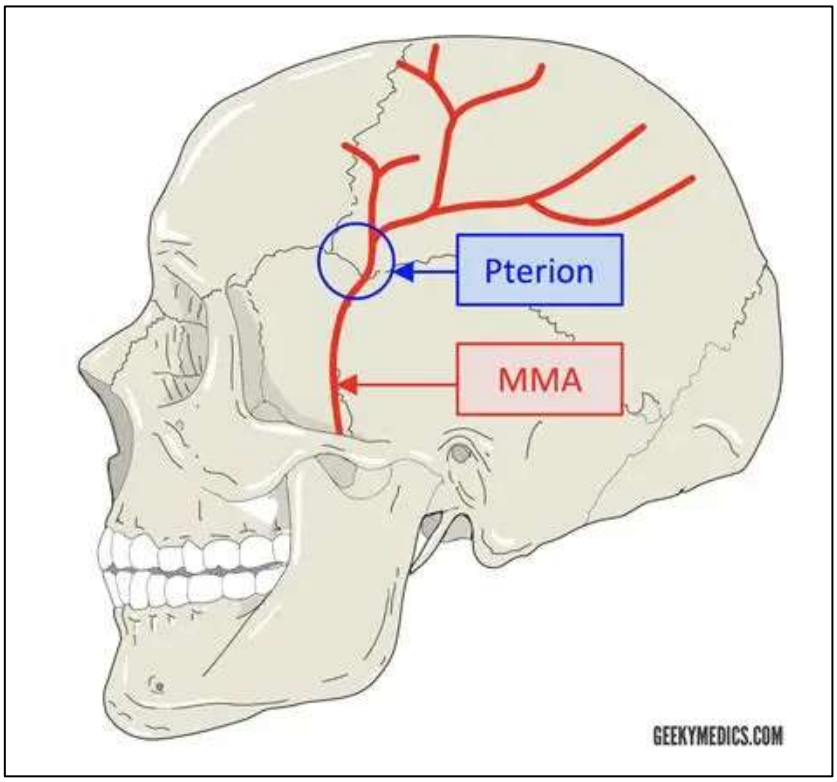
Pterion
MMA
GEEKYMEDICS.COM

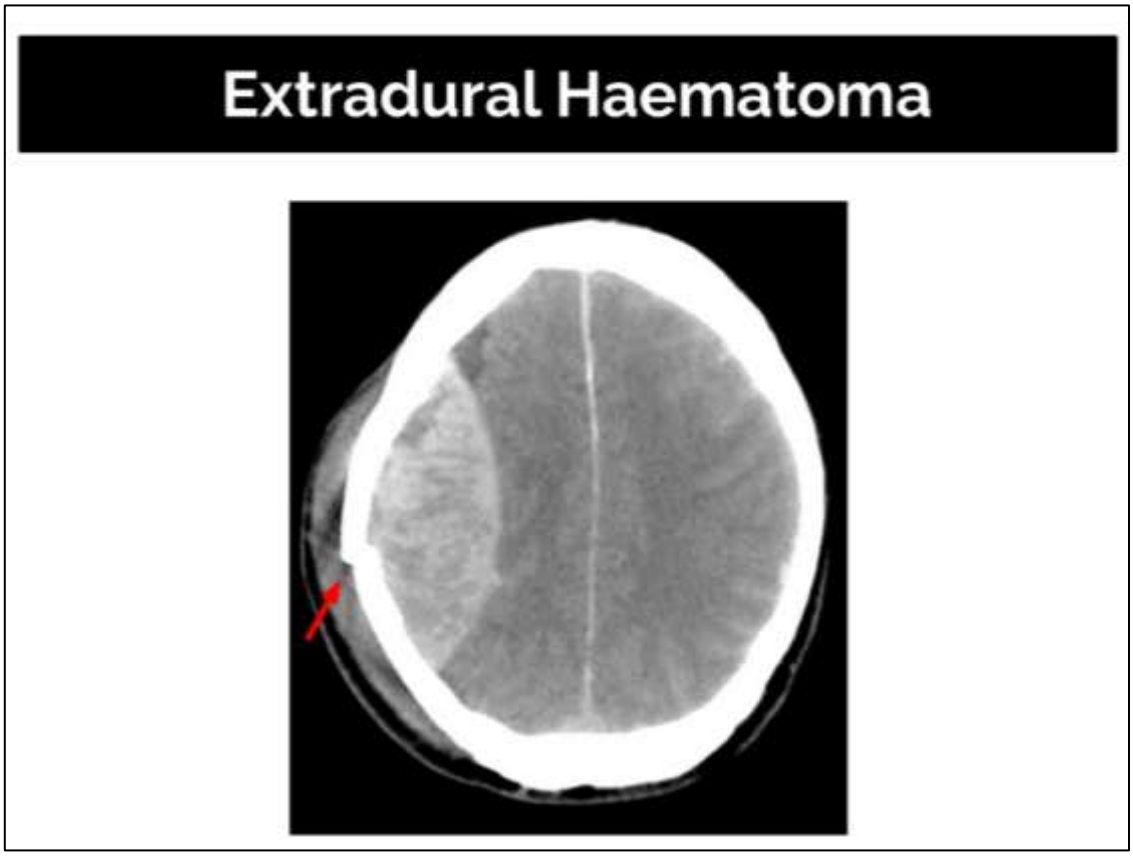
Extradural Haematoma

SGD 03 - Anatomy of Neck

(1)

(1.1) State the boundaries of the posterior triangle of the neck. (10 Marks)

(1.2) State the vertebral levels of the following. (40 Marks)

(a) Bifurcation of the common carotid artery

(b) Hard palate

(c) Hyoid bone

(d) Cricoid cartilage

(1.3) Describe the arrangement of fascia in the neck. You may use diagrams to illustrate your answer. (50 Marks)

(Total = 100 Marks)

(2) A 59-year-old man was admitted to a surgical casualty with bleeding from an oral carcinoma eroding into the right cheek. The bleeding was stopped by ligation of the external carotid artery in the carotid triangle.

(2.1) State two anatomical features that help to differentiate the external carotid artery from the internal carotid artery within the carotid triangle. (20 Marks)

(2.2) List the branches of the external carotid artery. (20 Marks)

(2.3) Describe the anterior triangle of the neck. (60 Marks)

(Total = 100 Marks)

SGD 03 - Anatomy of Neck Answers

(1)

(1.1) State the boundaries of the posterior triangle of the neck.

Anterior border – posterior border of sternocleidomastoid

Posterior border – anterior border of trapezius

Base – gap on the superior nuchal line between the attachment of sternocleidomastoid and trapezius

Roof- skin, superficial fascia and investing layer of deep cervical fascia

Contents

- Arteries - occipital, transverse cervical, suprascapular and subclavian
- Veins- transverse cervical, suprascapular and external jugular
- Nerves- cervical plexus branches and brachial plexus trunks
- Omohyoid muscle
- Lymph nodes

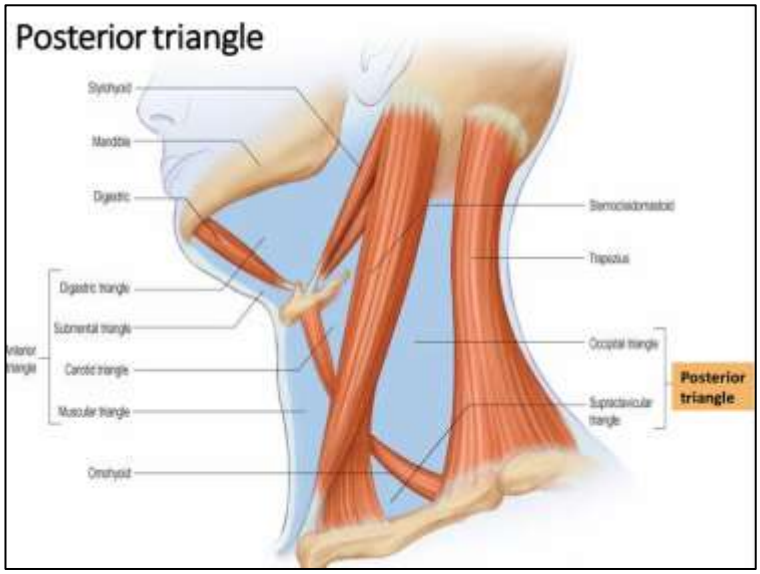

(1.2) State the vertebral levels of the following.

(a) Bifurcation of the common carotid artery
Upper border of C4

(b) Hard palate
C1

(c) Hyoid bone
C3

(d) Cricoid cartilage
C6

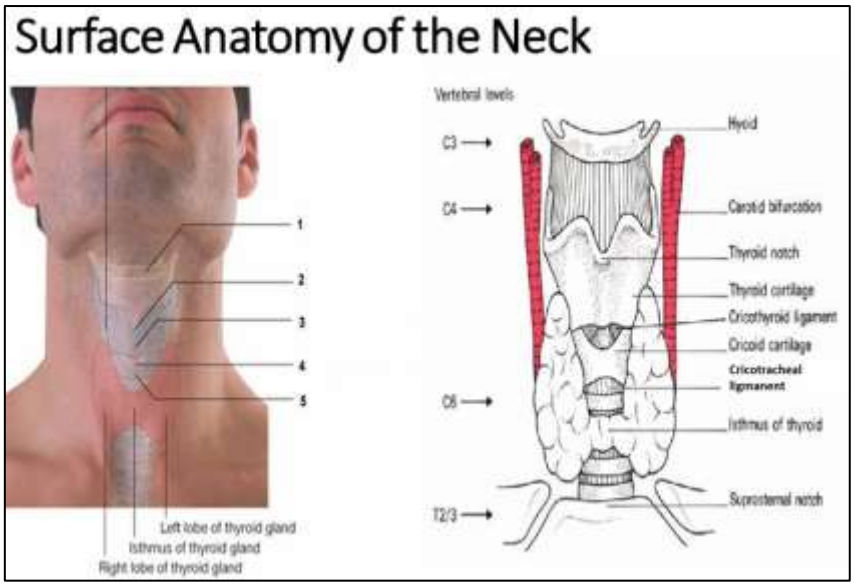

(1.3) Describe the arrangement of fascia in the neck with illustrations.

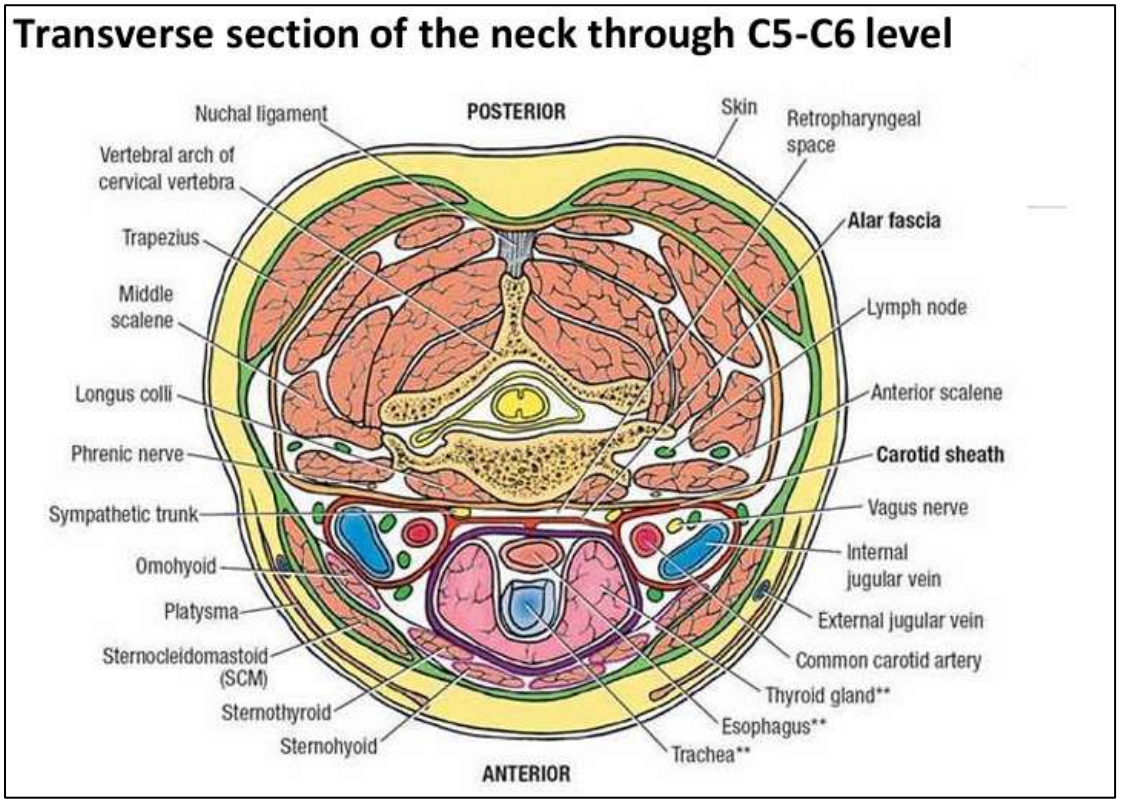

- There are **two main groups** of fascia in the neck.
- The **superficial cervical fascia** and the **deep cervical fascia.**
- The superficial cervical fascia lies underneath the skin and above the deep cervical fascia and contains the platysma, superficial veins, lymph nodes and cutaneous nerves and It is made primarily out of areolar tissue.
- The deep cervical fascia lies deep to the superficial cervical fascia and consists of **4 parts**; the investing layer, the pretracheal fascia, the prevertebral fascia and the carotid sheath.
- **The investing layer** of the deep cervical fascia is like a collar surrounding the deep structures of the neck and the other parts of the deep cervical fascia.

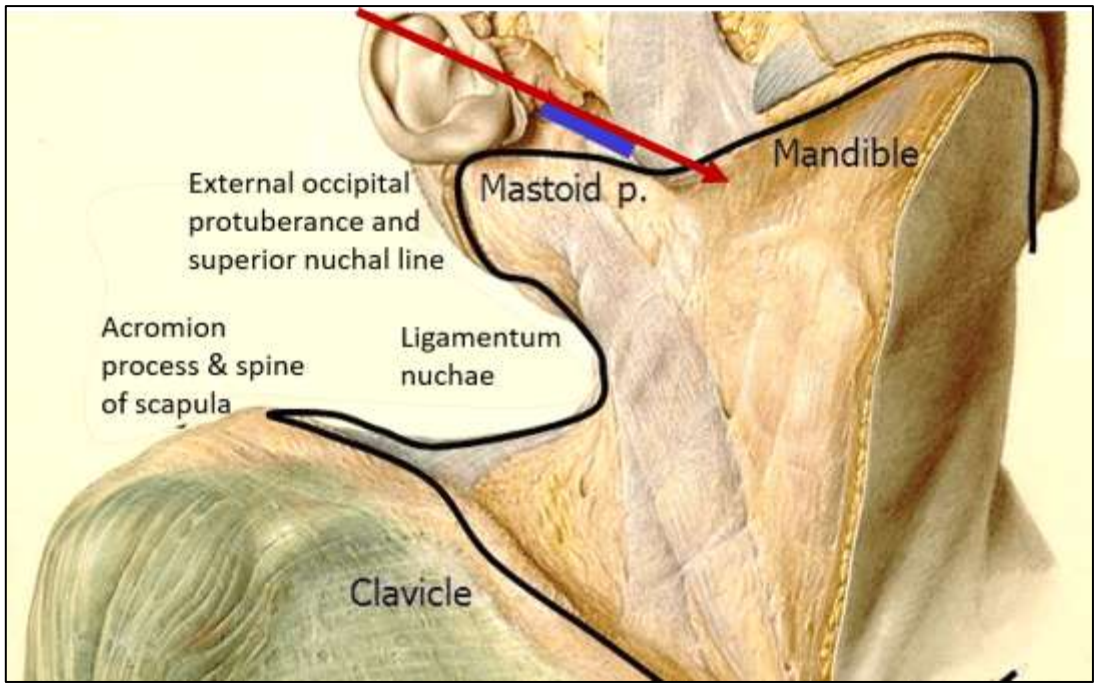

- It blends posteriorly with the ligamentum nuchae, which is attached to the spine of the cervical vertebrae and anteriorly is attached to the hyoid bone.
- Above the attachment of the hyoid bone, the investing layer is attached to the lower border of the mandible then to the mastoid process. From there it is attached along the superior nuchal line to the external occipital protruberance at the base of the skull.
- Between the mastoid process and the mandible, it splits into two layers and the superficial layer covers the parotid gland as the paratidomasseteric fascia and attaches superiorly to the zygomatic arch.
- The deep layer goes underneath the parotid gland and attaches to the styloid process (and the angle of the mandible) and it thickens to form the stylomandibular ligament.

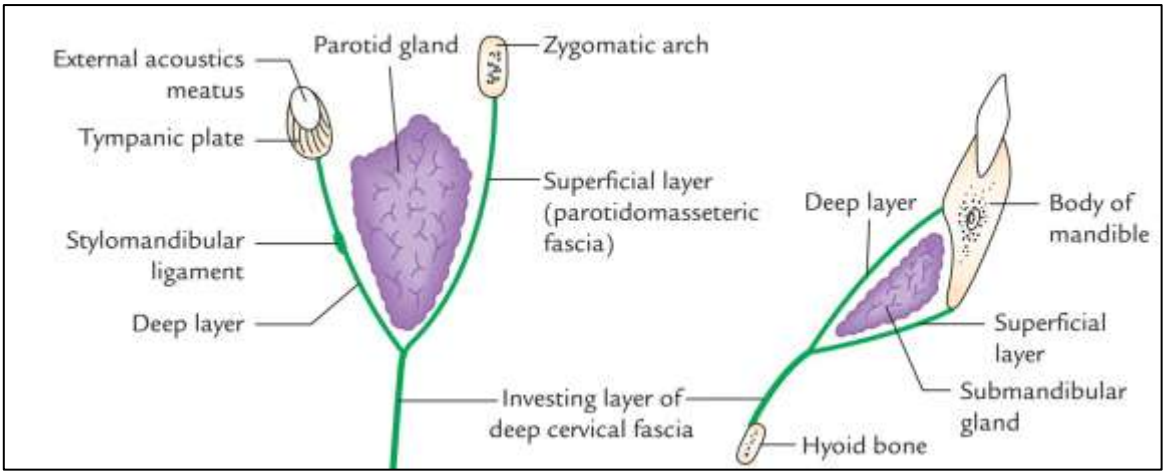

- Inferiorly attached to the spine of scapula and clavicle and manubrium.
- Above its attachment to the clavicle and the jugular notch, the fascia splits into two layers and attaches separately to these structures.
- These splitting forms a small space above the jugular notch called the **suprasternal space**.
- The suprasternal space contains the lower parts of the anterior jugular veins, their anastomotic arch, and a lymph node.

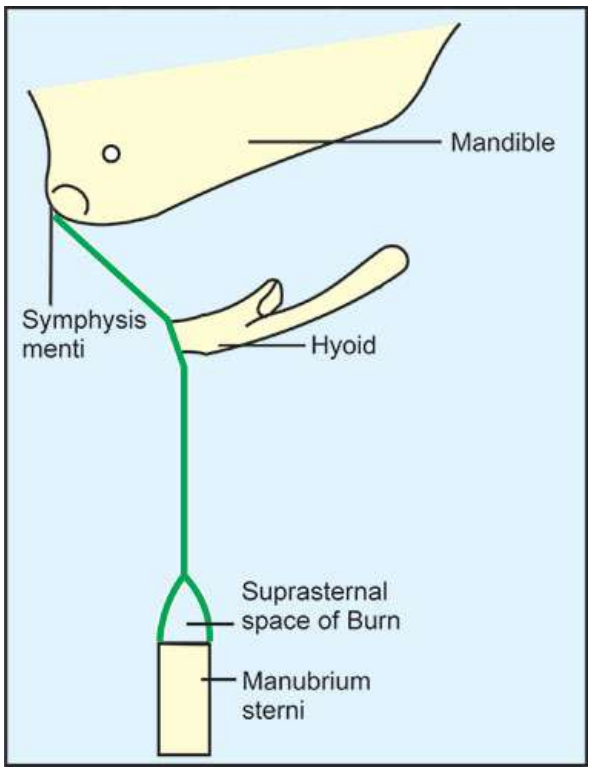

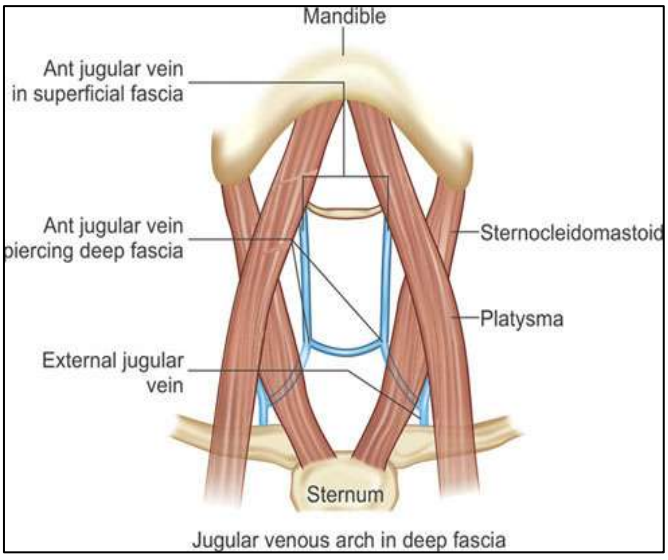

- The investing layer is pierced by the external jugular vein, internal jugular vein, and cutaneous nerves.

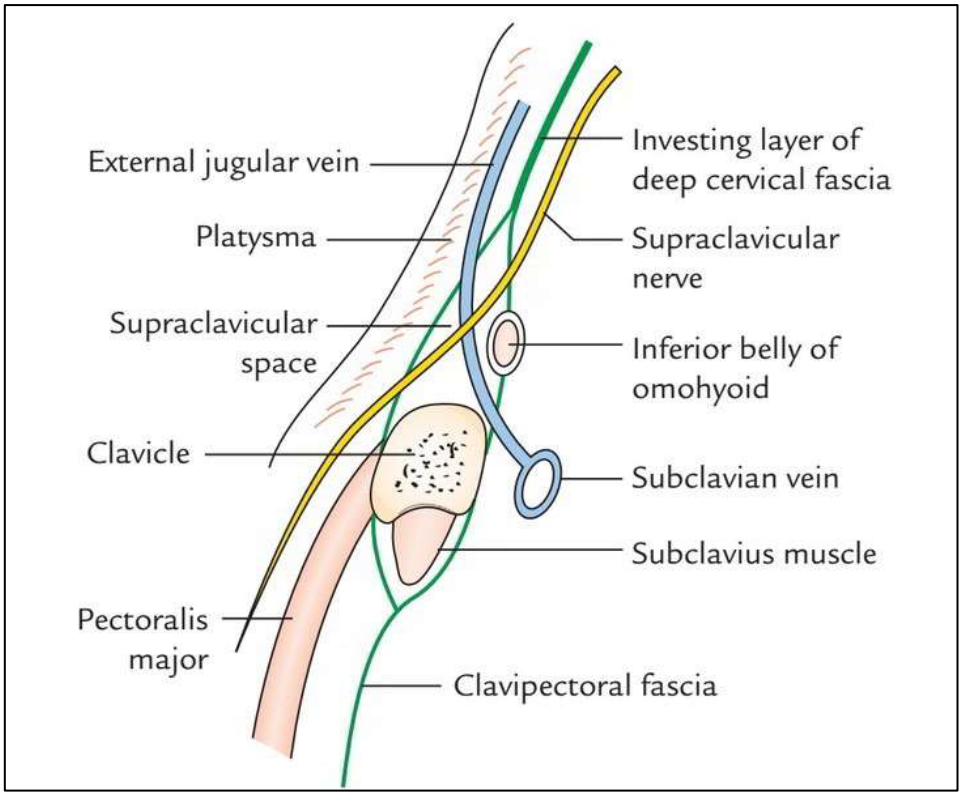

- **The prevertebral fascia** lies infront of the prevertebral muscles and extends from the base of the skull to the anterior longitudinal ligament of the T4 vertebra.

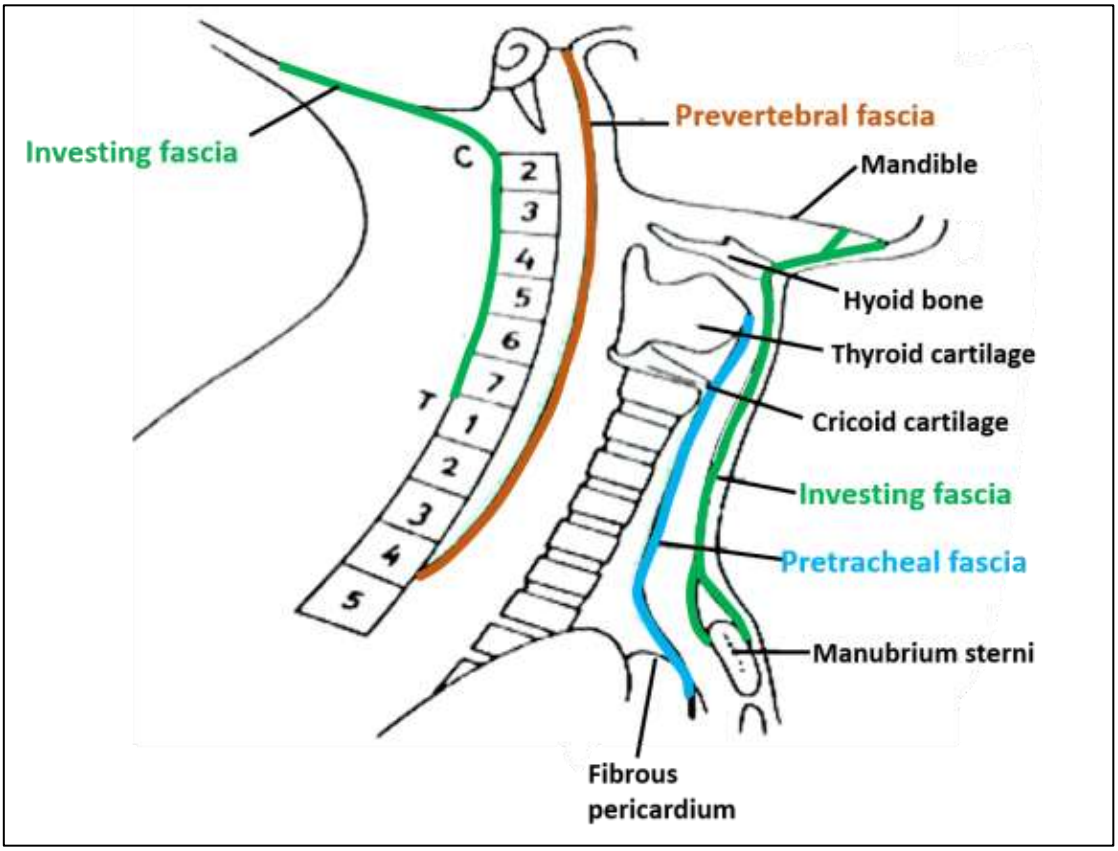

- It covers the muscles that form the floor of the posterior triangle and all the cervical nerve roots.
- The 3rd part of the subclavian artery lies deep to the fascia and as it enters the upper limb, the fascia gets prolonged with it and the brachial plexus below, but it does not invest the subclavian or the axillary vein allowing them to freely dilate during times of increased venous return.
- The fascia is pierced by the 4 cutaneous branches of the cervical plexus. (Great auricular, lesser occipital, transverse cervical and the supraclavicular nerves.

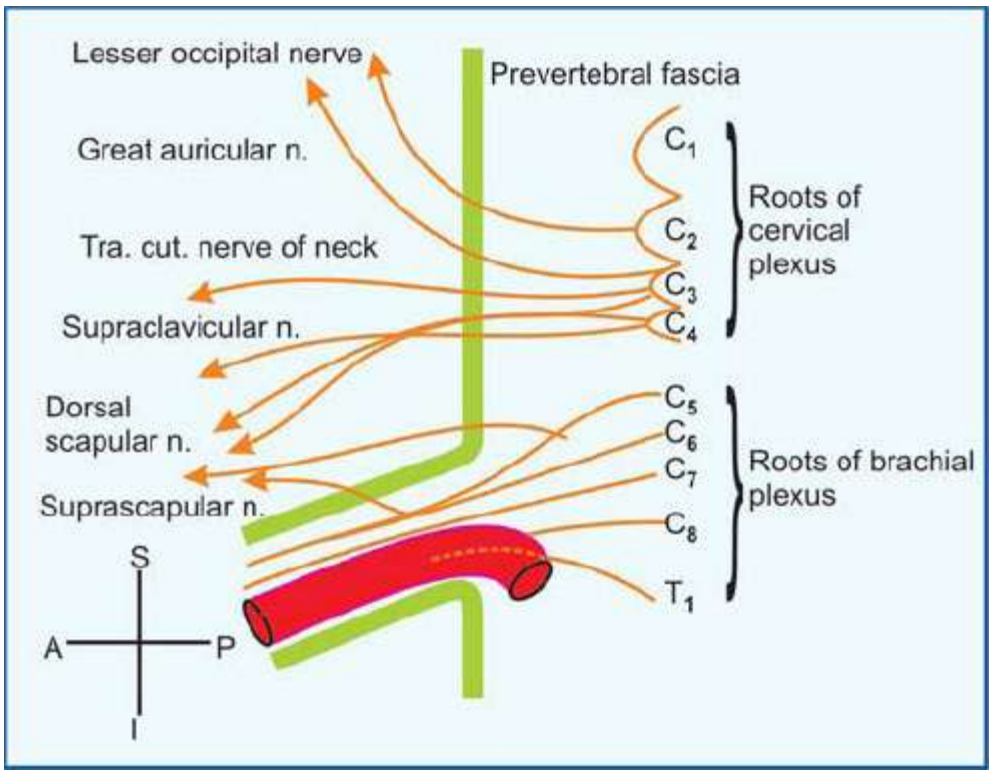

- **The pretracheal fascia**, covers the innermost components of the neck, such as the pharynx, oesophagus, larynx and trachea.
- It is attached to the body of the hyoid bone, oblique line of the thyroid cartilage superiorly and whilst fusing with the carotid sheath on the deep surface of the sternocleidomastoid, it fuses inferiorly with the adventitia of the arch of the aorta.
- The pretracheal faschia lies deep to the infrahyoid muscles and it splits to enclose the thyroid gland.
- The pretracheal fascia is not adherent to the thyroid gland except at the isthmus where it is also adherent to the second and third and fourth rings of the trachea.

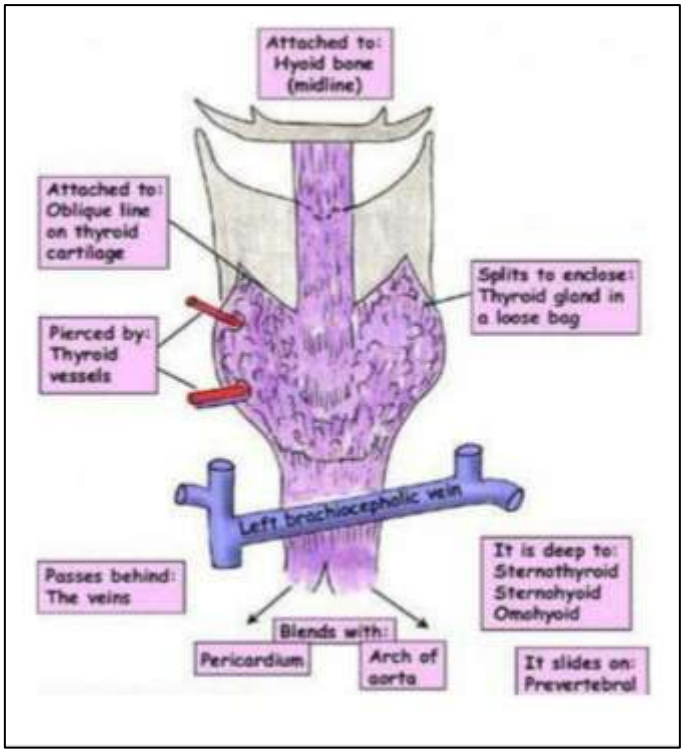

- **The carotid sheath** is a feltwork of areolar tissue that surrounds the common carotid below the thyroid cartilage and the internal carotid above the thyroid cartilage and the vagus nerve and the internal jugular vein.
- The sheath is attached to the base of the skull around the openings of the carotid canal and the jugular foramen and continues downwards following the vessels and blends with the adventitia of the aortic arch.
- Deep to the sternocleidomastoid it fuses with the pretrachea fascia.
- The cervical sympathetic trunk lies posterior to the carotid sheath but infront of the prevertebral sheath and is an important anatomical relation.

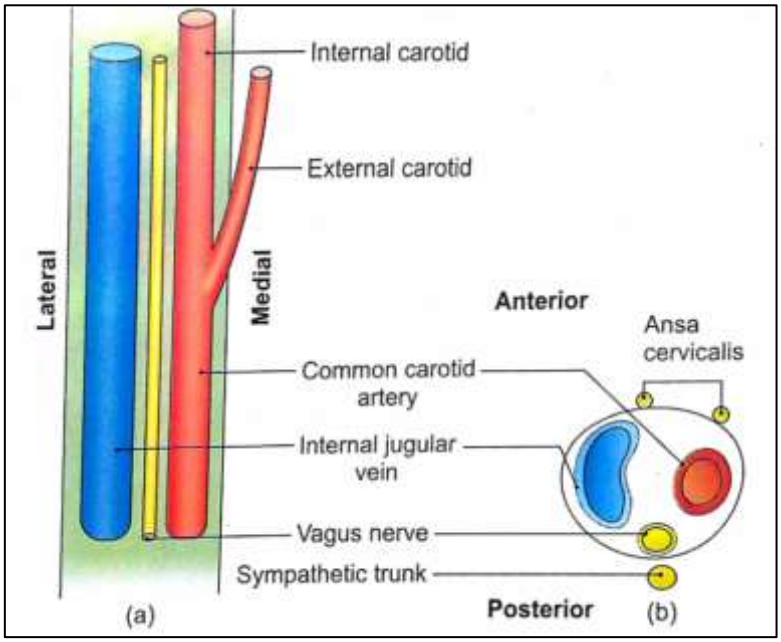

(2)

(2.1) State two anatomical features that help to differentiate the external carotid artery from the internal carotid artery within the carotid triangle.

- The **external carotid artery** gives away **several branches** in the neck whereas the **internal carotid artery has no branches in the neck.**
- The **lower part** of the artery, which is the part located in the **carotid tria**ngle is situated anterior and medial to the internal carotid artery.
- The **internal jugular vein** is situated just lateral to the internal carotid artery in close proximity to it, but laterally in close proximity to the external carotid artery is the internal carotid artery.

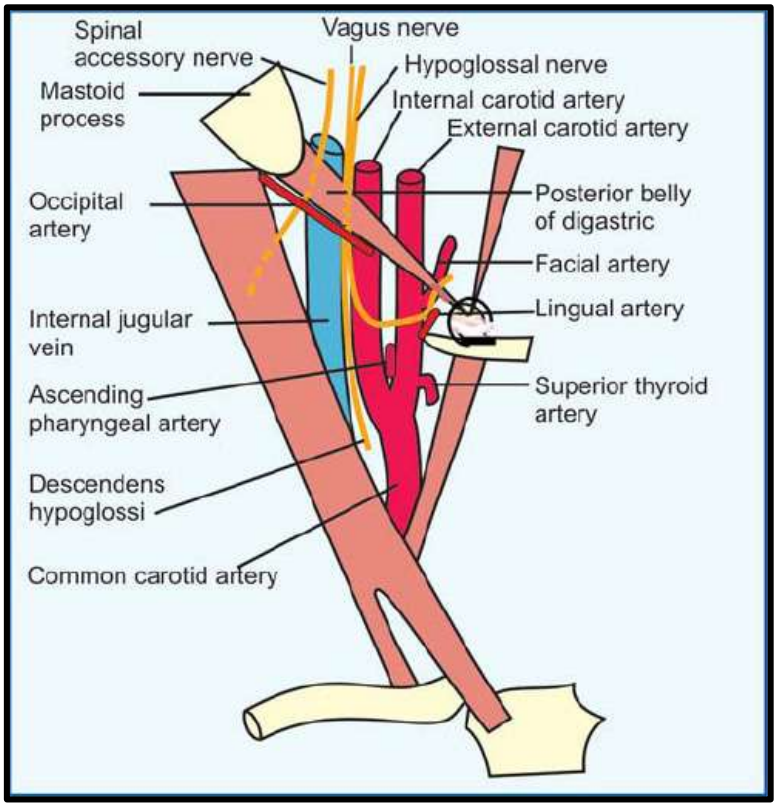

(2.2) List the branches of the external carotid artery.

- Superior thyroid artery
- Ascending pharyngeal artery
- Lingual artery
- Facial artery
- Occipital artery
- Posterior auricular artery
- Superficial temporal artery
- Maxillary artery

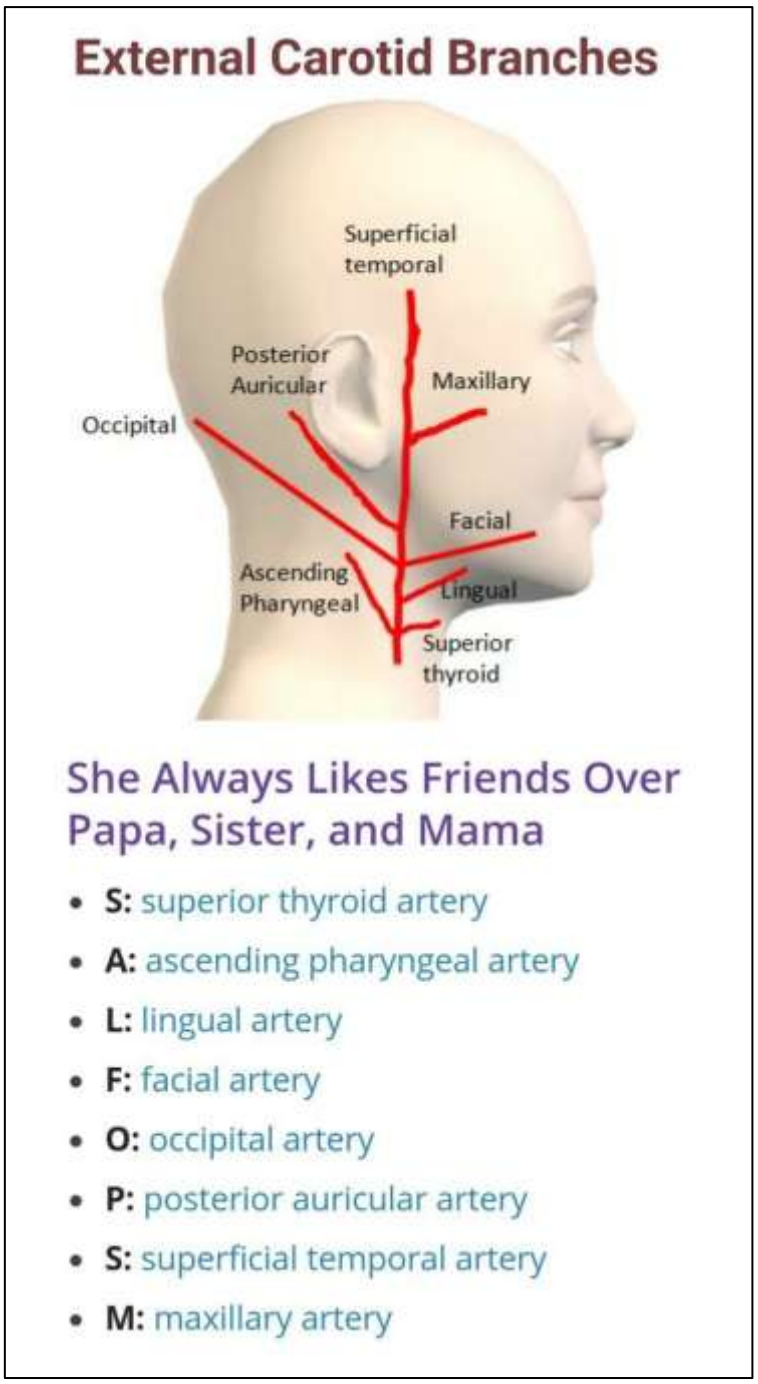

(2.3) Describe the anterior triangle of the neck.

- The region of the neck is subdivided into **two major triangles, the anterior and posterior** by the **sternocleidomastoid muscle.**
- The anterior triangle is an anatomical division created by muscles in head and neck. The anterior triangle is situated in front of the neck.

Boundaries:

- Superiorly: inferior border of mandible
- Laterally: medial border of sternocleidomastoid
- Medially: imaginary sagittal line drawn in the midline of the neck

The triangle is inverted with its apex inferior to the base.

- Roof: Skin, superficial fascia and investing layer of deep cervical fascia
- Floor

Contents:

- Suprahyoid muscles (stylohyoid, digastric, mylohyoid , and geniohyoid) and infrahyoid muscles (omohyoid, sternohyoid, thyrohyoid and sternothyroid).
- The common carotid artery passes through the anterior triangle, and bifurcates within the triangle into the external and internal carotid arteries.
- The internal jugular vein also can be found within this area.
- The cranial nerves in the anterior triangle are the facial (VII), vagus (X), accessory (XI) and hypoglossal (XII) nerves.

The anterior triangle can be further subdivided into **four triangles**, they are

1. Carotid triangle
2. Submental Triangle
3. Submandibular/ Digastric Triangle
4. Muscular Triangle

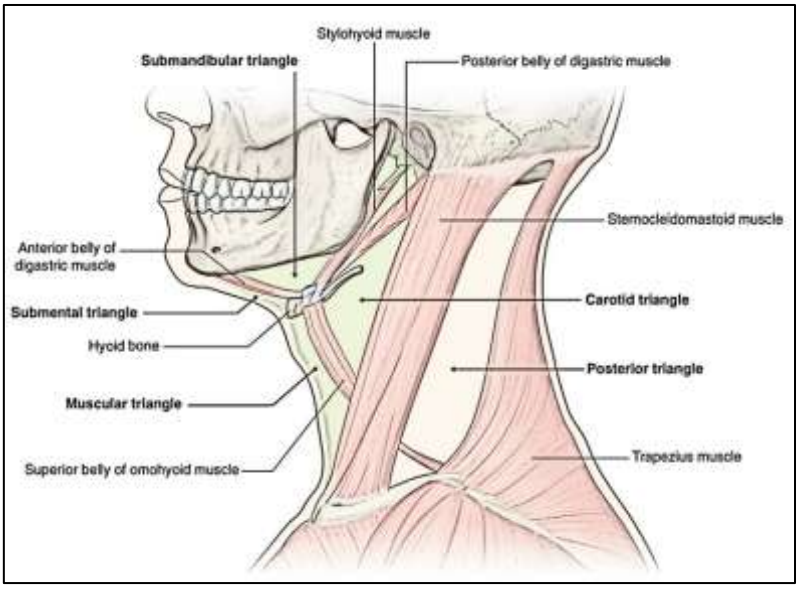

Carotid triangle

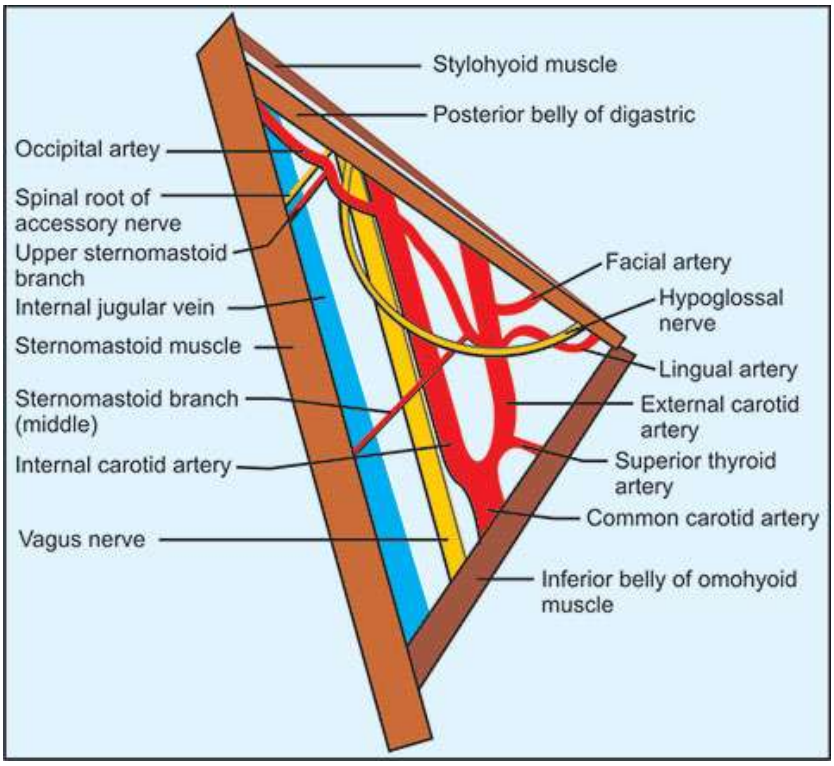

Boundaries:

- Superior: Posterior belly of the digastric muscle.
- Lateral: Medial border of the sternocleidomastoid muscle.
- Inferior Superior belly of the omohyoid muscle.

Contents:

- The main contents of the carotid triangle are the common carotid artery (which bifurcates within the carotid triangle into the external and internal carotid arteries).
- Internal jugular vein
- Hypoglossal
- Vagus nerves.

Submental Triangle

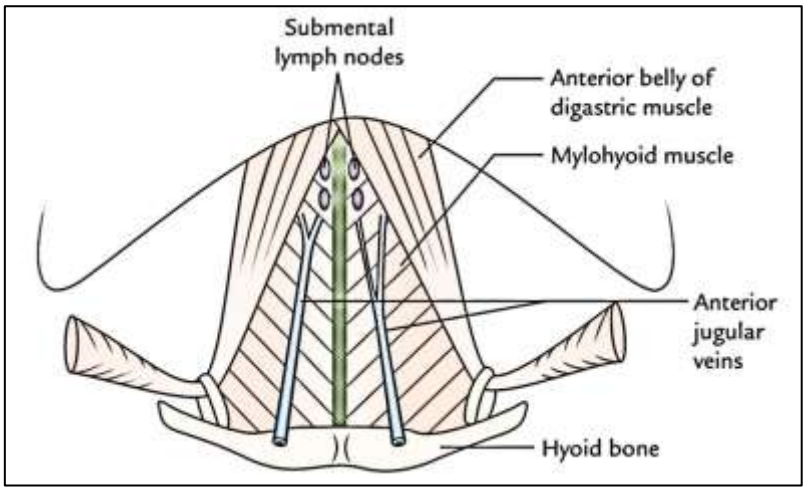

Boundaries:

- Inferiorly - Hyoid bone.
- Medially - Imaginary sagittal midline of the neck.
- Laterally - Anterior belly of the digastric.

Contents:

- Submental lymph nodes, which filter lymph draining from the floor of the mouth and parts of the tongue.
- Anterior jugular veins Floor: Mylohyoid muscle.

Submandibular/ Digastric Triangle

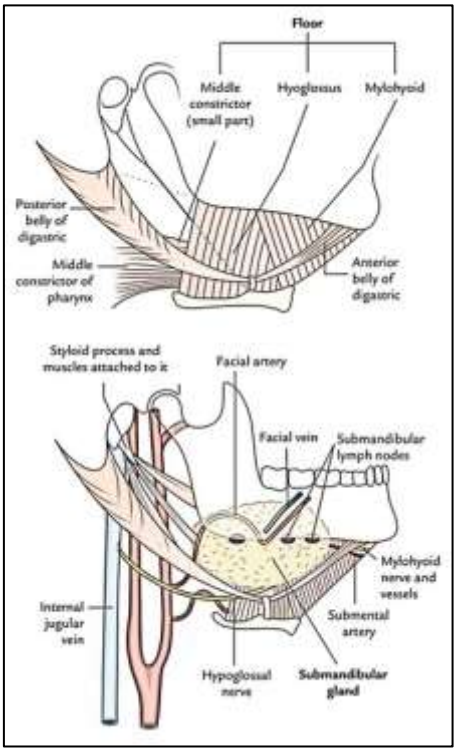

Boundaries:

- Superiorly: Body of the mandible.
- Anteriorly: Anterior belly of the digastric muscle.
- Posteriorly: Posterior belly of the digastric muscle.

Contents:

- Submandibular gland
- Lymph nodes

The **facial artery and vein** also pass through this area.

Muscular Triangle

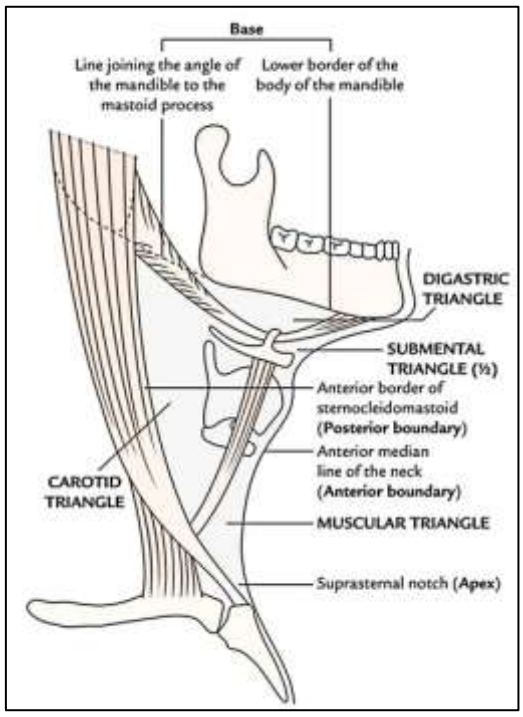

Boundaries:

- Medially: Imaginary midline of the neck.
- Superior - laterally: Superior belly of the omohyoid muscle.
- Inferior - laterally: Inferior portion of the sternocleidomastoid muscle.

Contents:

- Infrahyoid muscles
- Pharynx
- Thyroid and parathyroid glands.

SGD 04 - Cerebral Cortex

(1) A 65-year-old patient presented to the emergency unit with a sudden onset of weakness in the right leg and foot. The patient has been a heavy smoker with poorly controlled high blood pressure, hypercholesterolemia and diabetes mellitus for over 15 years. On examination, muscle power and sensations were reduced in the right lower limb. Upper limbs and the left Lower limb were normal. Radiological investigations revealed thromboembolism of a cerebral artery.

(1.1) State the cerebral artery most likely occluded in this patient. (10 marks)
(1.2) Draw labelled line diagrams to illustrate the arterial supply of the cerebral hemisphere. (40 marks)
(1.3) Explain the anatomical basis of neurological findings in this patient. (50 marks)
(Total = 100 Marks)

(2) A 40 - year - old man had a severe blow to the left side of his head over the temporal region. Several hours later, he developed slurring of speech and weakness of his right upper limb and was admitted to the hospital. CT scan of the brain revealed an extradural (epidural) haematoma.

(2.1) Explain why this patient developed an extradural haematoma. (50 marks)
(2.2) Outline the anatomical basis of "slurring of speech" and "weakness of the right upper limb". (50 marks)
(Total = 100 Marks)

SGD 04 - Cerebral Cortex Answers

(1)

(1.1) State the cerebral artery most likely occluded in this patient.

Left anterior cerebral artery

(1.2) Draw labelled line diagrams to illustrate the arterial supply of the cerebral hemisphere.

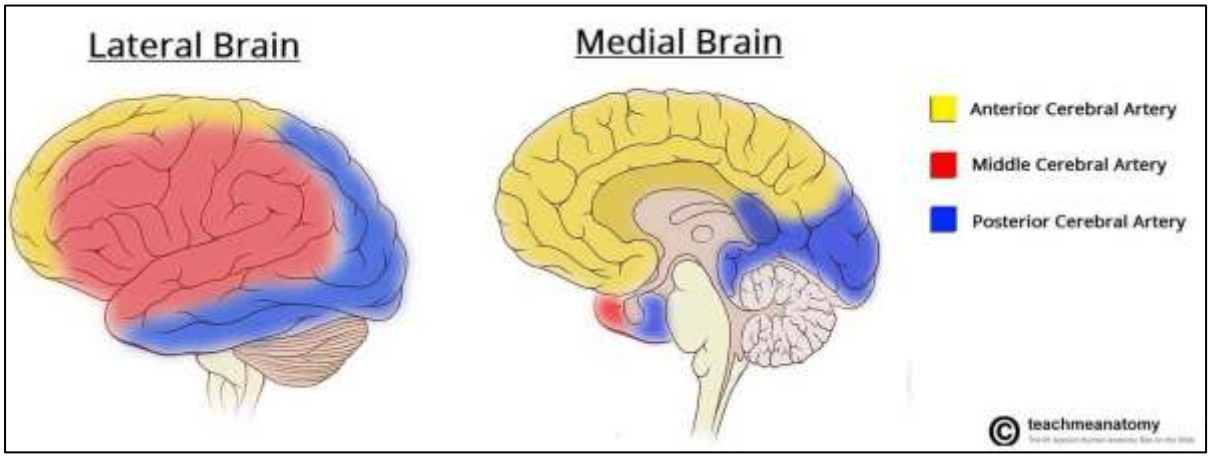

(1.3) Explain the anatomical basis of neurological findings in this patient.

- **Left anterior cerebral artery** supplies the **medial and superior** portions of the **frontal and parietal lobes** as well as the parts of the corpus callosum and cingulate gyrus.
- Occlusion of the artery causes ischaemia of the respective cortical areas, which then leads to a set of neurological deficits due to the ischaemic damage to those functional areas.
- According to the motor and sensory homunculus, **motor and sensory** signals from the **leg and foot** are primarily directed to the area supplied by the anterior cerebral artery.
- **Contralateral weakness** of the lower limb due to ischaemia of the superior and medial parts of the **precentral gyrus.**
- **Contralateral sensory loss** of the lower limb due to ischaemia of the superior and medial parts of the **postcentral gyrus.**
- **Inability to identify objects** correctly, **apathy** (state of reduced motivation, interest and emotional responsiveness), and **personality changes** due to damage to the frontal lobe (prefrontal cortex) and parietal lobes.

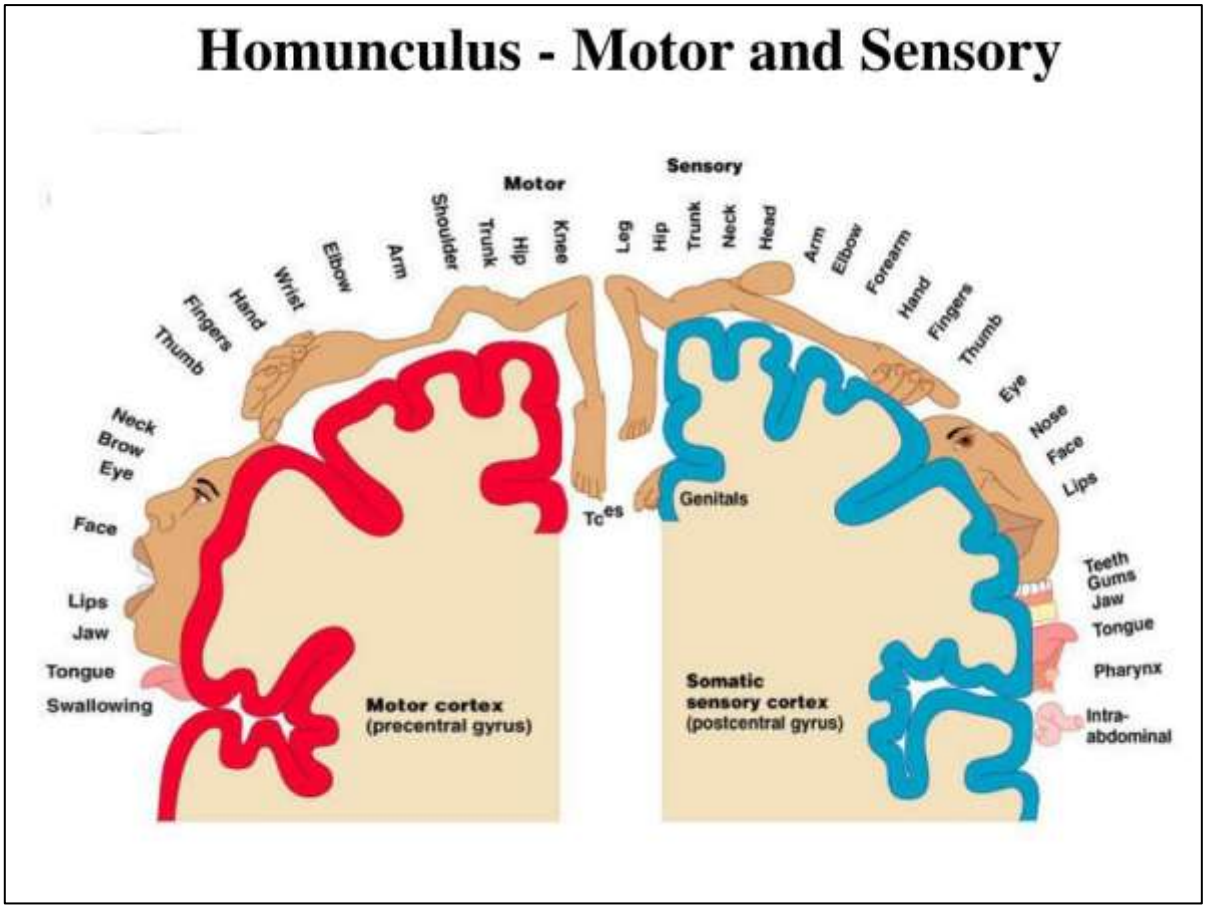
Homunculus - Motor and Sensory
Motor
Sensory
Shoulder
Arm
Elbow
Wrist
Hand
Fingers
Thumb
Trunk
Hip
Knee
Leg
Neck
Brow
Eye
Face
Lips
Jaw
Tongue
Swallowing
Toes
Genitals
Motor cortex
(precentral gyrus)
Somatic
sensory cortex
(postcentral gyrus)
Trunk
Neck
Head
Arm
Elbow
Forearm
Hand
Fingers
Thumb
Eye
Nose
Face
Lips
Teeth
Gums
Jaw
Tongue
Pharynx
Intra-
abdominal

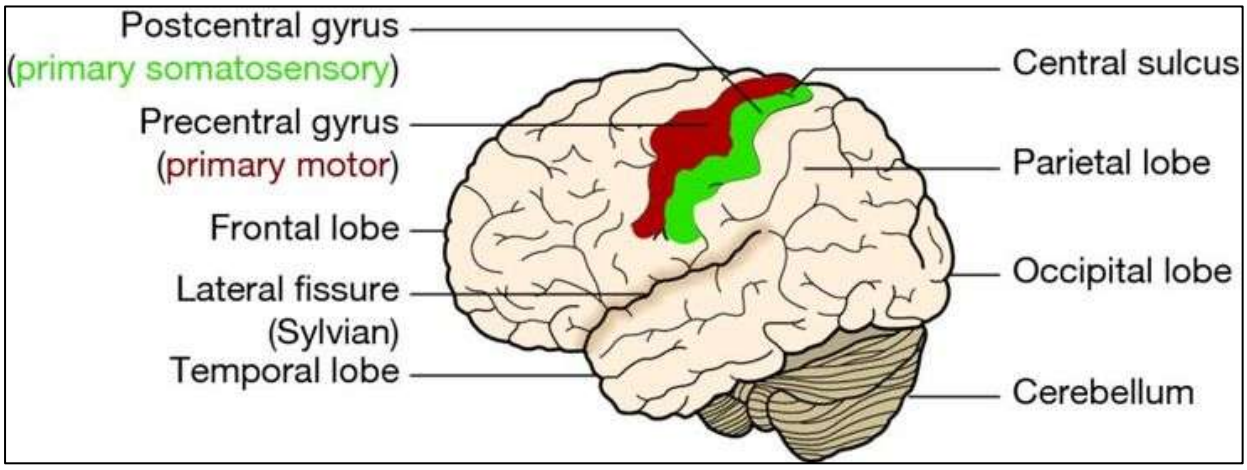
Postcentral gyrus
(primary somatosensory)
Precentral gyrus
(primary motor)
Frontal lobe
Lateral fissure
(Sylvian)
Temporal lobe
Central sulcus
Parietal lobe
Occipital lobe
Cerebellum

(2)

(2.1) Explain why this patient developed an extradural haematoma.

- Extra dural haemorrhage is gradual accumulation of of **blood in the extradural space.**
- This happens due to damage of the **anterior division of the middle meningeal artery and accompanying middle meningeal vein.**
- Middle meningeal artery arises from the **maxillary artery** in the infratemporal fossa.
- It enters to the cranial cavity through **foramen spinosum** and groove the upper surface of the **squamous part of the temporal bone.**
- It divides in to **anterior and posterior branches.**
- **Anterior branch** lies in a groove on the **greater wing of the sphenoid at the pterion.**
- This is the **most common branch that likely to tear during a fracture of the side of the skull involving pterion.**

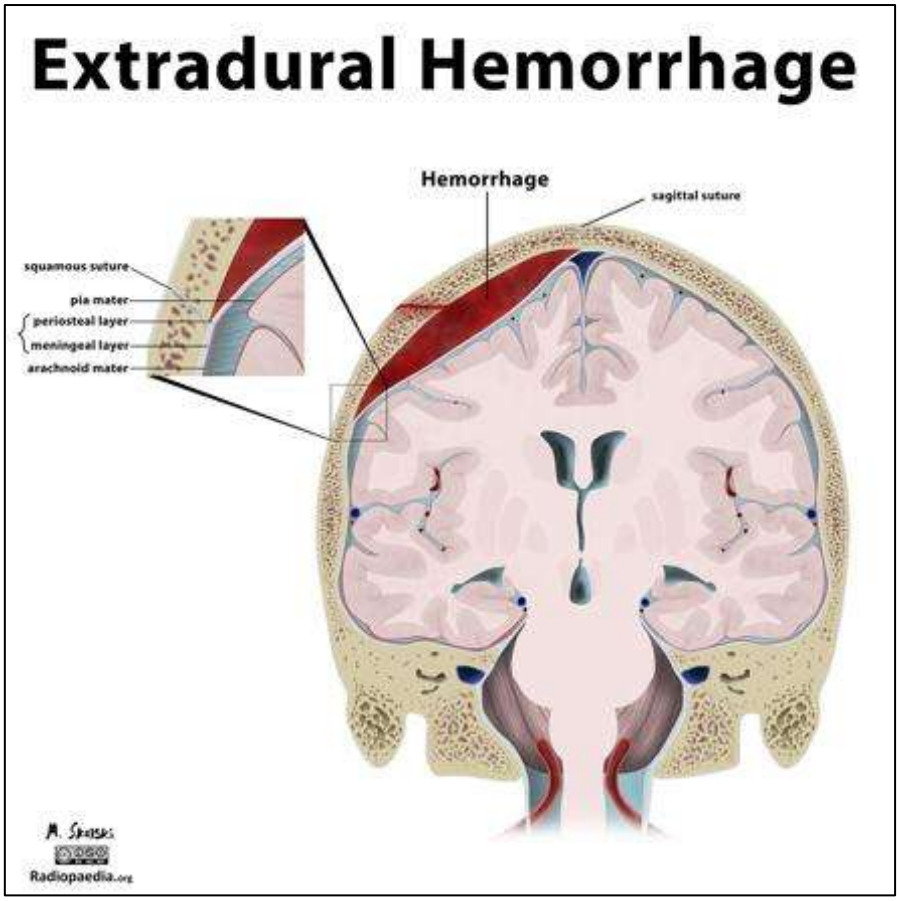

(2.2) Outline the anatomical basis of "slurring of speech" and "weakness of the right upper limb".

- Due to the extradural hemorrhage, there is an accumulation of blood, so the intracranial pressure rises, and the enlarging **blood clot exerts local pressure on the underlying motor area in the precentral gyrus.**
- This is the reason for the weakness of the upper limb **precentral gyrus** (Brodman area 4), which is the area between the central and the precentral sulcus, and it is responsible for **primary motor movements**.
- It produces isolated **movements on the opposite side** of the body.
- The movement area of the body is represented in **inverted form in the precentral gyrus.**
- On the **medial surface** - toes, ankle, leg, genitalia
- On the **lateral surface** from superior to inferior - knee, hip, trunk, arm, elbow, wrist, hand, finger, thumb, neck, face, lip, jaw, tongue
- On **paracentral lobule** - legs and perineum
- Parts involved in **fine, skilled movements** have a **large proportion**.
  Ex÷ hand and thumb
- In this patient, the blow was on the left side of the head at the **temporal region**. There is a lesion on the primary motor cortex of the left hemisphere, specifically in the area **responsible for the movements of the upper limb.**
- So, there is a weakness in the right side, and also the finer and more skilled movements are suffered the most.
- **"Slurring of speech"** can be seen due to a lesion in **Broca's area** (Brodmann area 44 and 45)
- It lies in the **inferior frontal gyrus**.
- Due to the lesion, there is a **loss of ability to produce speech.**
- This is known as **expressive aphasia**. But can think the words they wish to say, can write words and can understand their meaning when they see or hear them.

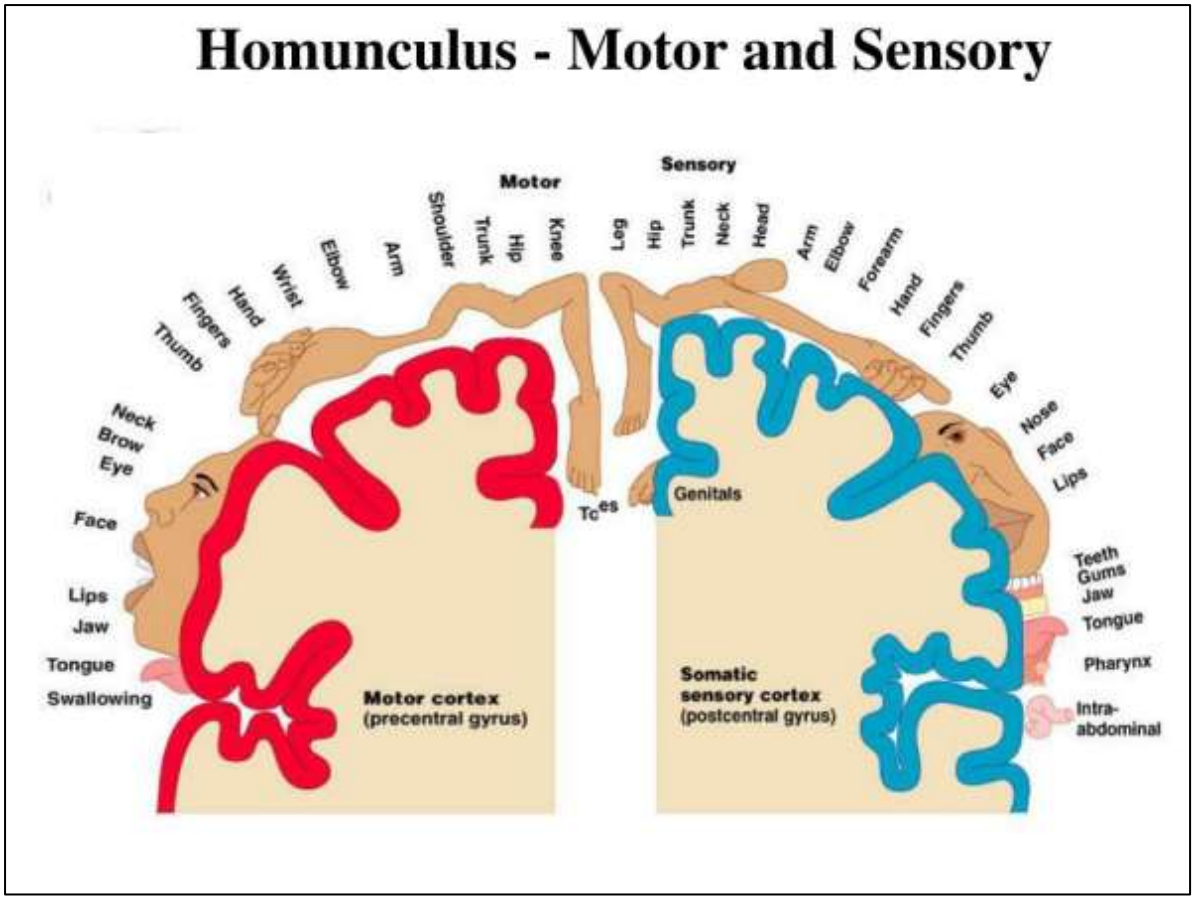
Homunculus - Motor and Sensory
Motor
Sensory
Shoulder
Arm
Elbow
Wrist
Hand
Fingers
Thumb
Trunk
Hip
Knee
Leg
Trunk
Hip
Neck
Head
Arm
Elbow
Forearm
Hand
Fingers
Thumb
Eye
Nose
Face
Lips
Neck
Brow
Eye
Face
Lips
Jaw
Tongue
Swallowing
Toes
Genitals
Teeth
Gums
Jaw
Tongue
Pharynx
Intra-abdominal
Motor cortex
(precentral gyrus)
Somatic
sensory cortex
(postcentral gyrus)

SGD 05 - Basal Ganglia & Cerebellum

(1) A 65-year-old man presents with resting tremor, rigidity, bradykinesia, and a shuffling gait. Clinical examination suggests a disorder involving the basal ganglia.

(1.1) Enumerate the components of the basal ganglia. (20 marks)
(1.2) Describe the anatomical relations of the lentiform nucleus. (20 marks)
(1.3) Describe the functional connections of the basal ganglia. (30 marks)
(1.4) Explain the role of the basal ganglia in the control of voluntary movements. (20 marks)
(1.5) Describe the anatomical basis of the clinical features seen in this patient. (10 marks)

(Total = 100 Marks)

(2) 60-year-old man is brought to a medical clinic with complaints of irregular swaying gait and difficulty keeping balance when standing still. On examination he is ataxic and there is diminished muscle his right upper and lower limbs. When he is asked to quickly pronate and supinate the forearms movements are normal on left side but jerky and slow on the right side. Bilateral papilloedema is observed. CT scan reveals a tumour in posterior cranial fossa compressing the cerebellum.

(2.1) Explain the anatomical basis of papillodema. (20 marks)
(2.2) Which of the above complaints are due to direct involvement of the cerebellum? (20 marks)
(2.3) List lobes and fissures of the cerebellum. (30 marks)
(2.4) Describe the blood supply of the cerebellum. (30 marks)

(Total = 100 Marks)

SGD 05 - Basal Ganglia & Cerebellum Answers

(1)

(1.1) Enumerate the components of the basal ganglia.

The basal ganglia are **large masses of grey matter** situated deep within the cerebral hemispheres.

- Corpus striatum
  - **Caudate nucleus**
  - **Lentiform nucleus**
    - Putamen
    - Globus pallidus
      - Globus Pallidus Internus
      - Globus Pallidus Externus
- Claustrum
- **Subthalamic nucleus**
- **Substantia nigra**
  - Pars Compacta
  - Pars Reticulata

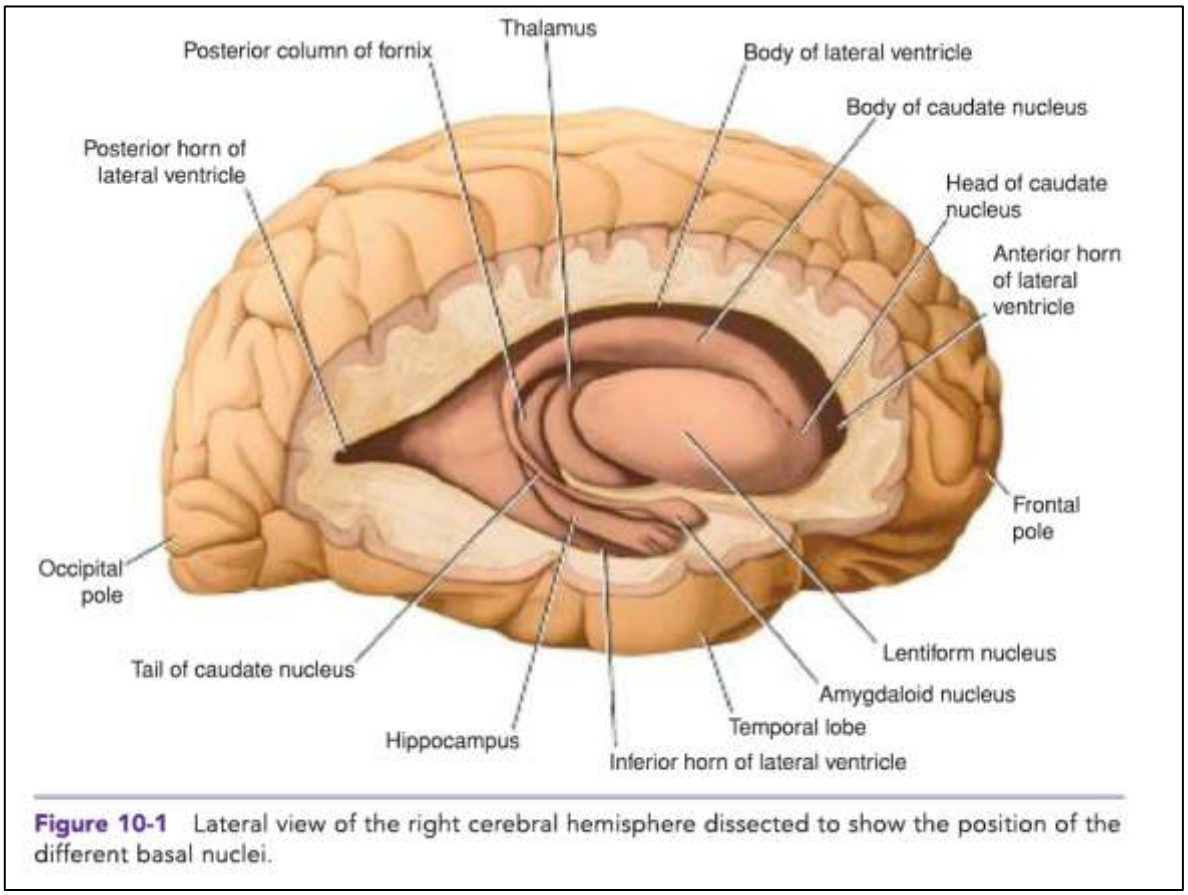

Figure 10-1 Lateral view of the right cerebral hemisphere dissected to show the position of the different basal nuclei.

(1.2) Describe the anatomical relations of the lentiform nucleus.

Wedge-shaped mass of gray matter (broad convex base – laterally, blade – medially).

- Medially → **Internal capsule** (separates it from the caudate nucleus and the thalamus).
- Laterally → **External capsule** (thin sheet of white matter) → Claustrum (thin sheet of gray matter) → Subcortical white matter of the insula.
- Divided by a vertical plate of white matter.

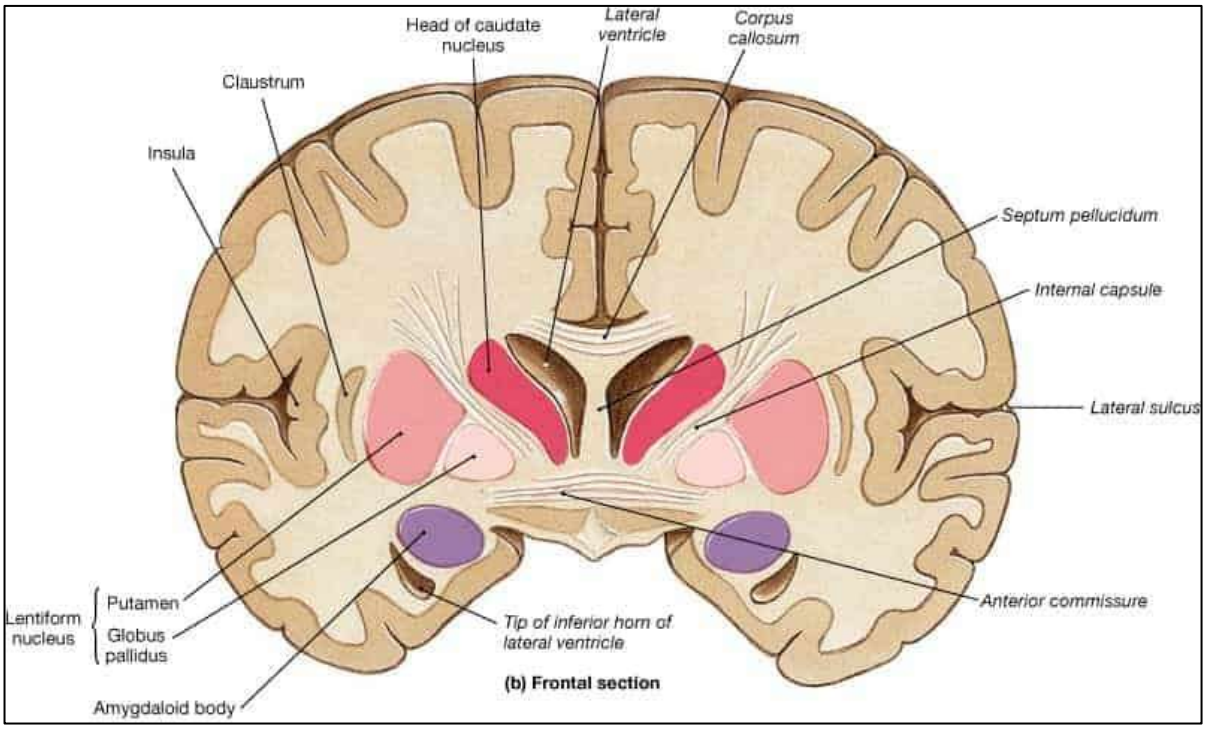

(1.3) Describe the functional connections of the basal ganglia.

The basal ganglia function through **afferent and efferent connections** forming motor circuits.

Afferent Connections

- Cerebral cortex → corticostriate fibres to caudate nucleus and putamen.
- Thalamus → thalamostriate fibres.
- Substantia nigra → nigrostriatal fibres (dopaminergic).
- Subthalamic nucleus.

Efferent Connections

- Striatum → globus pallidus.
- Globus pallidus → thalamus (ventral anterior and ventral lateral nuclei).
- Thalamus → motor cortex.
- Globus pallidus → subthalamic nucleus.
- Substantia nigra → thalamus.

These connections form cortico–striato–pallido–thalamo–cortical loops.

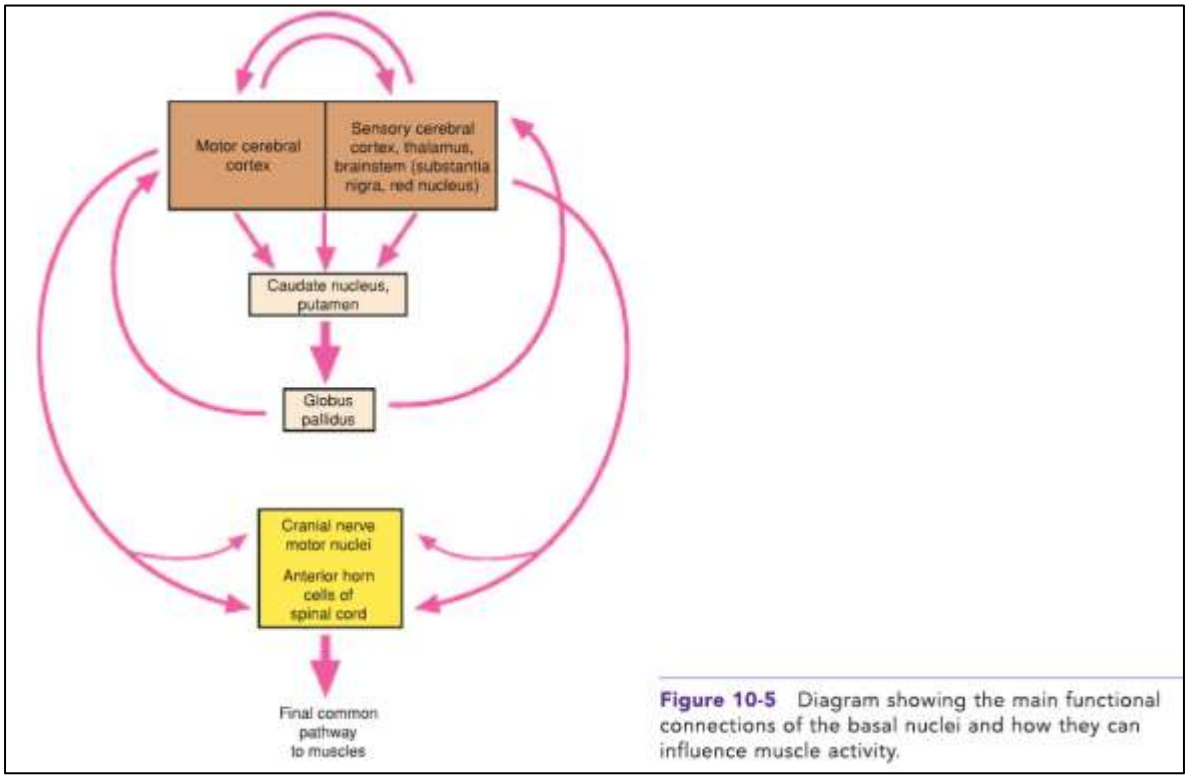

Figure 10-5 Diagram showing the main functional connections of the basal nuclei and how they can influence muscle activity.

(1.4) Explain the role of the basal ganglia in the control of voluntary movements.

Control muscular movements by Influencing the cerebral cortex.

- **Regulation** of voluntary movement
- **Learning** of motor skills.

Important in **preparation** for movements (trunk and limbs to be placed in appropriate positions before the primary motor part of the cerebral cortex activates discrete movements in the hands and feet).

(1.5) The clinical features described (resting tremor, rigidity, bradykinesia) are characteristic of Parkinson's disease.

This is due to the **degeneration of dopaminergic** neurons in the **substantia nigra**. Loss of dopamine leads to **an imbalance between excitatory and inhibitory pathways** in the basal ganglia, resulting in:

- Increased muscle tone (rigidity)
- Slowness of movement (bradykinesia)
- Resting tremor
- Shuffling gait

Thus, basal ganglia lesions produce **extrapyramidal symptoms** rather than paralysis

(2)

(2.1) Explain the anatomical basis of papillodema.

- A tumour in posterior cranial fossa compresses the cerebellum.
- Then, immediately anterior to the cerebellum is the 4th ventricle.
- Due to the tumour, pressure of the 4th ventricle rises.
- That causes more CSF to drain into subarachnoid space.
- Now there is an increased intracranial pressure.
- Subarachnoid space is continuing to eyeball via optic nerves.
- This causes bulging of the optic disc resulting papilloedema.

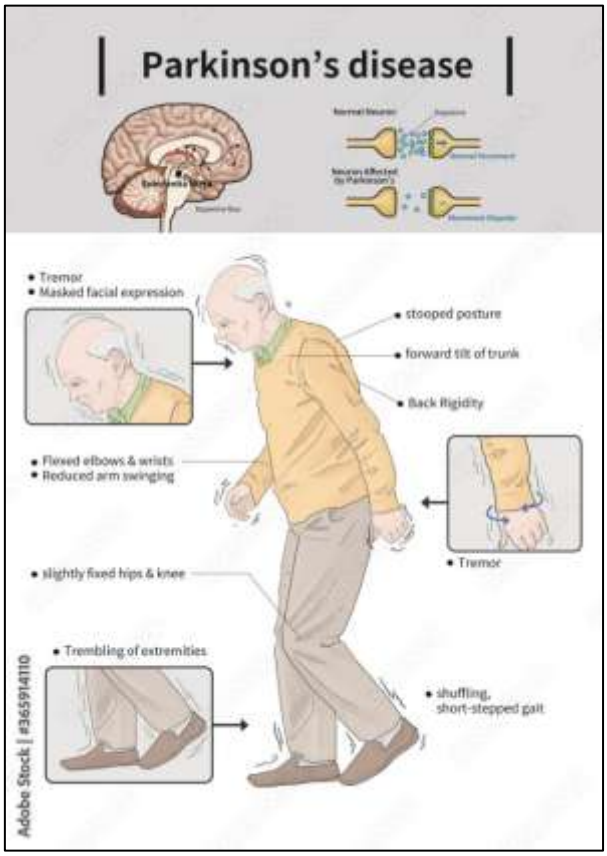

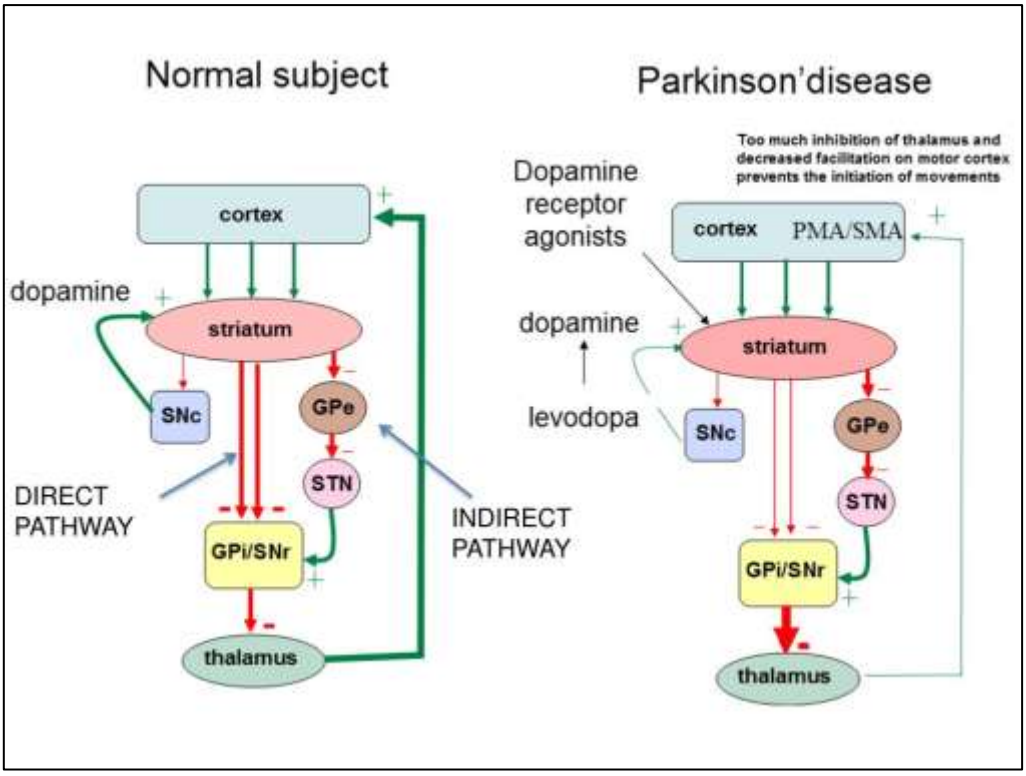
Normal subject
Parkinson'disease
Too much inhibition of thalamus and decreased facilitation on motor cortex prevents the initiation of movements
cortex
dopamine
striatum
SNc
GPe
STN
GPi/SNr
thalamus
DIRECT PATHWAY
INDIRECT PATHWAY
Dopamine receptor agonists
cortex
PMA/SMA
dopamine
striatum
levodopa
SNc
GPe
STN
GPi/SNr
thalamus

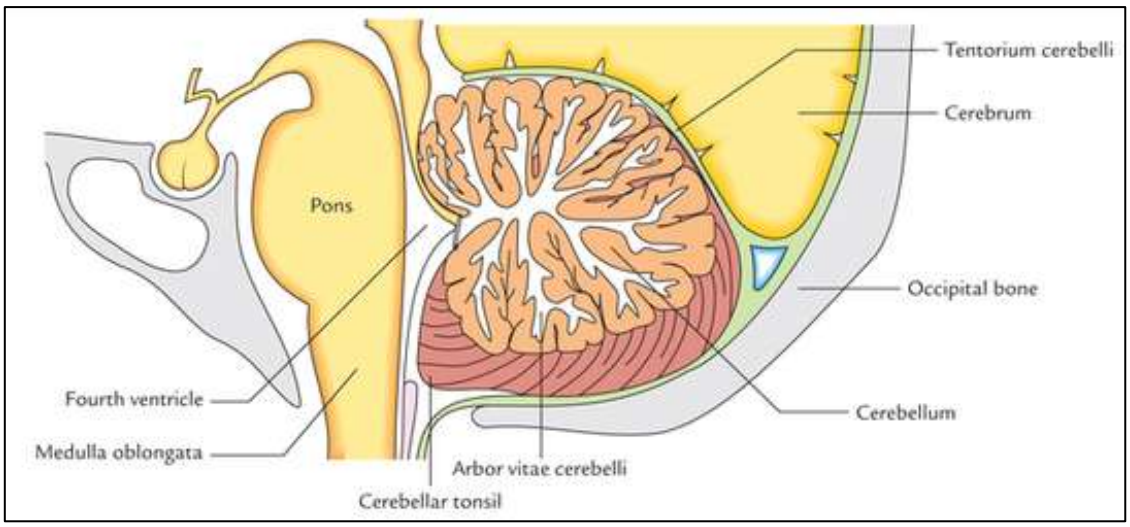
Tentorium cerebelli
Cerebrum
Pons
Occipital bone
Fourth ventricle
Cerebellum
Medulla oblongata
Arbor vitae cerebelli
Cerebellar tonsil

(2.2) Which of the above complaints are due to direct involvement of the cerebellum?

- Ataxia
- Jerky and slow movements in right side
- Irregular swaying gait
- Difficulty keeping balance

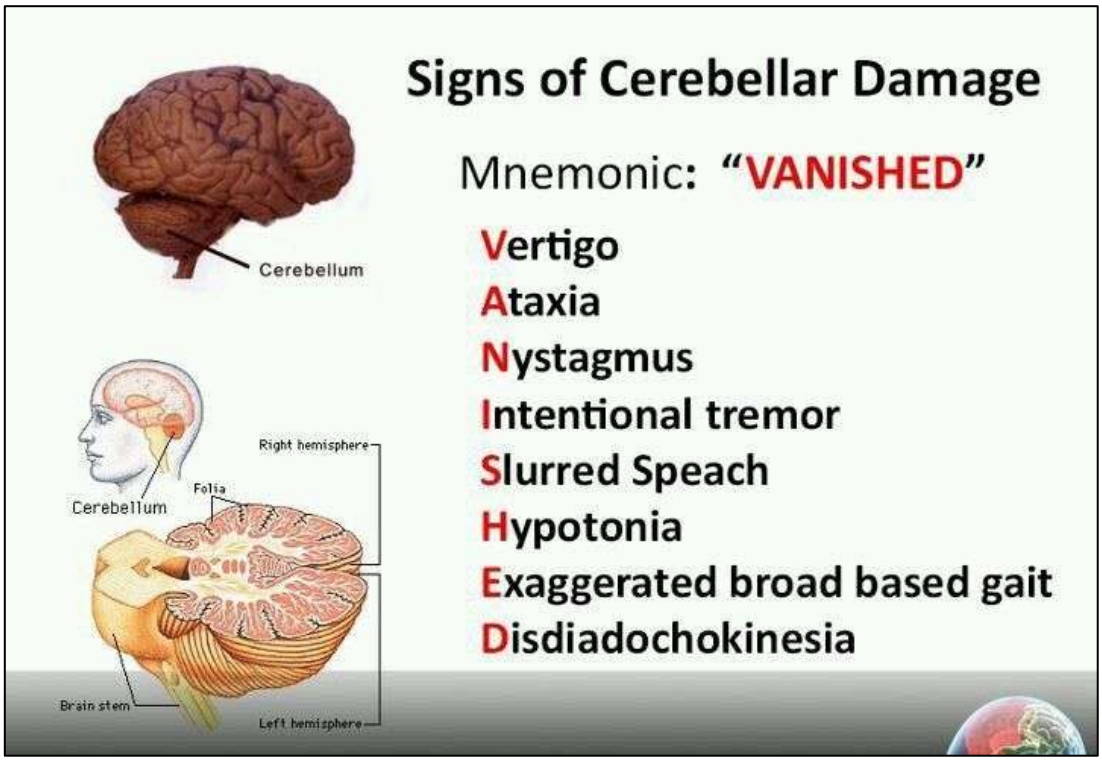

(2.3) List lobes and fissures of the cerebellum.

There are **3 lobes.**

1. Anterior lobe
2. Posterior lobe
3. Flocculonodular lobe

Anterior lobe is separated from the posterior lobe by V shape fissure called **primary fissure.**
Flocculonodular lobe is separated from the posterior lobe by **uvulonodular fissure.**

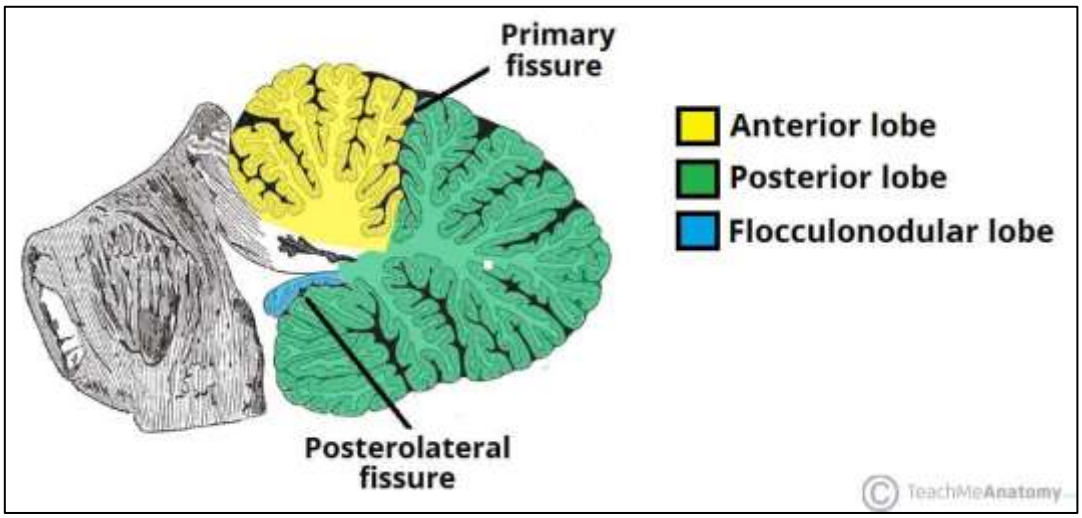
Primary fissure
Anterior lobe
Posterior lobe
Flocculonodular lobe
Posterolateral fissure
TeachMeAnatomy

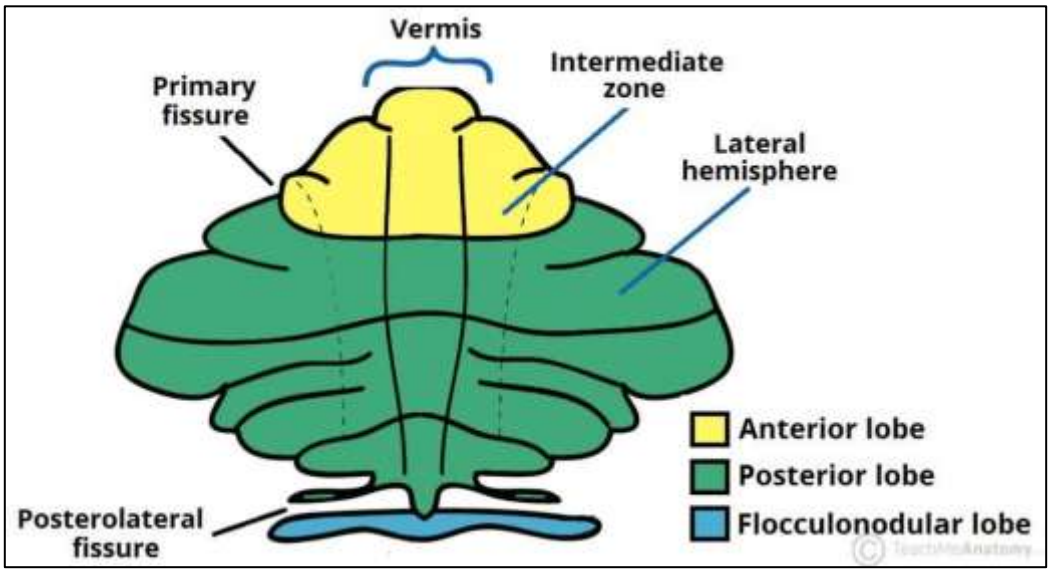
Vermis
Intermediate zone
Primary fissure
Lateral hemisphere
Anterior lobe
Posterior lobe
Flocculonodular lobe
Posterolateral fissure

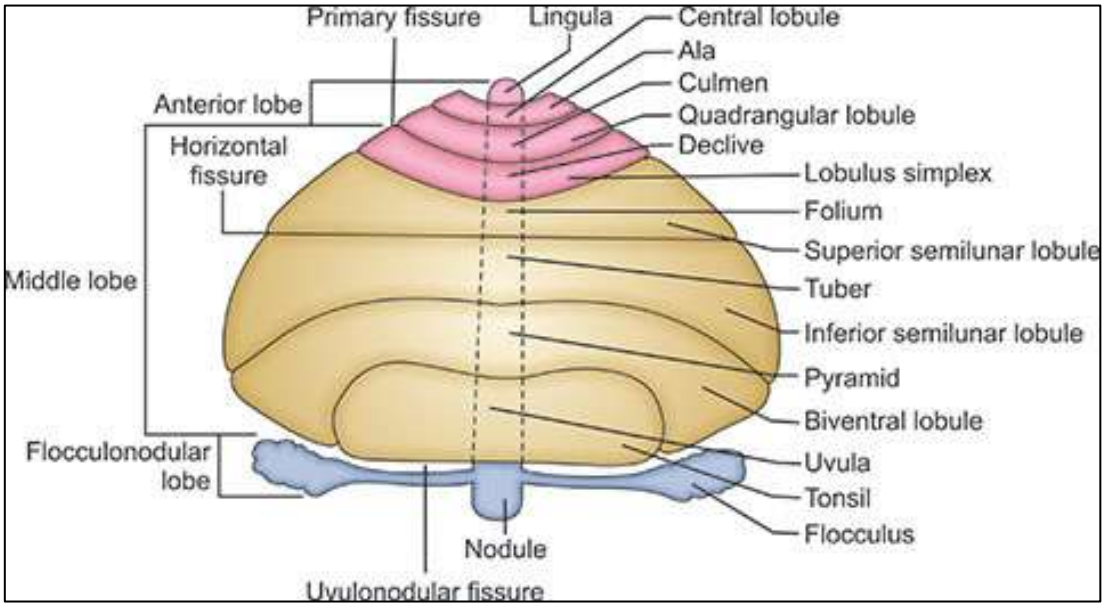
Primary fissure
Lingula
Central lobule
Ala
Culmen
Quadrangular lobule
Declive
Anterior lobe
Horizontal fissure
Lobulus simplex
Folium
Superior semilunar lobule
Middle lobe
Tuber
Inferior semilunar lobule
Pyramid
Biventral lobule
Flocculonodular lobe
Uvula
Tonsil
Flocculus
Nodule
Uvulonodular fissure

(2.4) Describe the blood supply of the cerebellum.

- **Superior cerebellar artery** from the Basilar artery supplies the **superior part.**
- **Anterior Inferior Cerebellar Artery** from the Basilar artery supplies the **anteroinferior part.**
- **Posterior Inferior Cerebellar Artery** supplies the **inferior surface of the vermis, central nuclei of cerebellum and the undersurface of the cerebellar hemispheres.**

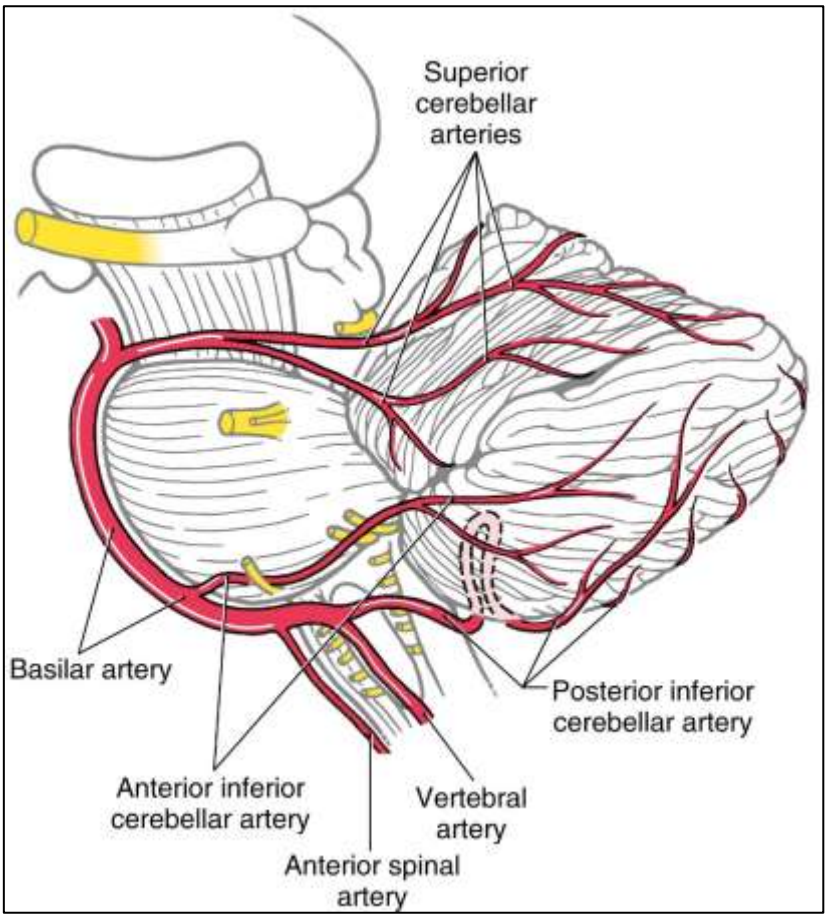

SGD 06 - Applied Anatomy of CNS

(1) Explain the anatomical basis of the following scenario;

A 40-year-old male who underwent parotid gland surgery for a tumor, developed drooping of the right corner of mouth, inability to close the right eye. On examination patient has lost wrinkling on right side of the forehead but had intact taste sensation of the tongue. (100 marks)

SGD 06 - Applied Anatomy of CNS Answers

(1) Explain the anatomical basis of the following scenario;

- Drooping corner of the mouth, inability to close the ipsilateral eye with loss of wrinkling of the forehead is suggestive of a **lower motor type facial nerve palsy**.
- During its course facial nerve travels through the parotid gland, which makes it vulnerable to be damaged during parotid gland surgeries.

- Facial nerve; the 7th cranial nerve, **emerges from** the brain stem at the **ponto-medullary junction as two divisions;** Primary root and the nervus intermedius.
- The larger **primary root** (facial nerve proper) innervates the muscles of **facial expression**
- The smaller **intermediate nerve** carries fibers for **taste sensation** of anterior 2/3 of tongue, **parasympathetic secretomotor fibres** to the sublingual and submandibular salivary Glands, the lacrimal gland and nasal mucosa.
- It also carry somatic sensory fibres supply a small area of the skin of the concha of the auricle.
- Next these two roots **enter the internal acoustic meatus** along with the 8th nerve and run laterally in the petrous temporal bone within which they fuse to form a single nerve trunk.
- Close to the middle ear nerve takes a sharp posterior bend and runs in the medial wall of the middle ear.
- At the bend, there is the geniculum, which is enlarged by the cell bodies of the afferent (taste) fibres to form the **geniculate ganglion**.
- Then the nerve curves downwards behind the middle ear and runs vertically downwards in the **facial canal**
- It gives off afferent fibers carrying taste sensation to anterior 2/3 of tongue via the **chorda tympani nerve.**
- Then the nerve proper emerges from the **stylomastoid foramen** as a purely motor nerve and then passes **through the parotid gland**.
- Within the parotid gland nerve divides into **five groups of branches** for the facial muscles and platysma.
- These are **Temporal, Zygomatic, Buccal, Marginal mandibular and cervical branches**.

- If the damage to the facial nerve occurs **within the parotid gland, ipsilateral muscles of facial expression** will be paralyzed.
- As the lesion occurs below the level of motor nerve nucleus (infranuclear), it gives rise to a **lower motor type facial paralysis.**
- Therefore, **both upper and lower quadrants of the the face** will be affected.
- **Paralysis of occipitofrontalis** leads to **inability of wrinkling** the ipsilateral forehead and inability to elevate the eyebrow.

- **Orbicularis oculi** is responsible for closing the eyelids, paralysis of this would cause **inability to close eyes tightly**.
- **Levator labii superioris and zygomaticus muscles** dilate the mouth and elevate the labial commissures to show a happy facial expression.
- When these muscles are paralyzed, **corner of the mouth droops downwards and the smile will become asymmetrical.**
- As corda tympani nerve is given before the nerve entering the parotid gland, **taste sensation of the tongue will be preserved.**
- Functioning muscles in the normal side will drag and **deviate the mouth to the normal side.**
- There will be **loss of nasolabial folds in the affected side**

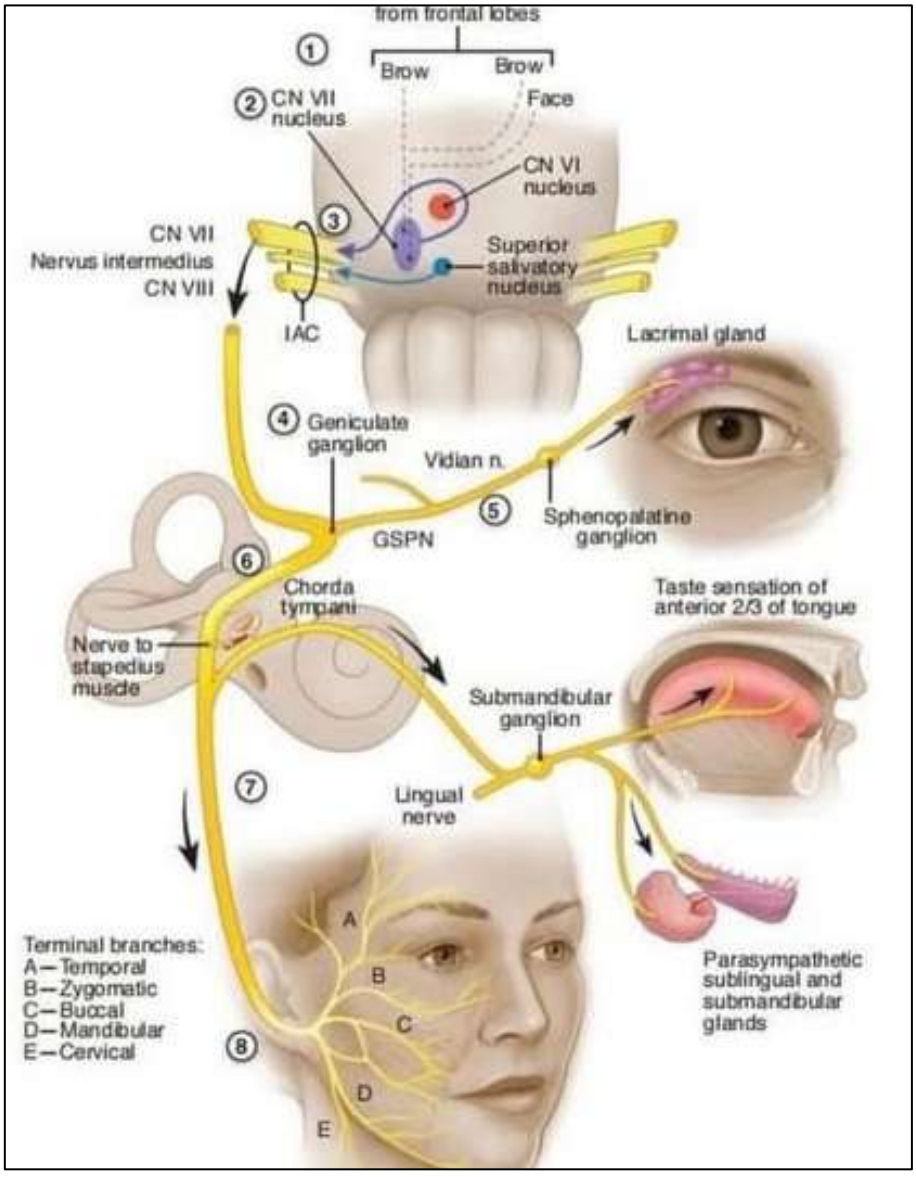

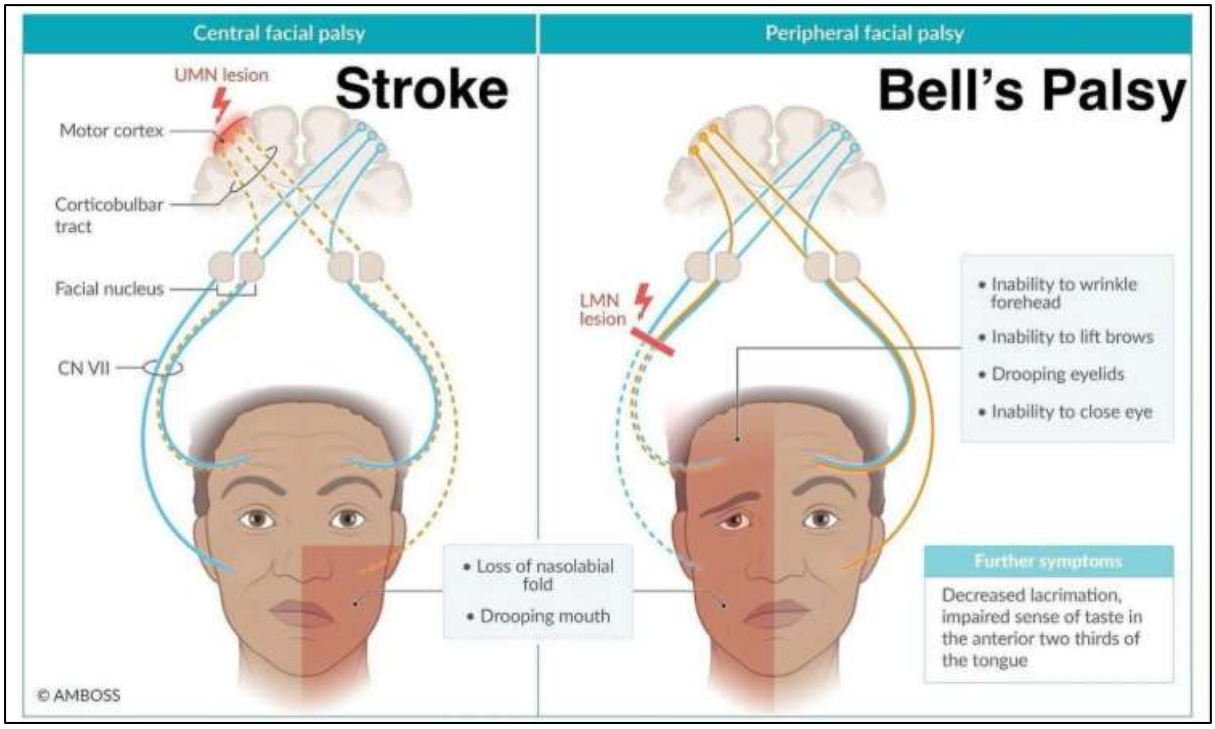
Central facial palsy
Peripheral facial palsy
Stroke
Bell's Palsy
UMN lesion
Motor cortex
Corticobulbar tract
Facial nucleus
CN VII
LMN lesion
• Inability to wrinkle forehead
• Inability to lift brows
• Drooping eyelids
• Inability to close eye
• Loss of nasolabial fold
• Drooping mouth
Further symptoms
Decreased lacrimation, impaired sense of taste in the anterior two thirds of the tongue
© AMBOSS

SGD 07 - Anatomy of Knee and Popliteal Fossa

(1)

(1.1) Describe the factors that maintain the stability of the knee joint (60 marks)

(1.2) Damage to the medial meniscus is more common than damage to the lateral meniscus of the knee joint. (40 marks)

(Total = 100 Marks)

(2) A 30-year-old male was admitted to the surgical ward with a swelling in the left popliteal fossa. Following clinical examination and investigations, the swelling was diagnosed as a malignant tumor arising from the lower end of the left femur.

(2.1) Describe the anatomy of the popliteal fossa. (60 Marks)

(2.2) What are the other abnormal swellings you may find in the popliteal fossa? (40 marks)

(Total = 100 Marks)

SGD 07 - Anatomy of Knee and Popliteal Fossa Answers

(1)

(1.1) Describe the factors that maintain the stability of the knee joint.

- The knee joint is the **largest joint** in the body and is **synovial**.
- It is a **compound joint** composed of **two joints.**
  1. Between the femur and Tibia – hinge joint
  2. Between patella and femur – saddle joint

- This joint is at the intersection of thigh and leg and is **stabilized by many factors**.
  a) **Bony factors** – Do not contribute much but the meniscus lying between the articular surfaces makes them fit well.
  b) **Muscle factors** – Anteriorly- Quadriceps tendon, Posteriorly- popliteus, plantaris, gastrocnemius, biceps femoris
  c) **Ligament factors**
    - Extracapsular: outside the capsule
      1. Tibial collateral ligament – medial
      2. Fibular collateral ligament – lateral
      3. Patella ligament – anterior
      4. Oblique and arcuate popliteal ligaments – posterior

    - Intracapsular (but not intrasynovial)
      1. Anterior cruciate – prevents anterior displacement of the tibia
      2. Posterior cruciate – prevents posterior displacement of the tibia
      3. Transverse ligament
      4. Anterior and posterior meniscofemoral ligaments

- Factors strengthening the capsule also contribute to the stability of the knee joint.
- The **capsule** of the knee joint attaches a little beyond the margin of the articular surface of the tibia and femur and is attached to the sides of the patella.

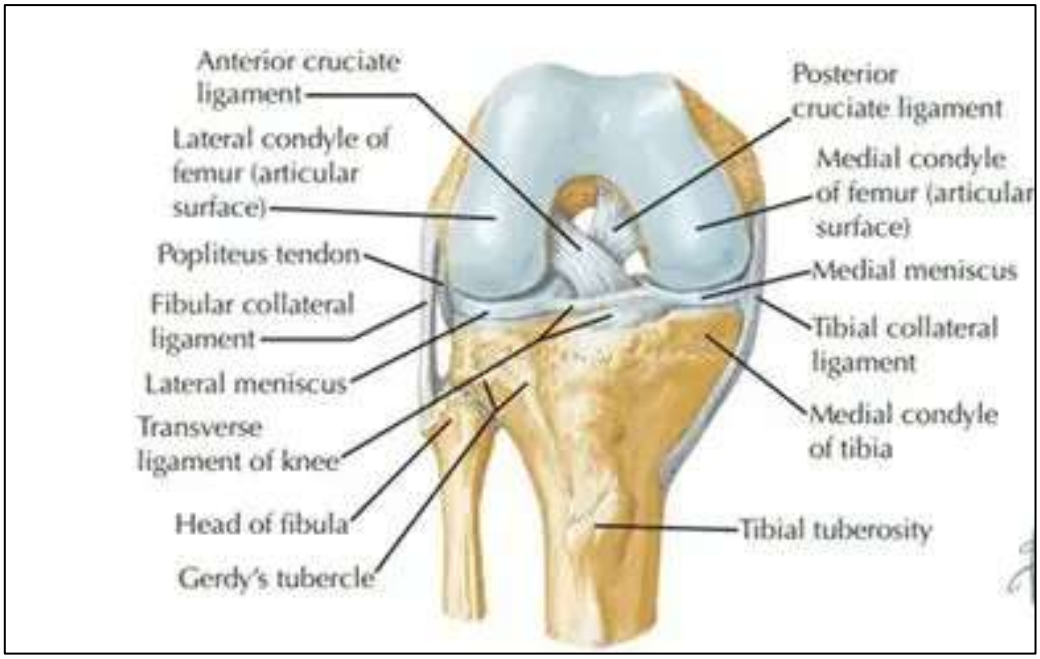

(1.2) Damage to the medial meniscus is more common than damage to the lateral meniscus of the knee joint.

- The knee joint is stabilized by **2 menisci,**
  - which are fibrocartilage discs that act as shock absorbers,
  - cushioning the knee joint between the 2 condyles of the inferior surface of the femur and the tibial plateau.
- The **medial meniscus** is **more elongated** than the lateral meniscus (more oval shaped).
- It attaches to the **intercondylar eminence of the tibia.**
- The **lateral meniscus** is **shorter and thicker** as well as being more circular shaped.
- The **medial meniscus is attached to the capsule** of the knee joint unlike the lateral meniscus.
- **Lateral meniscus** bears **no connection to the knee joint capsule.**
- These semilunar cartilages can only tear when the knee is flexed and able to rotate.
- If the **flexed knee is forcibly abducted and laterally rotated,** the **medial meniscus** may be drawn between the medial condyles of the femur and tibia and be wedged between them.
- Then it **prevents full extension of the knee.**
- Also, in **any injury to the knee joint capsule,** the **medial meniscus is highly prone** to damage.
- A **severe adduction along with internal rotation** is required to tear the **lateral meniscus.**
- Therefore, this injury is **less common.**

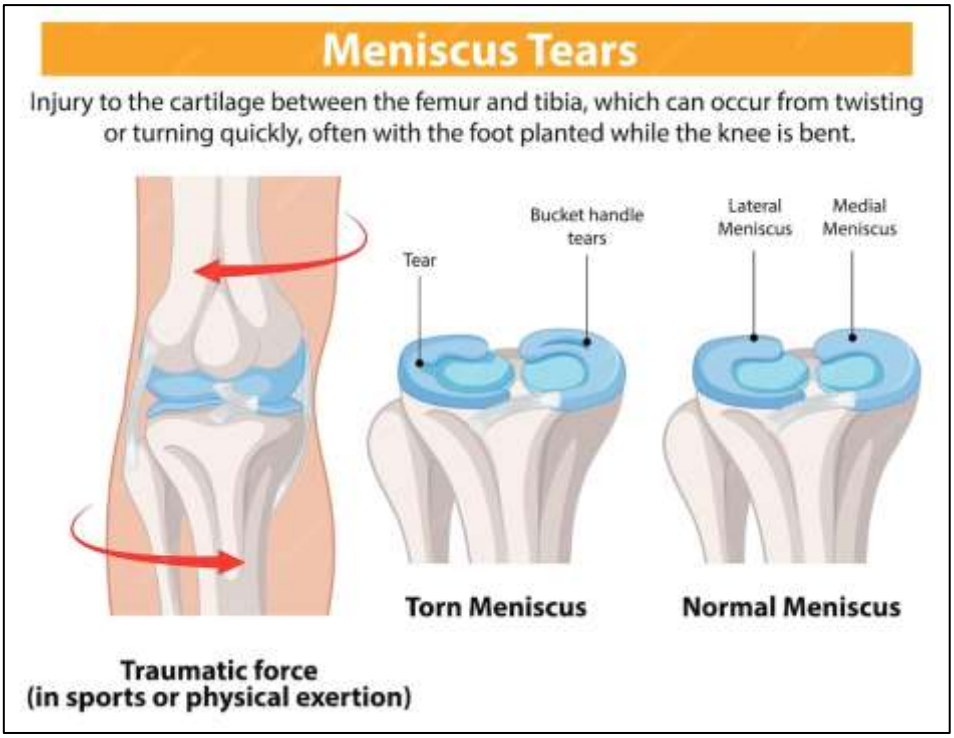

(2.1) Describe the anatomy of the popliteal fossa.

- A diamond-shaped intermuscular space located posterior to the knee joint.
- Boundaries
    - **Superolateral:** Biceps femoris
    - **Superomedial:** Semimembranosus and semitendinosus
    - **Inferolateral:** Lateral head of gastrocnemius ± plantaris
    - **Inferomedial:** Medial head of gastrocnemius

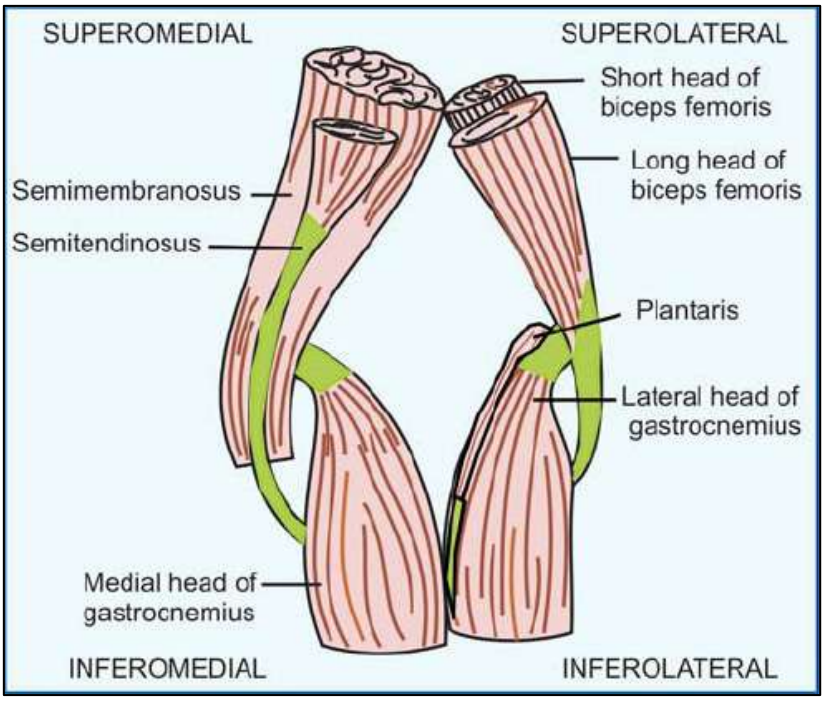

- Roof
  - Skin
  - Superficial fascia (contains small saphenous vein, posterior cutaneous nerve of thigh)
  - Deep fascia (popliteal fascia)
- Floor
  - Popliteal surface of femur
  - Posterior capsule of knee joint
  - Oblique popliteal ligament
  - Fascia over popliteus muscle

- Contents (superficial → deep)
  - Tibial nerve
  - Popliteal vein
  - Popliteal artery

- Other contents:
  - Common peroneal (fibular) nerve (runs along lateral boundary)
  - Popliteal lymph nodes
  - Fat

- Relations
  - Tibial nerve is the most superficial structure.
  - Popliteal artery is the deepest and lies closest to the femur.
  - Vein lies between nerve and artery.

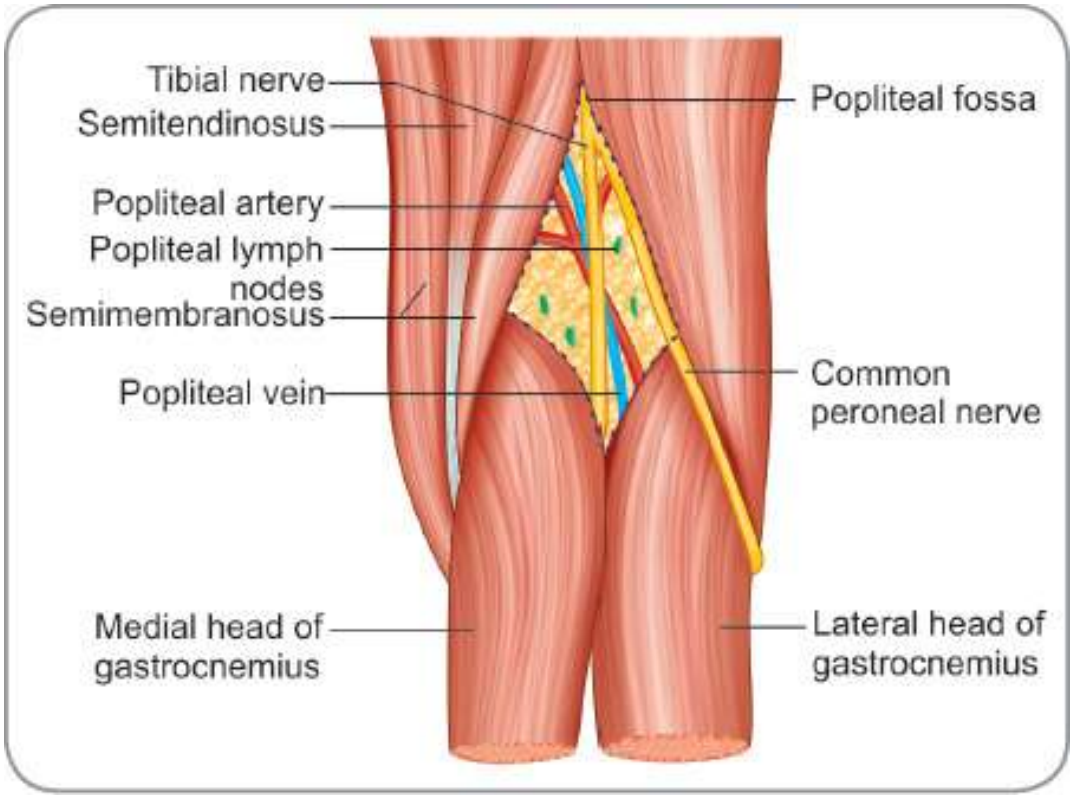

(2.2) What are the other abnormal swellings you may find in the popliteal fossa?

- Skin and soft tissues - sebaceous cyst, Baker's cyst, Abscess, lipoma, a malignant tumor of non - epithelial tissue/ Soft tissue tumors (benign or malignant)
- Vein - varicosities of short saphenous vein
- Artery - popliteal aneurysm, Hematoma (post-trauma)
- Lymph nodes - infection secondary to suppuration of foot.

SGD 08 - Calf & Ankle Joint

(1)

(1.1) Draw a labeled line diagram of a transverse section of the left leg at the level of the mid-calf to illustrate its compartments. Mark the position of vessels and nerves that belong to each of the compartments. (50 marks)

(1.2) List the muscles that belong to each of the compartments mentioned in 1.1 indicating their nerve supply. (50 marks)

(Total = 100 Marks)

(2) Describe the anatomy of the ankle joint. (100 marks)

SGD 08 - Calf & Ankle Joint Answers

(1)

(1.1) Draw a labeled line diagram of a transverse section of the left leg at the level of the mid-calf to illustrate its compartments.

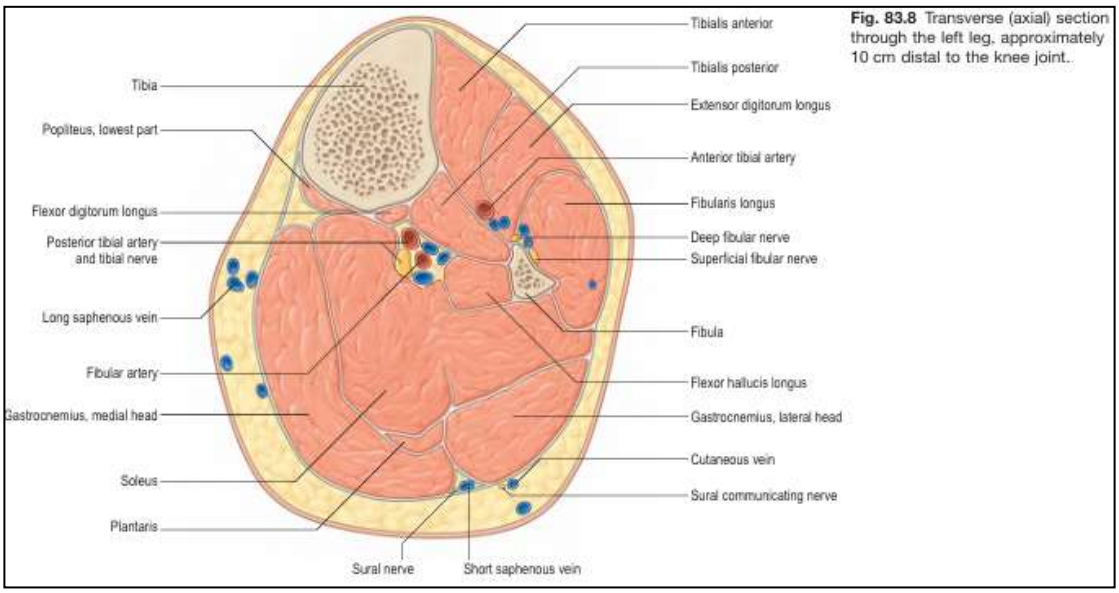

Fig. 83.8 Transverse (axial) section through the left leg, approximately 10 cm distal to the knee joint..

(1.2) List the muscles that belong to each of the compartments mentioned in 1.1 indicating their nerve supply.

- **Anterior compartment** - Deep peroneal nerve

  Tibialis anterior
  Extensor digitorum longus
  Extensor hallucis longus
  Fibularis tertius

- **Lateral compartment** - Superficial peroneal nerve

  Fibularis longus
  Fibularis brevis

- **Posterior compartment** - Tibial nerve

  1. **Superficial muscles**
     Gastrocnemius
     Plantaris
     Soleus
  2. **Deep muscles**
     Tibialis posterior
     Flexor digitorum longus
     Flexor hallucis longus
     Popliteus

(2) Describe the anatomy of the ankle joint.

The ankle joint is a **synovial hinge joint** formed between the distal ends of the tibia and fibula and the talus.

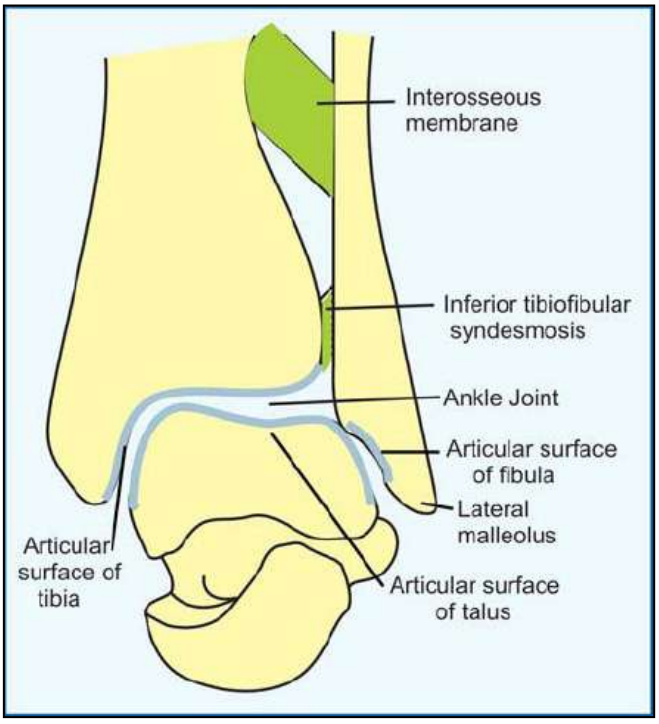

Articular surfaces

The joint is formed by:

- Lower end of tibia
- Lateral malleolus & medial malleolus
- Body of talus

The tibia and fibula form a mortise into which the talus fits.

Joint capsule

The capsule is:

- Thin and weak anteriorly and posteriorly.
- Strongly reinforced on the sides by collateral ligaments.

Ligaments

1. Medial (Deltoid) collateral ligament

- Strong, **triangular** ligament.
- Extends from the tip of the medial malleolus to:
  - Medial tuberosity of Talus
  - Calcaneus
  - Tuberosity of the Navicular
  - Spring ligament
- Prevents **over-eversion.**

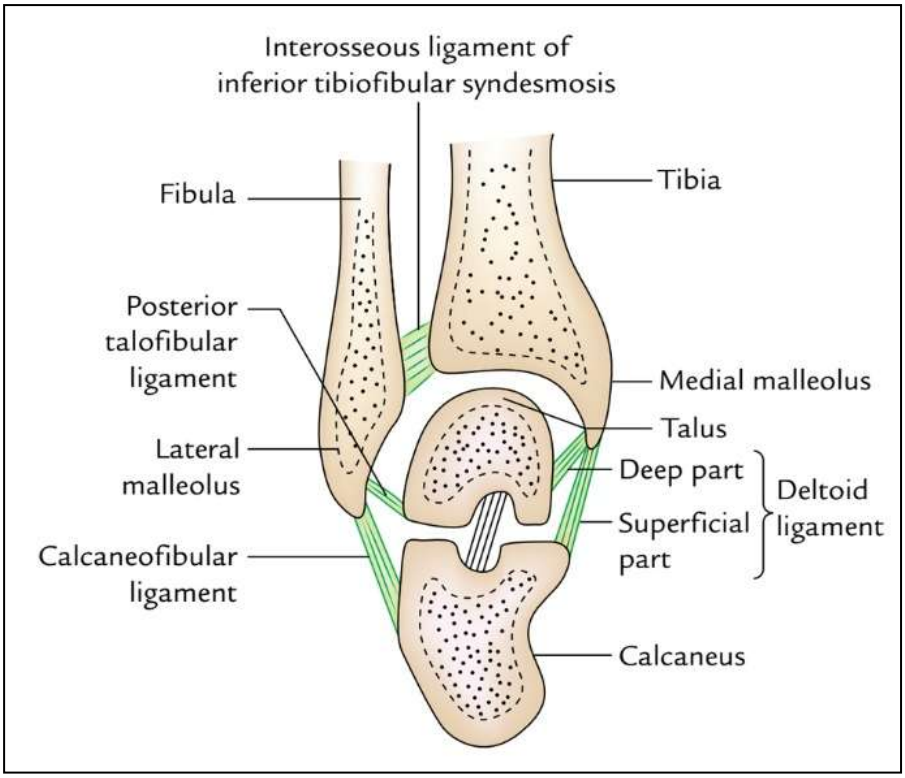

2. Lateral collateral ligament

- Comparatively weak. Has **three bands**.
- These bands radiate from the fibular malleolus and,
  - Anterior talofibular ligament – runs forwards to the neck of the talus.
  - Calcaneofibular ligament – passes downwards and backwards to the calcaneus.
  - Posterior talofibular ligament – passes backwards to the talus.

- Prevents **excessive inversion.**

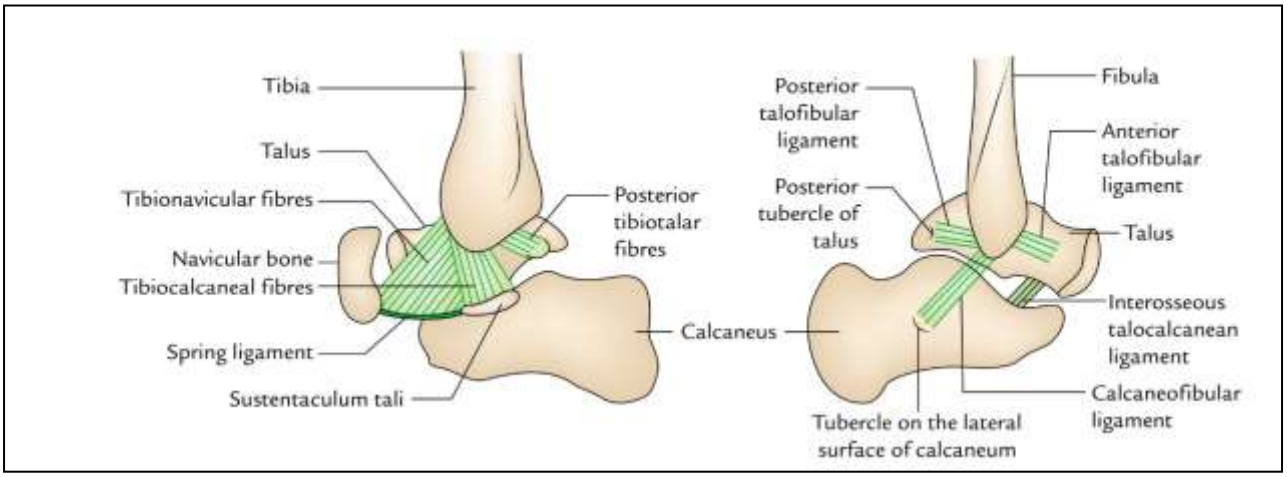

Movements and muscles

Dorsiflexion

- Tibialis anterior
- Extensor hallucis longus
- Extensor digitorum longus

Plantarflexion

- Gastrocnemius
- Soleus
- Tibialis posterior
- Flexor hallucis longus
- Flexor digitorum longus

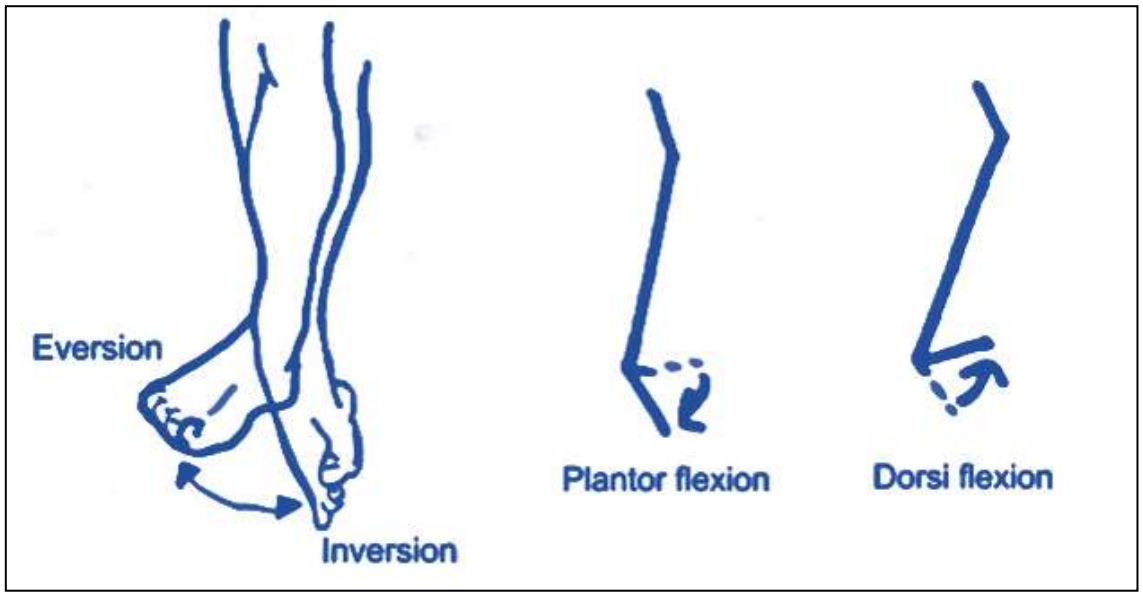

Blood supply

- Branches of:
  - Anterior tibial artery
  - Posterior tibial artery
  - Fibular artery

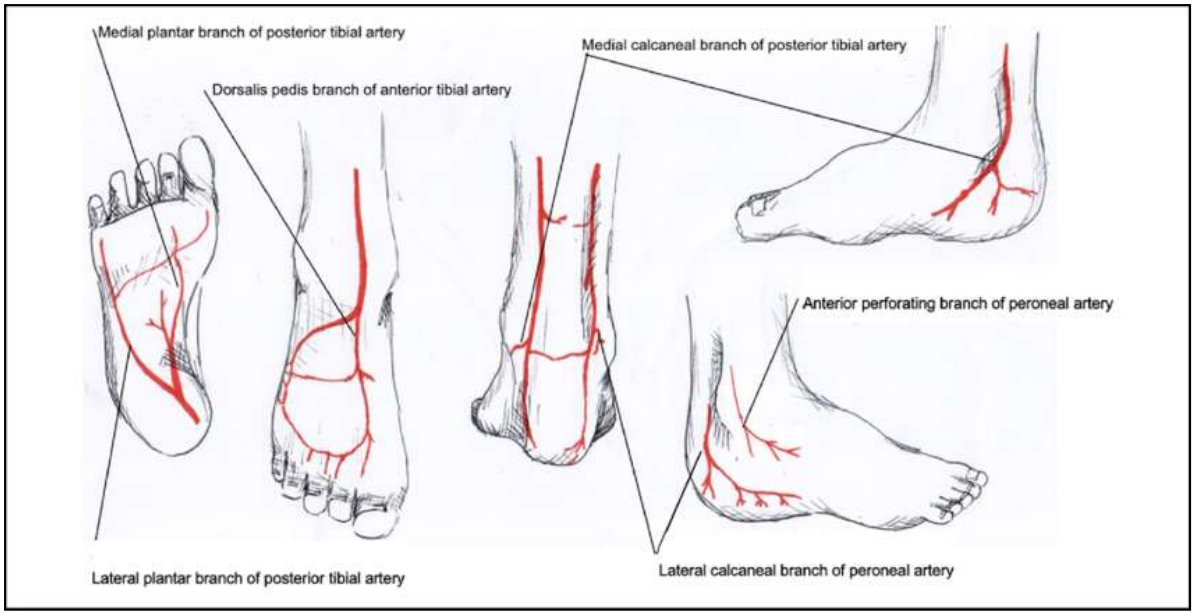

Nerve supply

- Deep fibular nerve
- Tibial nerve

SGD 09 - Applied anatomy of Lower limb

(1) A 28 - year - old male was admitted to the hospital complaining of severe pain following a blow to his right leg received during a football game. An X - ray revealed a fracture in the right fibular neck.

(1.1) What is the nerve most likely to be injured? (20 Marks)

(1.2) State the deformity of the foot. (30 Marks)

(1.3) Explain the anatomical basis for the deformity stated in 1.2. (50 Marks)

(Total = 100 Marks)

(2) A 25-year-old male sustained a crush injury to his right leg in a road traffic accident. He develops severe pain in the calf, which is out of proportion to the injury, with increasing swelling and pain on passive stretching of the toes.

(2.1) What are the clinical features of calf compartment syndrome. (20 Marks)

(2.2) Describe the anatomy of the fascial compartments of the calf. (40 Marks)

(2.3) Explain the pathophysiology of compartment syndrome of the calf. (40 Marks)

(Total = 100 Marks)

SGD 09 - Applied anatomy of Lower limb Answers

(1)

(1.1) What is the nerve most likely to be injured?

Common fibular nerve

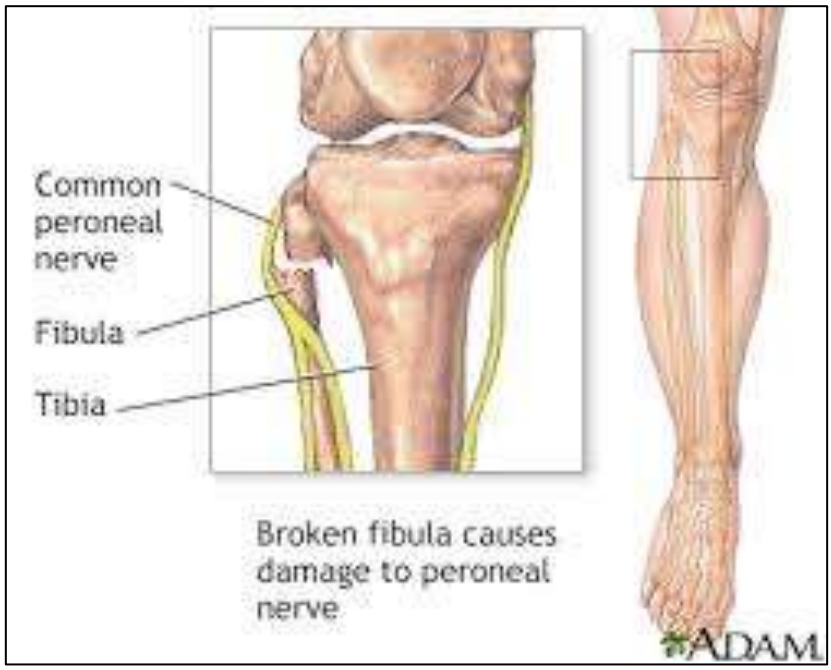

(1.2) State the deformity of the foot.

Foot drop



(1.3) Explain the anatomical basis for the deformity stated in 1.2.

- The **movements of the ankle joint** are mainly occurred by the **action of leg muscles**.
- **Leg** has a very distinct fascial separations into **3 compartments** as **anterior extensor compartment, posterior flexor compartment and lateral evertor compartment.**

- The **anterior compartment** of the leg contains tibialis anterior, extensor hallucis longus, extensor digitorum longus and peroneus tertius which are supplied by the **deep branch of the common peroneal nerve**.
- They are the **dorsiflexors of the ankle joint**.
- The **lateral group** of the leg composed of peroneus longus and brevis which are supplied by the **superficial branch of the common peroneal nerve**.
- They function as the **sole evertors** of the ankle joint.
- The **posterior compartment** composed of superficial gastrocnemius, plantaris and soleus muscles and deep flexor digitorum longus, flexor hallucis longus and tibialis posterior and popliteus muscles. All these muscles are supplied by the **tibial nerve**.
- These muscles function as the **plantar flexors of the ankle joint**.

- So, when the **common peroneal nerve gets damaged** as in above case, both the **anterior and lateral compartments** of the leg get denervated and **paralyzed.**
- But as the tibial nerve is intact, the **posterior compartment functions normally** and due to **unopposed action of posterior compartment muscles**, foot cannot be stably grounded and result in the **dropping of the foot.**
- This results in showing **high stepping gait** in this type of patients.



(2)

(2.1) What are the clinical features of calf compartment syndrome.

- Severe pain out of proportion to injury
- Pain on passive stretch (earliest and most important sign)
- Paresthesia
- Pallor
- Pulselessness (late sign)
- Paralysis (late and irreversible)

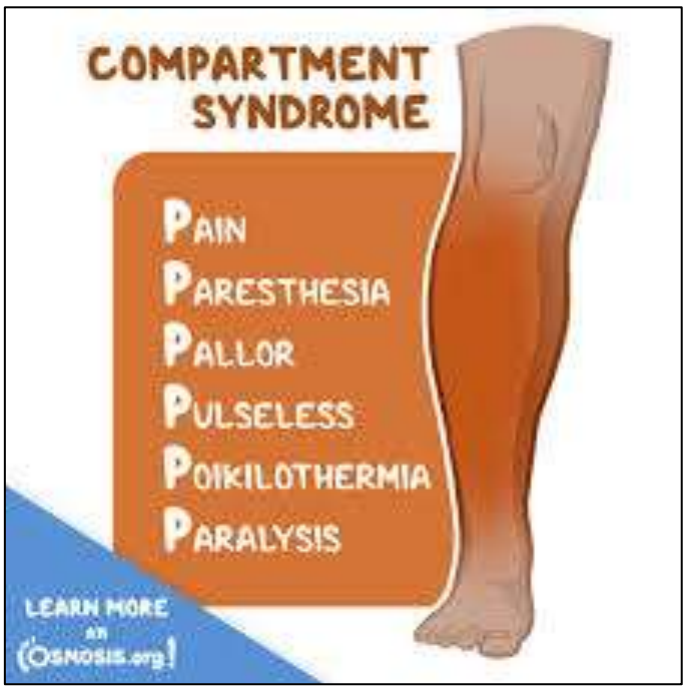

(2.2) Describe the anatomy of the fascial compartments of the calf.

The leg is divided into four fascial compartments by deep fascia and intermuscular septa:

- Anterior compartment
  - Muscles: Tibialis anterior, extensor hallucis longus, extensor digitorum longus, fibularis tertius
  - Nerve: Deep fibular nerve
  - Artery: Anterior tibial artery

- Lateral compartment
  - Muscles: Fibularis longus and brevis
  - Nerve: Superficial fibular nerve
  - Artery: Perforating branches of fibular artery

- Posterior compartment (superficial)
  - Muscles: Gastrocnemius, soleus, plantaris
  - Nerve: Tibial nerve
  - Artery: Posterior tibial artery

- Posterior compartment (deep)
  - Muscles: Tibialis posterior, flexor digitorum longus, flexor hallucis longus
  - Nerve: Tibial nerve
  - Artery: Posterior tibial and fibular arteries

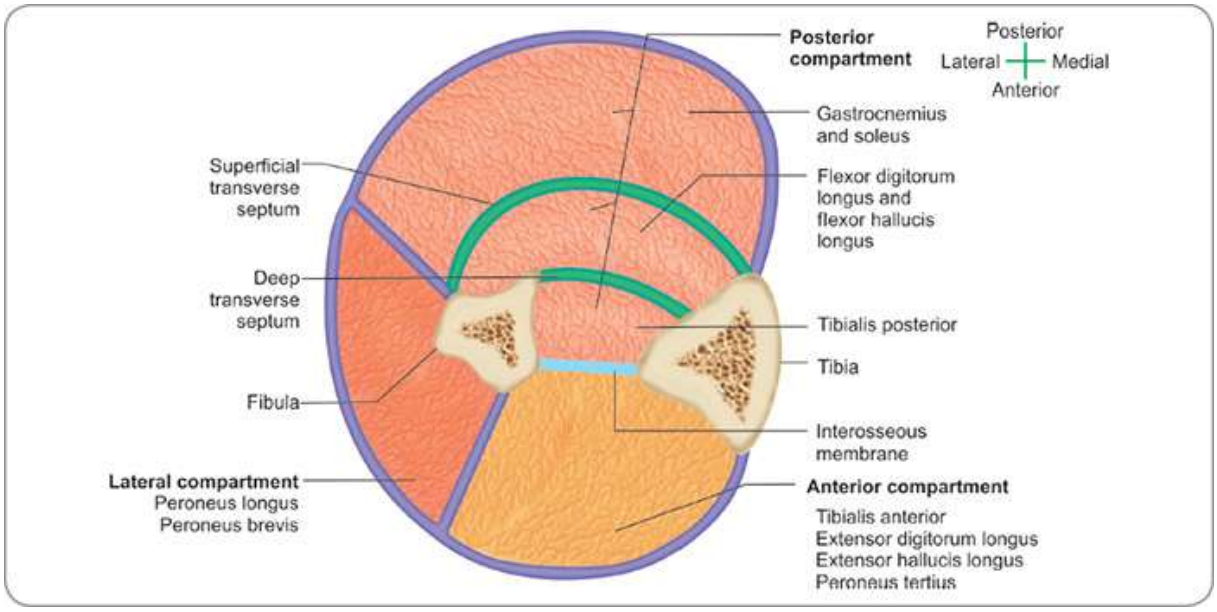

(2.3) Explain the pathophysiology of compartment syndrome of the calf.

- Compartment syndrome of the calf occurs when the **pressure within a closed osteofascial compartment increases to a level that compromises capillary blood flow**, leading to tissue ischemia.
- This usually happens because the leg compartments are surrounded by relatively non-distensible deep fascia, so any increase in volume rapidly raises **intracompartmental pressure.**
- The **common causes** include **fractures of the tibia**, which is the most frequent, followed by crush injuries, tight casts or bandages, and reperfusion injury after a period of ischemia.
- Less commonly, bleeding into a compartment or severe soft tissue trauma may be responsible.
- As the pressure rises, **venous outflow is obstructed first**, leading to increased capillary hydrostatic pressure and **fluid leakage into the interstitial space.**
- This worsens swelling and **further elevates compartment pressure**, creating a vicious cycle.
- Eventually **arterial inflow is compromised**, resulting in **muscle and nerve ischemia,** and if not relieved promptly, irreversible necrosis of tissues can occur within hours.

BATCH 02 – SEMESTER 03 TUTORIALS WITH ANSWERS

Tutorial 01 - Face

(1) A 30-year-old male presented with diplopia and severe pain in the left eye and was diagnosed with cavernous sinus thrombosis. He had a history of an untreated boil in the left nasal region one week earlier.

(1.1) Explain this case scenario. (60 Marks)

(1.2) Briefly describe the arterial supply of the face. (40 Marks)

(Total = 100 Marks)

(2) A 45-year-old man presents with difficulty chewing food and pain near the right preauricular region. On examination, there is tenderness over the angle of the mandible and weakness while clenching the teeth. Jaw deviation is observed when the patient opens his mouth.

(2.1) Name the muscles of mastication. Describe their origin, insertion, nerve supply, and main actions. (50 Marks)

(2.2) Explain the jaw deviation in this patient. (30 Marks)

(2.3) What is the most likely nerve involved? Give reasons. (20 Marks)

(Total = 100 Marks)

Tutorial 01 – Face Answers

(1)

(1.1) Explain this case scenario.

- The nasal region, particularly the area extending from the corners of the mouth to the bridge of the nose (the "**danger area of the face**"),
- It is the area **between angular & deep facial veins.**
- At the **medial angle of the eyelids**, there is a **communication** between the **ophthalmic and angular veins**.
- They **directly drain** into the **cavernous sinus.**
- **Deep facial vein** drains into the **pterygoid plexus** & connects to the **cavernous sinus** through emissary veins.
- It provides a pathway for the spread of infection from the face to the cavernous sinus, producing septic thrombosis.
- The cavernous sinus contains several important neurovascular structures, including the **internal carotid artery and cranial nerves III, IV, V_1, V_2, and VI**.
- **Diplopia** results from paralysis of extraocular muscles due to cranial nerve involvement, especially the abducens nerve (VI), which is most vulnerable because it lies freely within the sinus.
- **Severe eye pain** occurs due to irritation of the ophthalmic division of the trigeminal nerve (V_1).

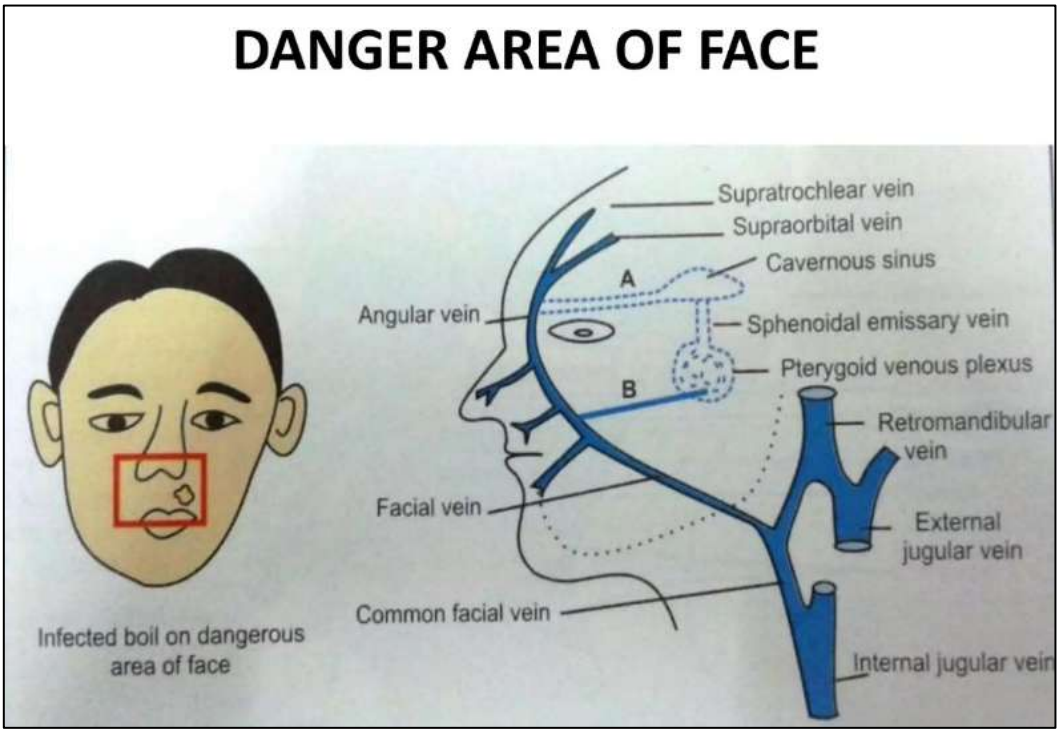

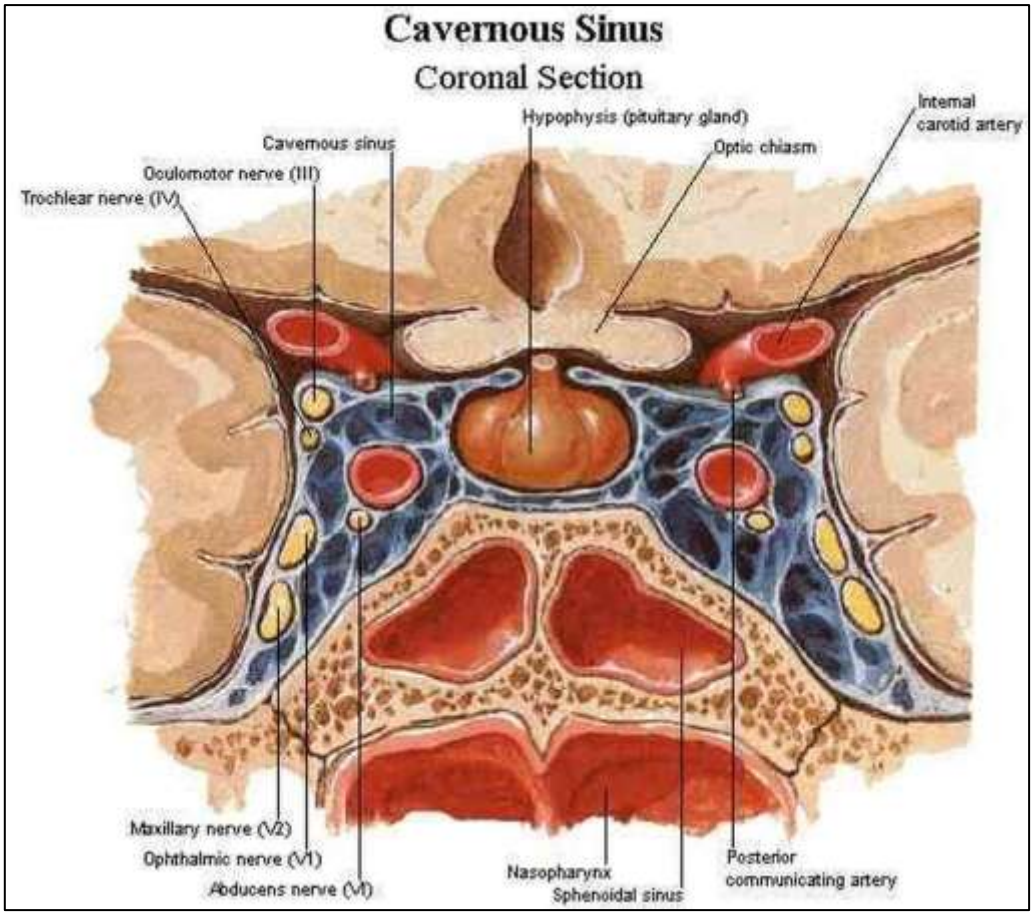

(1.2) **Briefly describe the arterial supply of the face.**

- The face receives the blood supply from the **facial, maxillary, ophthalmic and superficial temporal arteries.**
- The **facia**l artery arises from the **external carotid artery**.
- Having arched upward and over the submandibular salivary gland, it **curves around** the **inferior margin of the body of the mandibl**e at the anterior border of the masseter muscle.
- It runs upward in a **tortuous** course toward the angle of the mouth.
- It then ascends deep to the zygomaticus muscles and the levator labii superioris muscle and runs along the side of the nose to the medial angle of the eye, where it **anastomoses with the terminal branches of the ophthalmic artery**.
- Branches
    - The **inferior labial artery** arises near the angle of the mouth. It runs medially in the lower lip and anastomoses with its fellow of the opposite side.
    - The **superior labial artery** arises near the angle of the mouth. It runs medially in the upper lip and gives branches to the septum and ala of the nose.
    - The **lateral nasal artery** arises from the facial artery alongside the nose. It supplies the skin on the side and dorsum of the nose.

- The superficial temporal artery the smaller terminal branch of the external carotid artery & ascends in front of the auricle to supply the scalp.
    - The **transverse facial artery**, a branch of the superficial temporal artery, arises within the parotid gland. It runs forward across the cheek just above the parotid duct.

- The maxillary artery is the larger of the two terminal branches of the external carotid artery, and has three branches that supply the face, namely the mental, buccal and infraorbital arteries.
    - **Mental artery** arises from the first part of the maxillary artery & supplies muscles and skin in the chin region, and anastomoses with the inferior labial and submental arteries.
    - **Buccal artery** is a branch of the second part of the maxillary artery& supplies the cheek, and anastomoses with the infraorbital artery and with branches of the facial artery.
    - **Infraorbital artery** arises from the third part of the maxillary artery& supplyies the lower eyelid, the lateral aspect of the nose and the upper lip. The infraorbital artery has extensive anastomoses with the transverse facial and buccal arteries and with branches of the ophthalmic and facial arteries.

- The **supraorbital and supratrochlear** arteries, branches of the ophthalmic artery, supply the skin of the forehead.

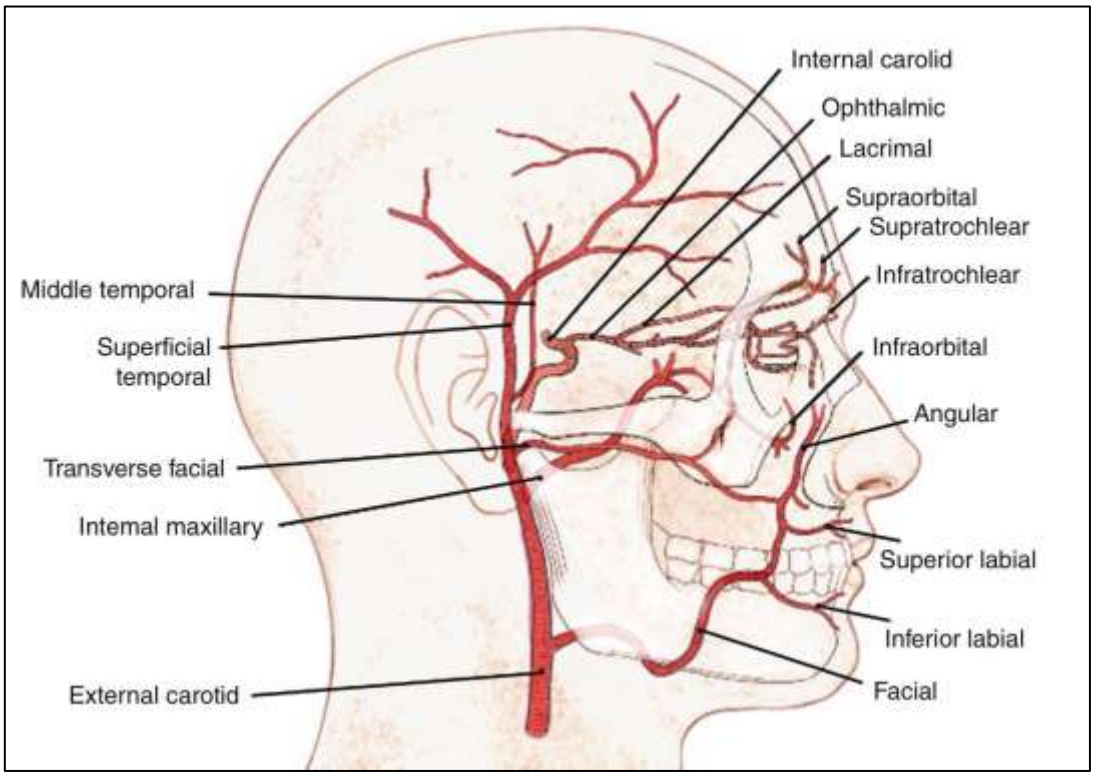

(2)

(2.1) Name the muscles of mastication. Describe their origin, insertion, nerve supply, and main actions.

- Masseter
- Temporalis
- Medial pterygoid
- Lateral pterygoid

Masseter

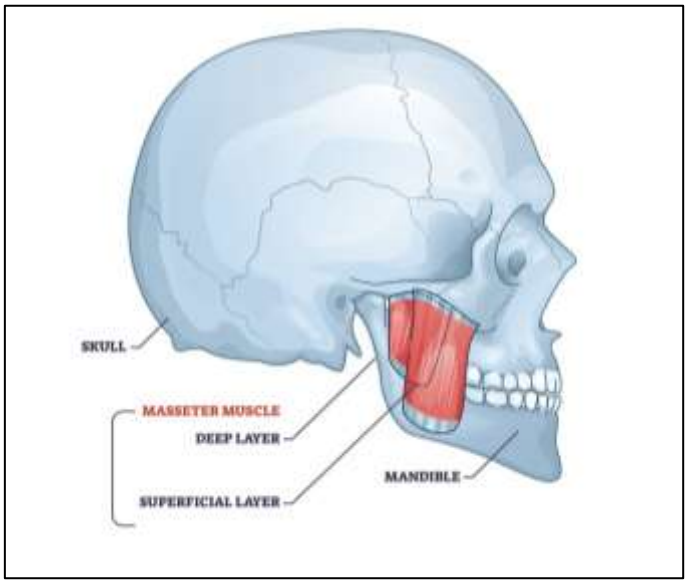

Origin: Zygomatic arch
Insertion: Lateral surface of ramus and angle of mandible
Nerve supply: Masseteric nerve (branch of mandibular nerve – CN V3)
Action: Elevates mandible (closes mouth); assists in protrusion.

Temporalis

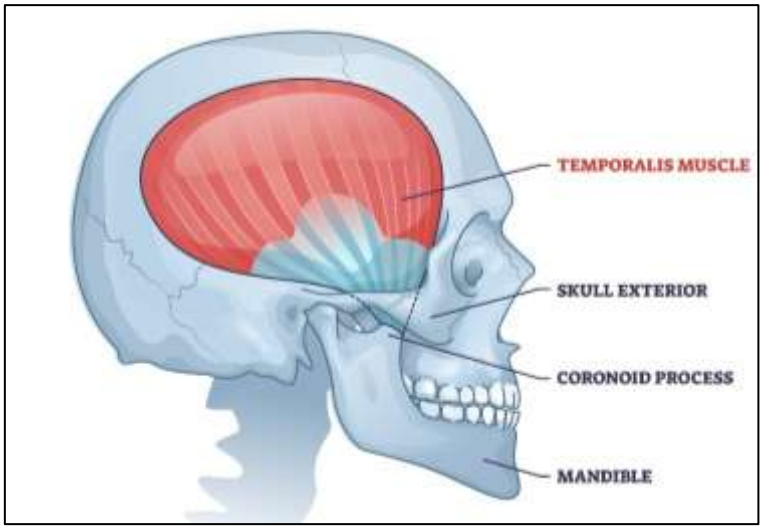

Origin: Temporal fossa
Insertion: Coronoid process and anterior border of ramus of mandible
Nerve supply: Deep temporal nerves (branch of CN V3)
Action: Elevates mandible; posterior fibers retract mandible.

Medial Pterygoid

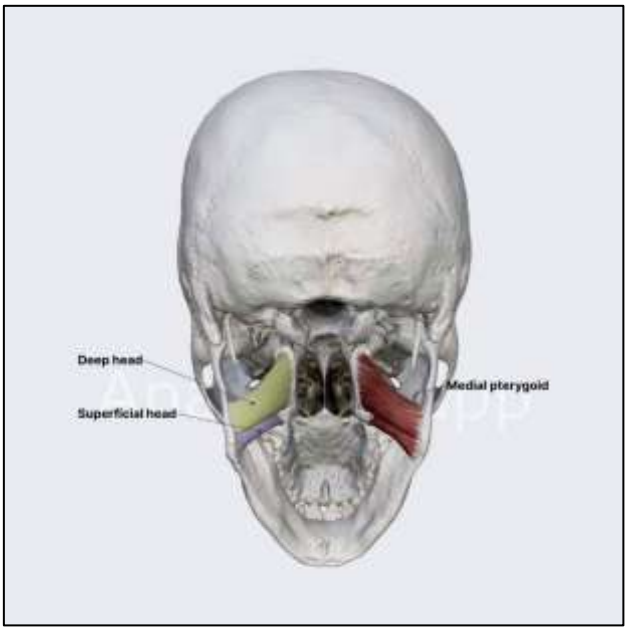

Origin: Medial surface of lateral pterygoid plate
Insertion: Medial surface of angle of mandible
Nerve supply: Nerve to medial pterygoid (branch of CN V3)
Action: Elevates mandible; assists in protrusion; side-to-side grinding.

Lateral Pterygoid

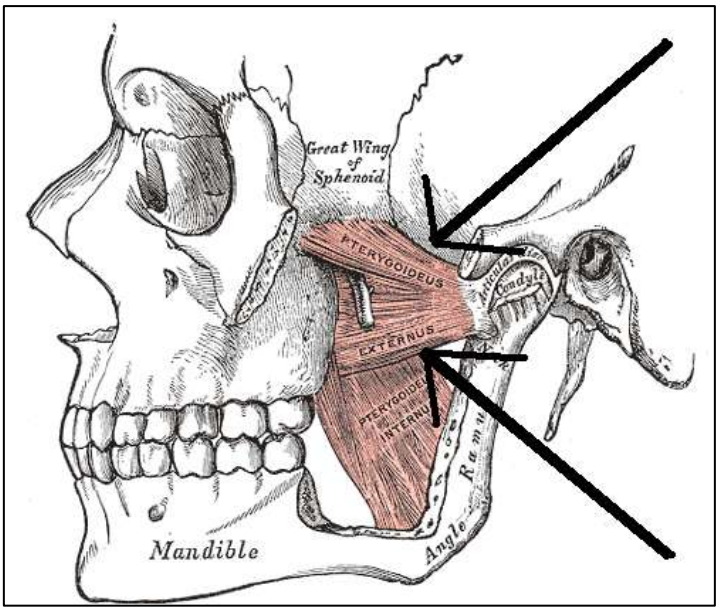

Origin:
- Superior head – Greater wing of sphenoid
- Inferior head – Lateral surface of lateral pterygoid plate

Insertion: Neck of mandible and articular disc of TMJ
Nerve supply: Nerve to lateral pterygoid (branch of CN V3)
Action:
- Protrudes mandible.
- Depresses mandible (opens mouth).
- Unilateral contraction → deviation to opposite side.

(2.2) Explain the jaw deviation in this patient.

- Jaw deviates **toward the side of the lesion during opening**.
- The Lateral pterygoid muscle pulls the mandible forward.
- If the right side is weak, the left muscle acts unopposed.
- The mandible deviates to the right (side of lesion).

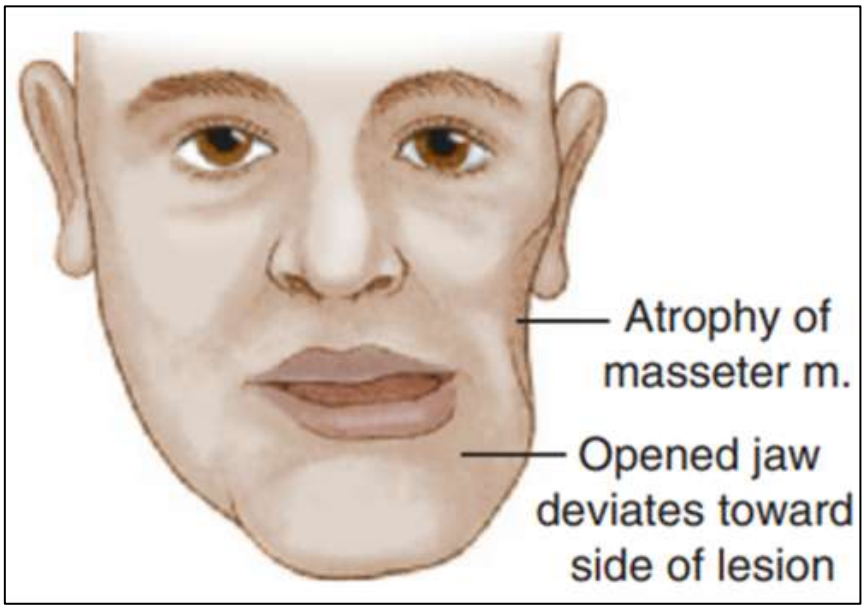

(2.3) What is the most likely nerve involved? Give reasons.

Mandibular nerve (V3)

Reasons:

- All muscles of mastication are supplied by V3.
- Weak clenching → masseter + temporalis involvement
- Temporal wasting → temporalis involvement
- Jaw deviation → lateral pterygoid involvement

Since multiple muscles are affected → this indicates a mandibular nerve lesion, not an isolated muscle injury.

Clinical Correlation

Damage to the mandibular nerve (V3) may occur due to:

- Trauma
- Tumors
- Infections in the infratemporal fossa

It results in:

- Difficulty chewing
- Weak jaw closure
- Jaw deviation toward the affected side

Tutorial 02 - Spinal Cord & Tracts

1) A 60-year-old man suddenly developed weakness of both lower limbs after a vascular event. On examination, he had bilateral spastic paralysis below the lesion and loss of pain and temperature sensation, while vibration and position sense were preserved.

   (1.1) What is the condition? (10 marks)
   (1.2) Name the artery most commonly involved in this condition. (10 marks)
   (1.3) Describe the arterial supply of the spinal cord. (40 marks)
   (1.4) Explain briefly the clinical features based on the tracts affected. (40 marks)
   (Total = 100 Marks)

2) A 55-year-old man had fallen from a height and was brought to the hospital. Investigations revealed that he had a fracture dislocation of the vertebral column at level of T10. On examination, he had the following features suggestive of hemisection of the spinal cord. (a) spastic paralysis of the right side below the level of lesion, (b) positive babinski sign on right side, (c) loss of tactile discrimination, vibratory and position sense on the right side below the level of lesion and (d) loss of pain and temperature sensations on the left side a few segments below the lesion.

   (2.1) State the side of the lesion in the spinal cord. (20 Marks)
   (2.2) Name the tracts responsible for each of the features listed above in (a), (b), (c) and (d). (30 Marks)
   (2.3) Draw a labeled cross section of the spinal cord, indicating the location of the damaged tracts. (50 Marks)
   (Total = 100 Marks)

Tutorial 02 - Spinal Cord & Tracts Answers

(1)

(1.1) What is the condition?

Anterior spinal cord syndrome

(1.2) Name the artery most commonly involved in this condition.

Anterior spinal artery

(1.3) Describe the arterial supply of the spinal cord.

The spinal cord receives its arterial supply from

- **two posterior spinal arteries**
- **one anterior spinal artery**
- **segmental artery & feeding artery**

Posterior Spinal Arteries

- The posterior spinal arteries arise **either directly from the vertebral arteries** inside the skull or **indirectly from the posterior inferior cerebellar arteries**.
- Each artery descends on the posterior surface of the spinal cord **close to the posterior nerve roots** and gives off branches that enter the substance of the cord.
- The posterior spinal arteries supply the **posterior 1/3 of the spinal cord.**

Anterior Spinal Artery

- The anterior spinal artery is formed by the **union of two arteries**, each of **which arises from the vertebral artery** inside the skull.
- The anterior spinal artery then descends on the anterior surface of the spinal cord within the **anterior median fissure.**
- Branches from the anterior spinal artery enter the substance of the cord and supply the **anterior 2/3 of the spinal cord.**

Segmental Spinal Arteries

- At each intervertebral foramen, the longitudinally running **posterior and anterior spinal arteries are reinforced by small segmental arteries** on both sides.
- The arteries are **branches of** the arteries outside the vertebral column (**deep cervical, intercostal, and lumbar arteries**).
- Having entered the vertebral canal, each segmental spinal artery gives rise to **anterior and posterior radicular arteries** that accompany the anterior and posterior nerve roots to the spinal cord.

- Additional **feeder arteries** enter the vertebral canal and **anastomose with the anterior and posterior spinal arteries.**
- **One large and important feeder artery**, the great anterior medullary artery of **Adamkiewicz**, arises from the **aorta** in the **lower thoracic or upper lumbar vertebral** levels; it is unilateral and, in the majority of persons, enters the spinal cord from the left side.

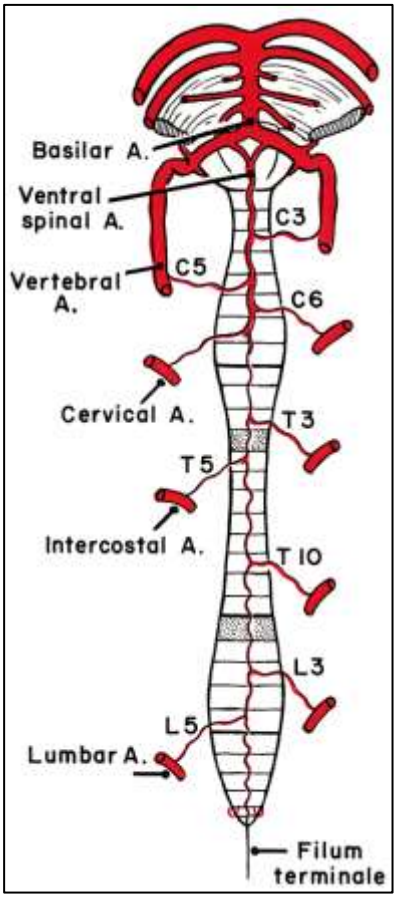

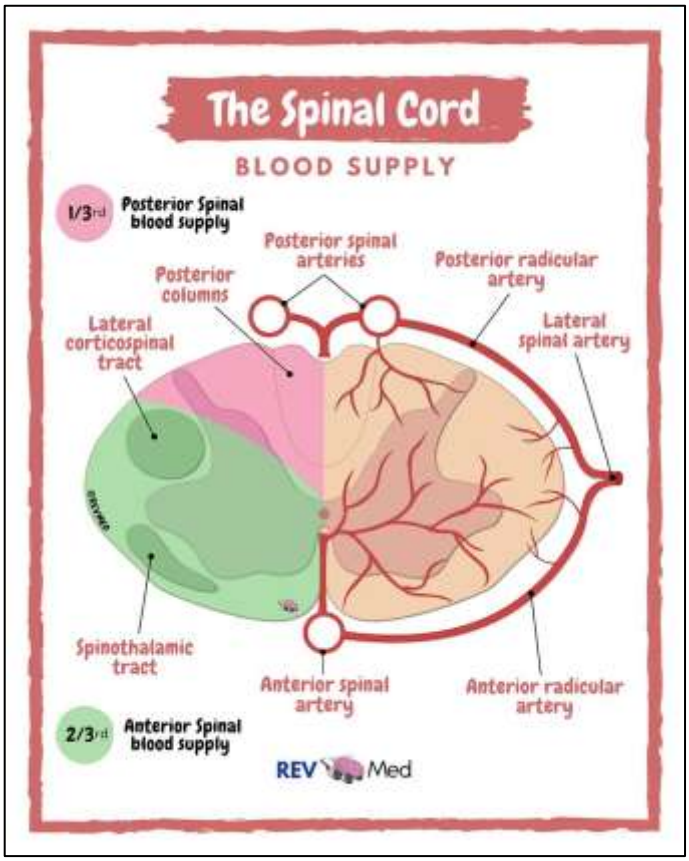

(1.4) Explain briefly the clinical features based on the tracts affected.

- **Bilateral motor paralysis** below the lesion - Damage to the **Corticospinal tract.**
- The corticospinal tract carries voluntary motor impulses.
- Lesion produces **upper motor neuron signs below the level of lesion**.
- Clinical findings
  Spastic paralysis
  Hyperreflexia
  Positive Babinski sign

- **Loss of pain and temperature** sensation - Damage to the **Spinothalamic tract.**
- The spinothalamic tract carries pain and temperature.
- Fibers **cross within 1–2 segments**, so loss occurs below the lesion.
- Clinical finding
  Bilateral loss of pain and temperature sensation.

- **Autonomic dysfunction** - Damage to **autonomic pathways** in the anterior spinal cord.
- Clinical findings
  Bladder dysfunction
  Bowel dysfunction
  Sexual dysfunction.

- **Preservation of vibration and position** sense - The **dorsal column–medial lemniscus** pathway remains **intact.**
- These tracts are **located in the posterior part of the spinal** cord, supplied mainly by the **Posterior spinal arteries**.
- Clinical findings
  Intact vibration sense
  Intact proprioception
  Intact fine touch

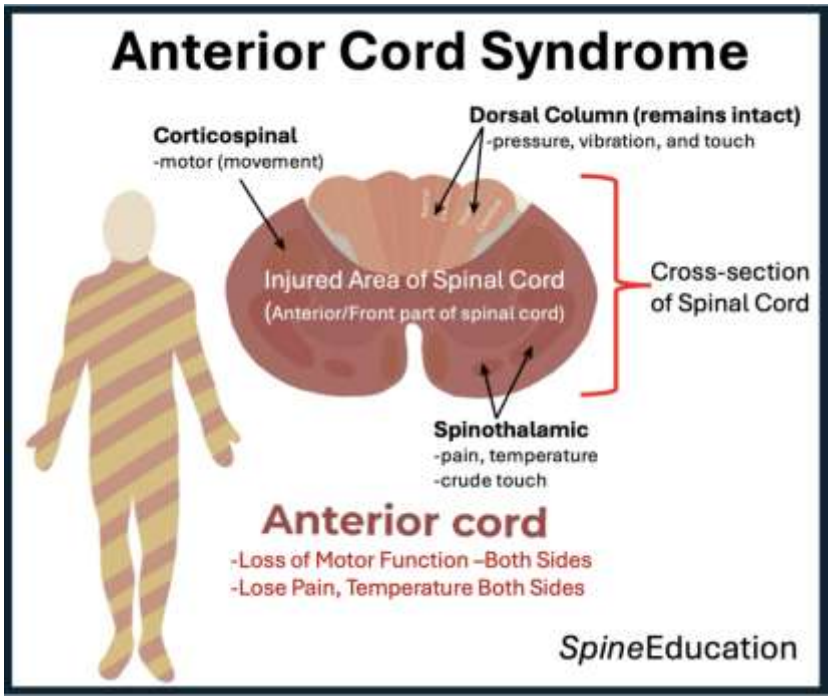

(2)

(2.1) State the side of the lesion in the spinal cord.

Right side

- **Motor paralysis (spastic) is on the right side** → corticospinal tract damage occurs **ipsilateral** to the lesion.
- **Loss of vibration, position and discriminative touch on the right side** → dorsal column pathway also runs **ipsilaterally**.
- **Loss of pain and temperature on the left side** → spinothalamic tract crosses **1–2 segments above entry**, so damage on the right produces sensory loss on the **contralateral side**.

Therefore, the hemisection is **right-sided**.

(2.2) Name the tracts responsible for each of the features listed above in (a), (b), (c) and (d).

Feature	Tract involved	Explanation
(a) Spastic paralysis on right side below lesion	**Lateral corticospinal tract**	Upper motor neuron tract controlling voluntary movement
(b) Positive Babinski sign on right side	**Lateral corticospinal tract**	UMN lesion produces Babinski reflex
(c) Loss of tactile discrimination, vibration and position sense on right side	**Dorsal column–medial lemniscus pathway** (Fasciculus gracilis at T10 level)	Carries proprioception, vibration, fine touch
(d) Loss of pain and temperature on left side	**Spinothalamic tract (anterolateral system)**	Fibers cross to opposite side within 1–2 spinal segments

(2.3) Draw a labeled cross section of the spinal cord, indicating the location of the damaged tracts.

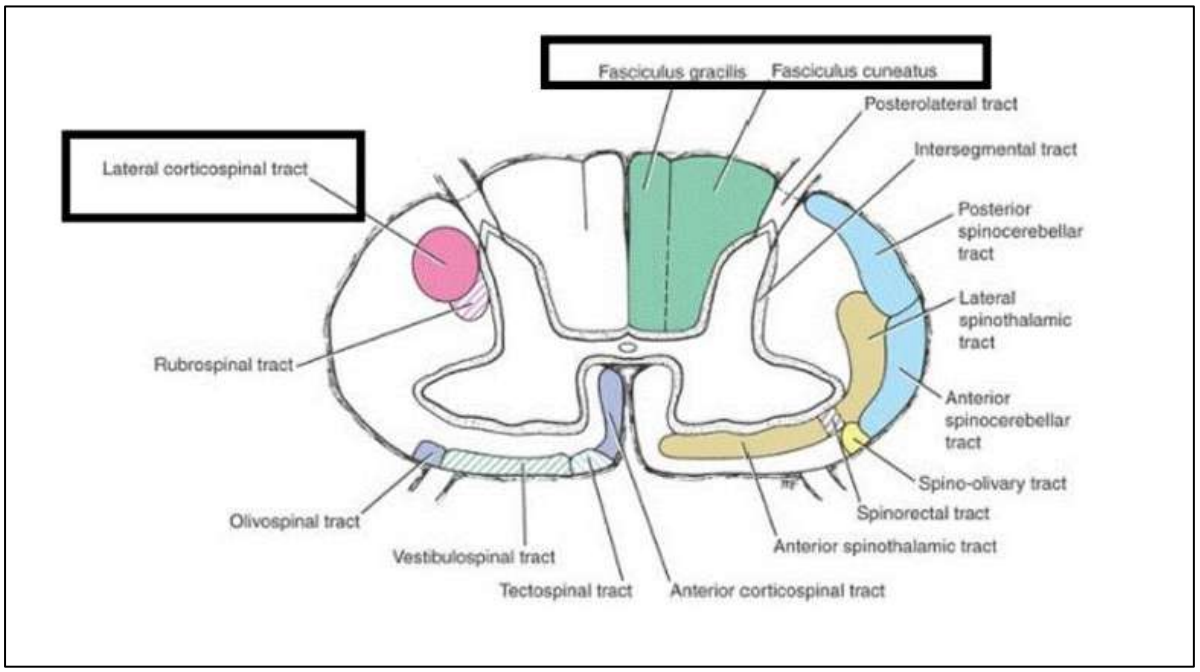

Tutorial 03 - Hip & Gluteal Region

(1) Describe the hip joint in relation to

(1.1) Type of joint (20 marks)

(1.2) Movements (30 marks)

(1.3) Stability (50 marks)

(Total = 100 Marks)

Tutorial 03 - Hip & Gluteal Region Answers

(1)

(1.1) Type of joint.

- The hip joint is **synovial** joint of the **ball and socket** variety.
- In the hip joint, the **head of the femur (ball)** articulates with the **acetabulum** of the pelvic bone (socket).

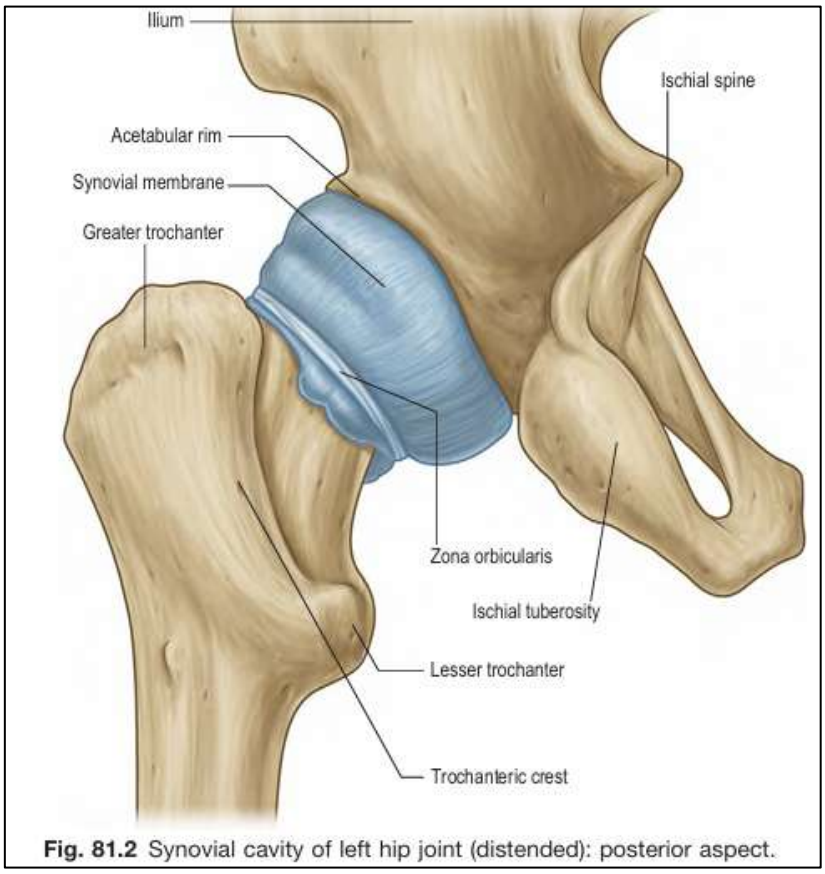

Fig. 81.2 Synovial cavity of left hip joint (distended): posterior aspect.

(1.2) Movements.

- The hip joint shows below movements.
- **Hip flexion** is done by **iliacus and psoas major** supported by rectus femoris, Sartorius and pectineus.
- **Hip extension** is done by the **hamstring muscles** and gluteus maximus in extreme situations. **Gluteus minimus and medius** along with **tensor fascia latae abduct**.
- A**dductors** are **longus, brevis and magnus adduct.**
- The same muscles that abducted also participate in **medial rotation**.
- **Pyriformis, obturator internus and externus**, and **quadratus femoris** perform **lateral rotation.**

(1.3) Stability.

- When it comes to the hip joint, the **bony factors** itself provide much stability.
- **Femoral head** connected to the shaft by its thin neck nicely fits into the **deep acetabulum**.
- The **acetabular labrum** deepens it even further.
- The hip joint also has a **strong but lax capsule** with which the iliofemoral, ischiofemoral and pubofemoral fuse.
- The **iliofemoral ligament** especially is important in joint stability.
- The **short muscles of the gluteal region** are important muscular stabilizers.
- Thip joint is considered a much **more stable joint than the shoulder joint** and accounts for far less dislocations.

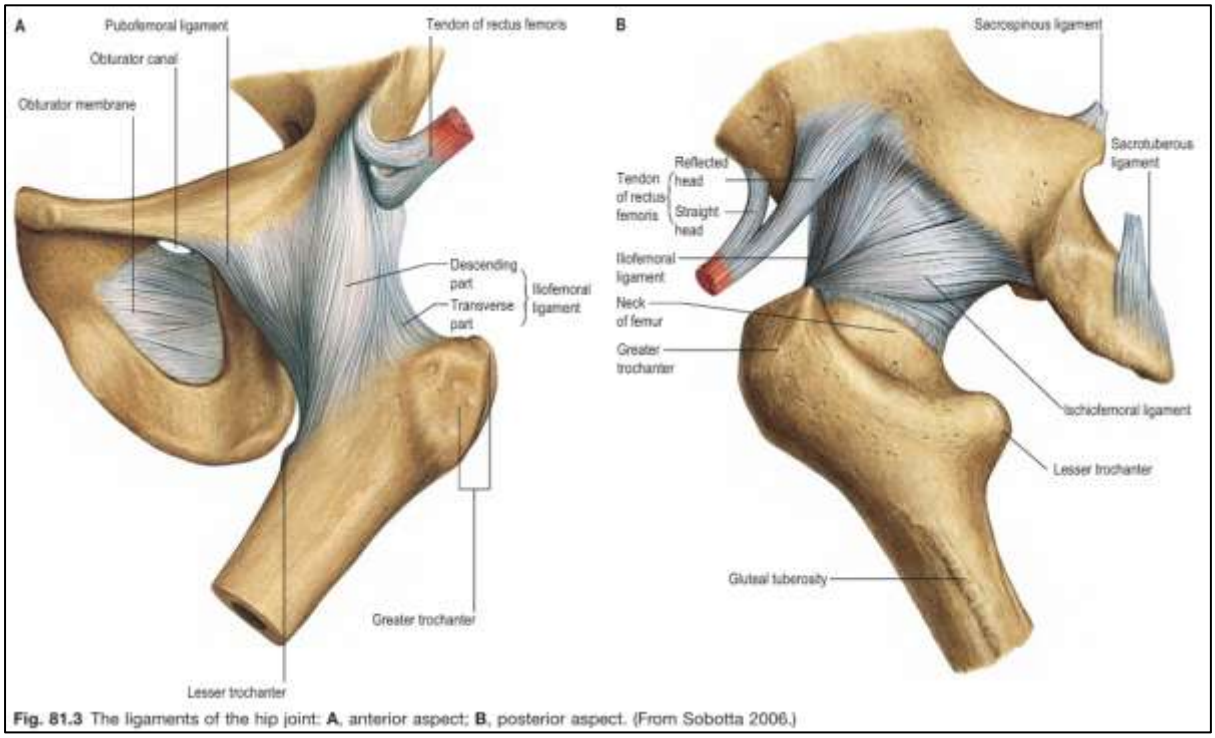

Fig. 81.3 The ligaments of the hip joint: **A**, anterior aspect; **B**, posterior aspect. (From Sobotta 2006.)

BATCH 02 – CAT 03 MOCK EXAM PAPERS WITH ANSWERS

Batch 02 – CAT 03 - MOCK MCQ Paper

MULTIPLE CHOICE QUESTIONS **Time: 1 hour**

This paper consists of 10 True or False type questions and 10 Single Best Answer type questions.

True/ False Questions.

(1) True/ False regarding the lateral wall of the nose?

(A) The sphenoid sinus opens into the sphenoethmoidal sinus.
(B) The ethmoidal bulla is situated under the middle concha.
(C) The hiatus semilunaris is a groove below the ethmoidal bulla.
(D) Frontal air sinus opens into the superior meatus.
(E) The nasolacrimal duct opens anterior to the infundibulum of hiatus semilunaris.

(2) True/ False regarding the tongue

(A) The tip has bilateral lymph drainage which crosses midline.
(B) The taste and general sensation from the posterior 1/3 are carried by the 9th cranial nerve.
(C) Has genioglossus which prevents the tongue been pulled posteriorly.
(D) The posterior part lymph drains to the deep cervical lymph nodes.
(E) Lingual vein lies deep to it.

(3) Which muscles are supplied by the occulomotor nerve?

(A) Superior oblique
(B) Superior rectus
(C) Inferior rectus
(D) Involuntary portion of levator palpebrae superioris
(E) Lateral rectus

(4) True or false regarding the dorsal columns?

(A) Fasciculus gracilis contains fibers received at sacral and lumbar levels.
(B) Axons of first order neurons decussate in the medulla.
(C) Medial lemniscus terminates at the ventral posterolateral nucleus of the thalamus.
(D) Carry proprioception and discriminative touch.
(E) Hemi section of the spinal cord causes contralateral loss of sense of vibration.

(5) Superior constrictor of the pharynx attaches to?

(A) Stylohyoid ligament
(B) Pterygomandibular raphe
(C) Hyoid bone
(D) Pharyngeal raphe
(E) Pterygoid hamulus

(6) True/ False regarding the ear?

(A) Ceruminous glands are modified sebaceous glands.
(B) External auditory meatus is supplied by auriculotemporal nerve.
(C) Joints between middle car ossicles are secondary cartilaginous type.
(D) Cochlea is pierced by the cochlear nerve.
(E) Otitis media is more common in children than in adults.

(7) Which of the following structures is not a component of the diencephalon?

(A) Thalamus
(B) Hypothalamus
(C) Epithalamus
(D) Subthalamus
(E) Pons

(8) True/ False regarding the vagus nerve?

(A) Crosses the left subclavian artery in the root of the neck.
(B) Carries general visceral sensory fibers.
(C) Leaves the skull along with the internal jugular vein.
(D) Leaves the medulla as a number of rootlets between the olive and pyramid.
(E) Lies posterolateral to the common carotid artery.

(9) Which of the following bony parts are palpable?

(A) Head of femur
(B) Ischial spine
(C) Shaft of femur
(D) Anterior inferior iliac spine
(E) Coccyx

(10) True/ False regarding the knee joint?

(A) Is a synovial hinge joint.
(B) Is capable of medial and lateral rotations.
(C) Capsule is deficient anteriorly and synovial membrane through this give rise to suprapatellar bursa.
(D) Osteomyelitis of tibia leads to secondary infections of the knee joint.
(E) Popliteus tendon is intracapsular and extra synovial.

Single Best Response (SBR) questions.

(11) A 54-year-old patient was diagnosed with a Maxillary sinus carcinoma and was admitted to the ENT ward. The patient had lost sensation of the skin over the maxilla. Which of the following nerve is affected?

(A) External nasal nerve
(B) Infratrochlear nerve
(C) Infraorbital nerve
(D) Supratrochlear nerve
(E) Supraorbital nerve

(12) A 60-year-old man presents with deviation of the tongue to the right side on protrusion. On examination, there is evidence of unilateral paralysis of a tongue muscle. Which of the following muscles is most likely affected?

(A) Superior longitudinal muscle
(B) Genioglossus
(C) Hyoglossus
(D) Inferior longitudinal muscle
(E) Intrinsic muscle of the larynx

(13) A 65-year-old female had met a doctor complaining about left side facial nerve paralysis and hearing impairment. Where is the possible site for the injury?

(A) In the inner ear.
(B) At the internal auditory meatus.
(C) In the middle ear cavity.
(D) In the stylomastoid foramen.
(E) Within the parotid gland.

(14) Which of the following is used to recognize the brain stem death?

(A) Gag reflex
(B) Papillary light reflex
(C) Babinski sign
(D) Cremasteric reflex
(E) Knee joint exaggeration

(15) 40-years-old woman presented with hoarseness of voice. Right recurrent nerve was damaged. What muscle is not affected?

(A) Right cricothyroid
(B) Right posterior cricoarytenoid
(C) Right thyroarytenoid
(D) Trans arytenoid muscle
(E) Oblique arytenoid muscle

(16) During CNS development, different regions of the brain arise from primary brain vesicles. Which structure develops from the mesencephalon?

(A) Cerebellum
(B) Medulla oblongata
(C) Midbrain
(D) Thalamus
(E) Cerebral hemispheres

(17) A patient presents with increased appetite and significant weight gain. A lesion is suspected in the part of the hypothalamus responsible for regulating satiety. Which nucleus of the hypothalamus is most likely affected?

(A) Lateral nucleus
(B) Ventromedial nucleus
(C) Suprachiasmatic nucleus
(D) Supraoptic nucleus
(E) Paraventricular nucleus

(18) A patient with untreated middle ear infection develops mastoiditis. Infection spreads from the middle ear to the mastoid air cells. Through which structure does this infection most commonly spread?

(A) Oval window
(B) Round window
(C) Aditus to mastoid antrum
(D) Pharyngotympanic tube
(E) External auditory canal

(19) A 34-year-old man who was subjected to a road traffic accident came to the ward with a fracture in the upper end of the femur. One month later a vascular necrosis had occurred in the head of the femur. Which is the most likely site of fracture?

(A) Middle of the neck of femur
(B) Base of neck of femur
(C) Pertrochanteric fracture
(D) Subcapital fracture
(E) Subtrochanteric fracture

(20) A rugby player was fallen on his flexed right knee and had severe pain at the knee. An orthopedic surgeon who examined him told him that there was an undue posterior mobility of right tibia over the femur. What is the structure most likely to get damaged?

(A) Anterior cruciate ligament
(B) Lateral meniscus
(C) Medial collateral ligament
(D) Medial meniscus
(E) Posterior cruciate ligament

Batch 02 – CAT 03 - MOCK MCQ Paper Answers

True/ False Questions.

(1)

(A) **F** - To the sphenoethmoidal recess.
(B) **T**
(C) **T** – Anterior & inferior to ethmoidal bulla
(D) **F** - To the middle meatus through the frontonasal duct
(E) **F** - Hiatus semilunaris is in the middle meatus.

Nasolacrimal duct → inferior nasal meatus under inferior conchae

Frontonasal duct → middle meatus

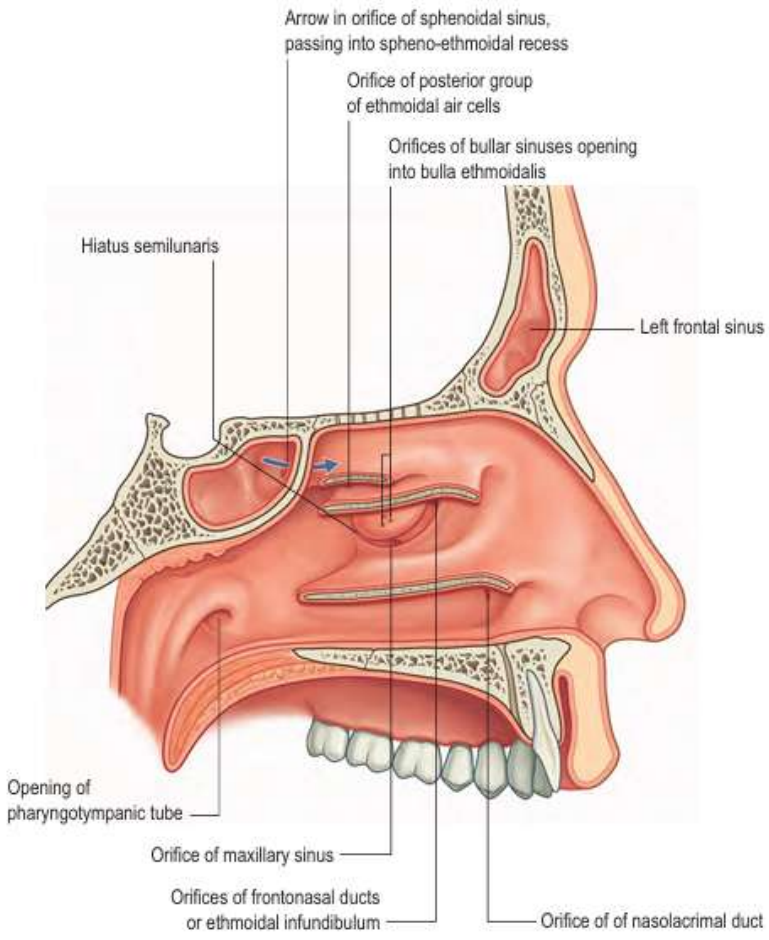

Fig. 32.5 Lateral wall of the nasal cavity. The conchae have been removed to show the positions of the ostia of the paranasal sinuses and the nasolacrimal duct. (From Drake, Vogl and Mitchell 2005.)

(2)

(A) **T** - The tip of the tongue drains bilaterally to submental lymph nodes, so spread can cross the midline.

(B) **T** - Glossopharyngeal nerve (CN IX) carries both general sensation and taste from the posterior one-third.

(C) **T** - Genioglossus protrudes the tongue and prevents it from falling backward, especially important in airway patency.

(D) **T** - Posterior one-third drains mainly to deep cervical nodes (especially jugulodigastric).

(E) **F** - The deep lingual vein lies superficial on the undersurface of the tongue (visible clinically), not deep.

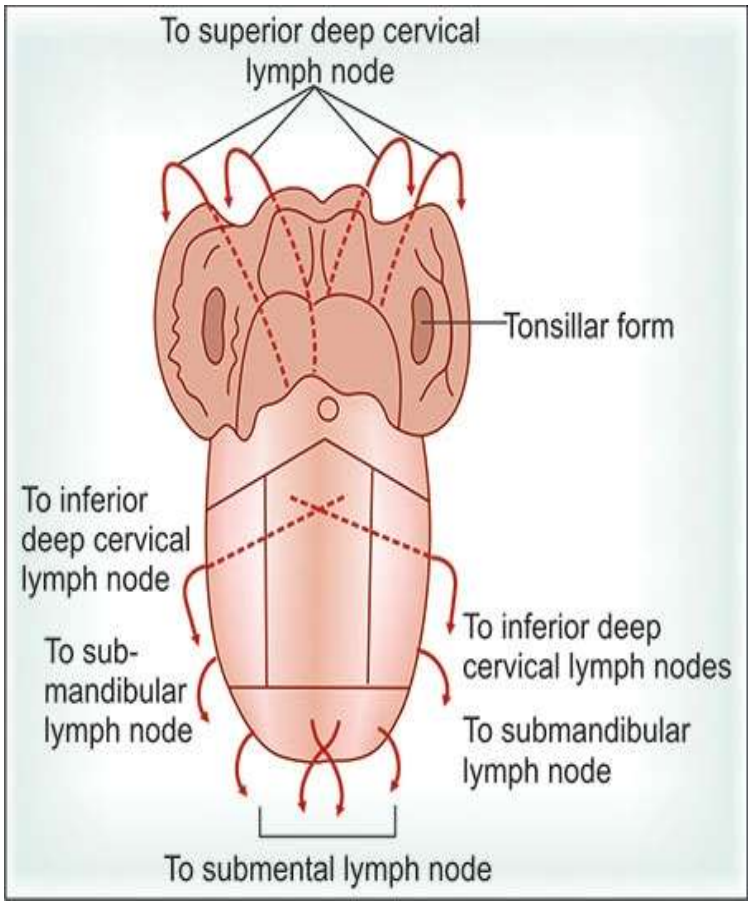

(3)

(A) **F**

(B) **T**

(C) **T**

(D) **F**

(E) **F**

Occulomotor nerve supplies,
- Superior rectus
- Inferior rectus
- Medial rectus
- Inferior oblique
- Levator palpebrae superioris (skeletal/voluntary part)
- Parasympathetic fibers to sphincter pupillae & ciliary muscle (via ciliary ganglion).

Superior oblique is supplied by Trochlear nerve (CN IV).
Lateral rectus is supplied by Abducens nerve (CN VI).
Involuntary portion of levator palpebrae superioris is superior tarsal muscle (Müller's muscle), supplied by sympathetic fibers, not CN III.

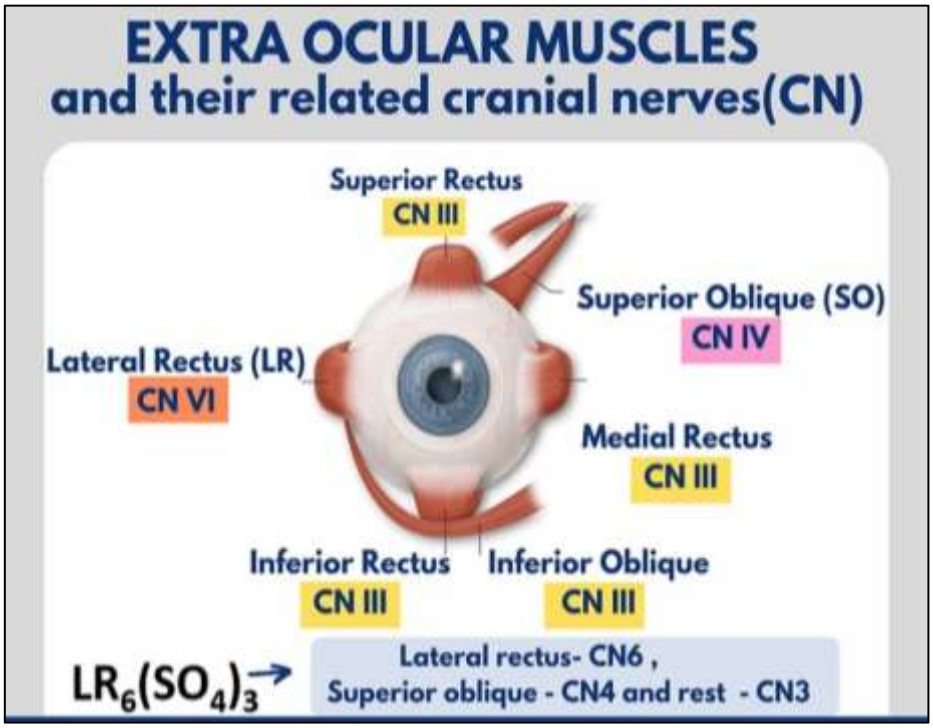

(4)
- (A) **T**
- (B) **F**
- (C) **T**
- (D) **T**
- (E) **F**

The dorsal column–medial lemniscus pathway carries fine touch, vibration, and conscious proprioception from the body to the brain.

1. First-order neurons
   Cell bodies in dorsal root ganglia.
   Enter spinal cord and ascend ipsilaterally in:
   - Fasciculus gracilis (lower body: sacral, lumbar)
   - Fasciculus cuneatus (upper body: thoracic, cervical)

2. Second-order neurons
   Synapse in nucleus gracilis and nucleus cuneatus in the medulla.
   Axons decussate (cross) as internal arcuate fibers → form the medial lemniscus.

3. Third-order neurons
   Synapse in VPL nucleus of thalamus. Project to primary somatosensory cortex.

.

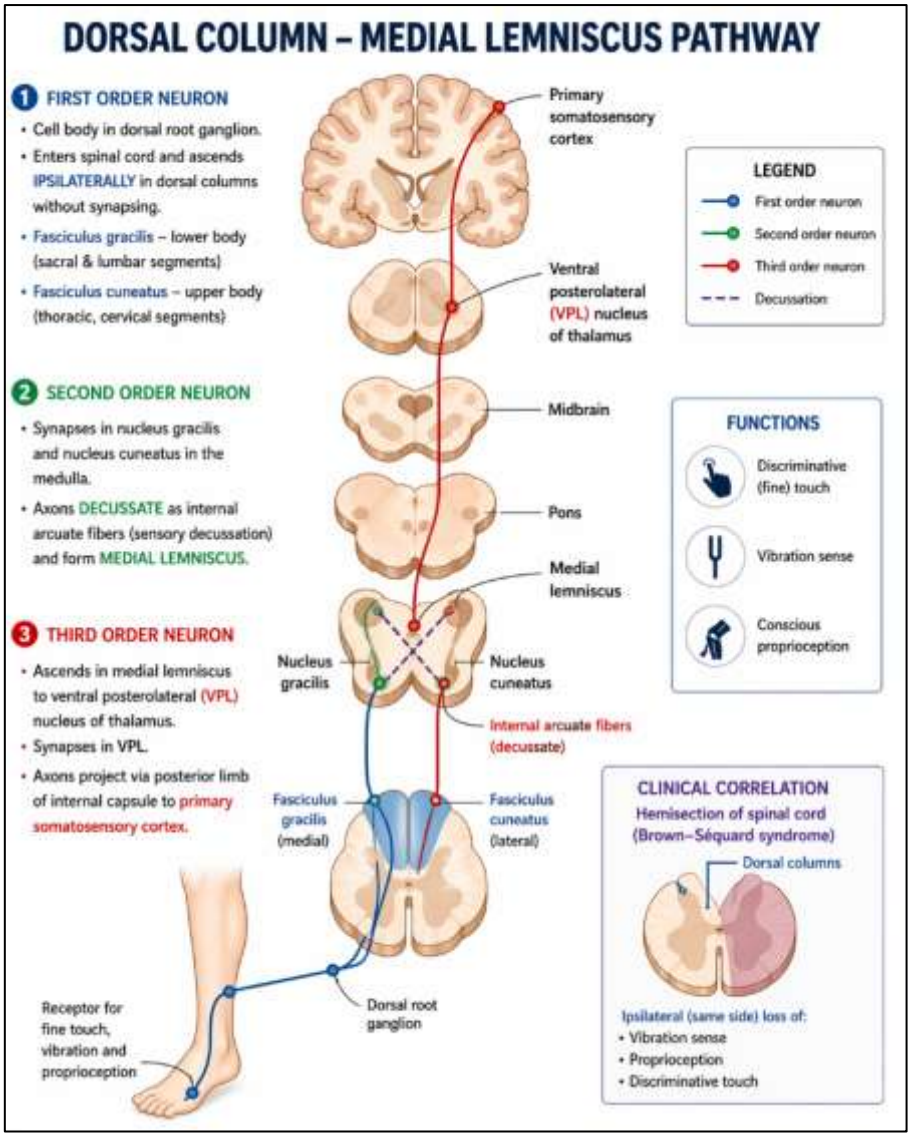

(5)

(A) **F**
(B) **T**
(C) **F**
(D) **T**
(E) **T**

The superior constrictor muscle is a quadrilateral, thin muscle of the upper pharynx that initiates swallowing by narrowing the pharyngeal cavity.

- It originates from the lower part of the medial pterygoid plate, pterygoid hamulus, pterygomandibular raphe, and mandibular mylohyoid line.
- It inserts posteriorly into the median pharyngeal raphe and the pharyngeal tubercle of the occipital bone.

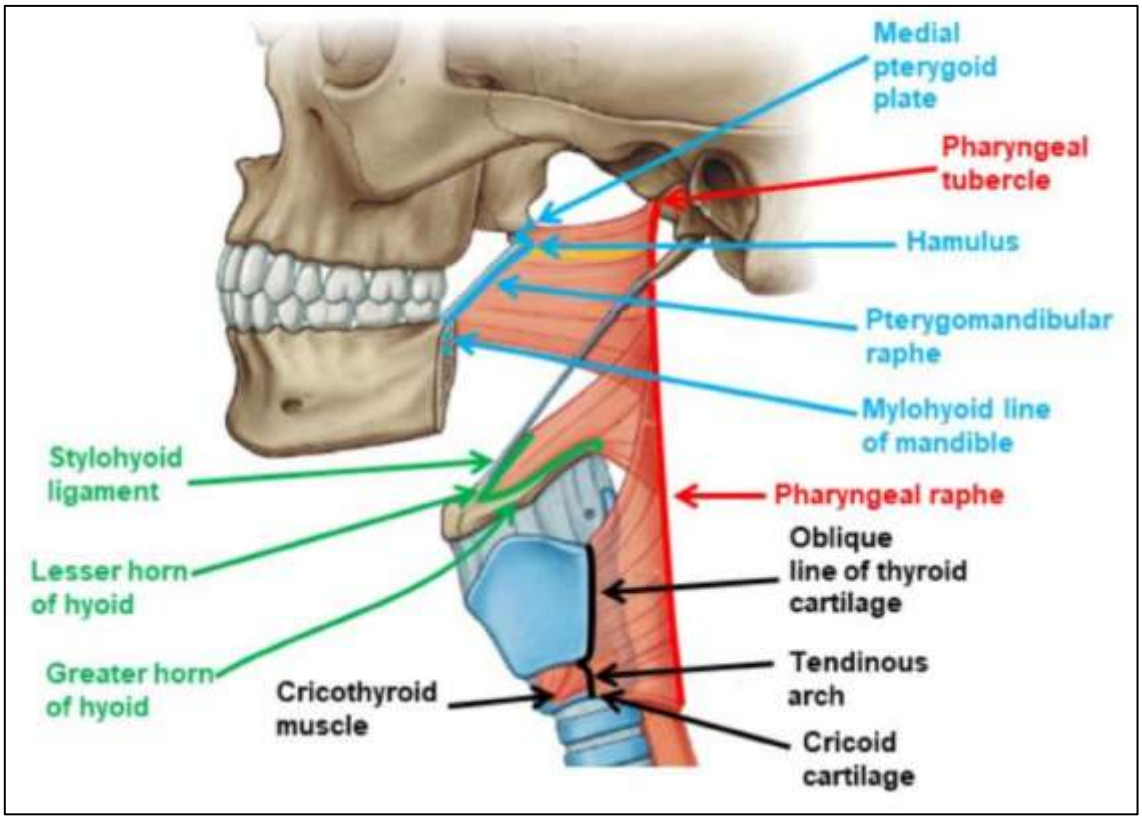

(6)

(A) **F** - Modified sweat gland.

(B) **T**- The auriculotemporal nerve supplies the anterior and superior walls and the auricular branch of vagus supplies the posterior and inferior walls.

(C) **F** - Synovial type.

(D) **F**

(E) **T**

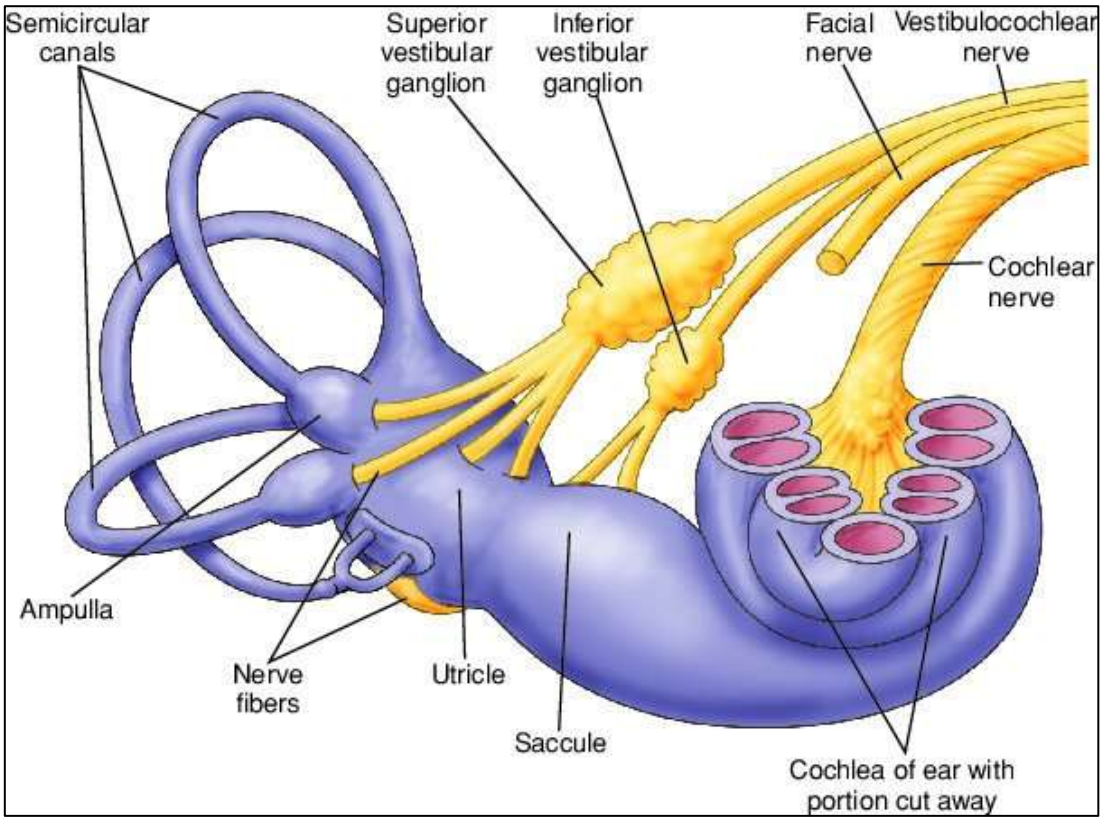

(7)

(A) **F**

(B) **F**

(C) **F**

(D) **F**

(E) **T**

The diencephalon consists of:

- Thalamus
- Hypothalamus
- Epithalamus (includes pineal gland)
- Subthalamus

The pons is part of the brainstem, not the diencephalon.

(8)

(A) **F** – The left vagus crosses the arch of the aorta, not the subclavian artery (that relation is more relevant to the left recurrent laryngeal nerve looping under the arch).
(B) **T -** It carries GVS fibers from thoracic and abdominal viscera.
(C) **T**
(D) **F** - The rootlets lie between olives and inferior cerebellar peduncle.
(E) **T** - In the carotid sheath, it lies posteriorolaterally between the internal jugular vein and common carotid artery.

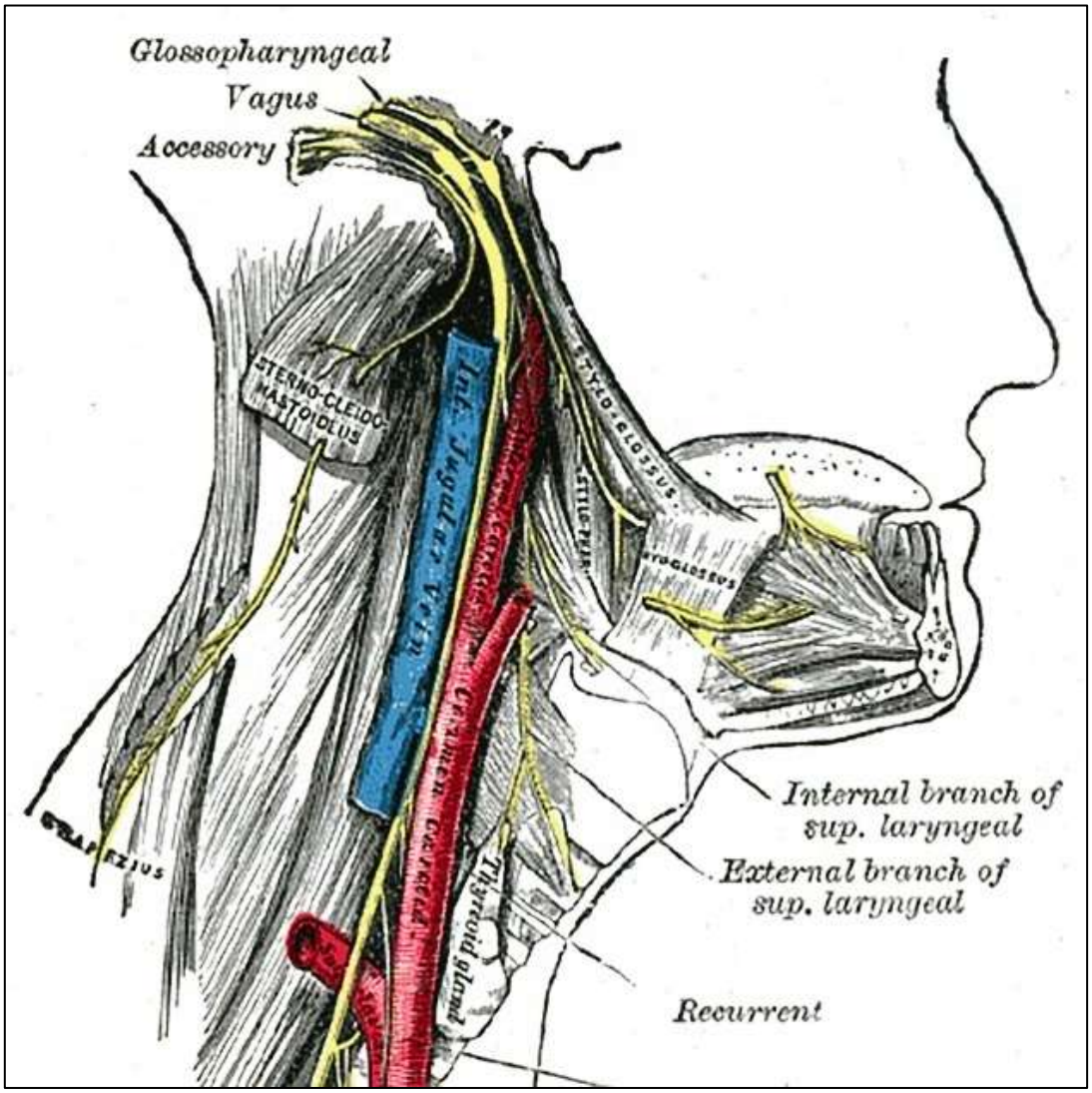

(9)

(A) **F**

(B) **F** - Ischial spine is not externally palpable — it can only be felt per vaginally or per rectally, not on surface examination.

(C) **F**

(D) **F** - Anterior inferior iliac spine is generally not palpable — unlike the ASIS, which is easily felt, AIIS lies deeper.

(E) **T** - Coccyx can be felt at the lower end of the vertebral column in the midline (especially in thin individuals).

(10)

(A) **T** - Joint between femur and tibia is a synovial hinge type but the joint between femur and patella is synovial plane joint. Knee joint is called a modified hinge joint.

(B) **T** - These movements are useful in locking and unlocking mechanisms of knee joint.

(C) **T** - Capsule is attached to the margins of articular surfaces in sides and posterior aspect but anteriorly it is deficient due to presence of patella. This absence permits the synovial membrane to push upward beneath the quadriceps tendon by forming Supra-patellar Bursa.

(D) **F** - Upper end of the tibial shaft is one of the most common sites for acute osteomyelitis. Due to safe attachment of knee joint capsule tibial diaphysis is extracapsular. So, involvement of the knee joint therefore occurs only in the late and neglected case.

(E) **T** - Popliteus arises from lateral side of the lateral condyle of the femur and emerges from the joint capsule posteriorly and inserted into back of upper end of tibia. So, its tendon is intracapsular but extra articular and extra synovial.

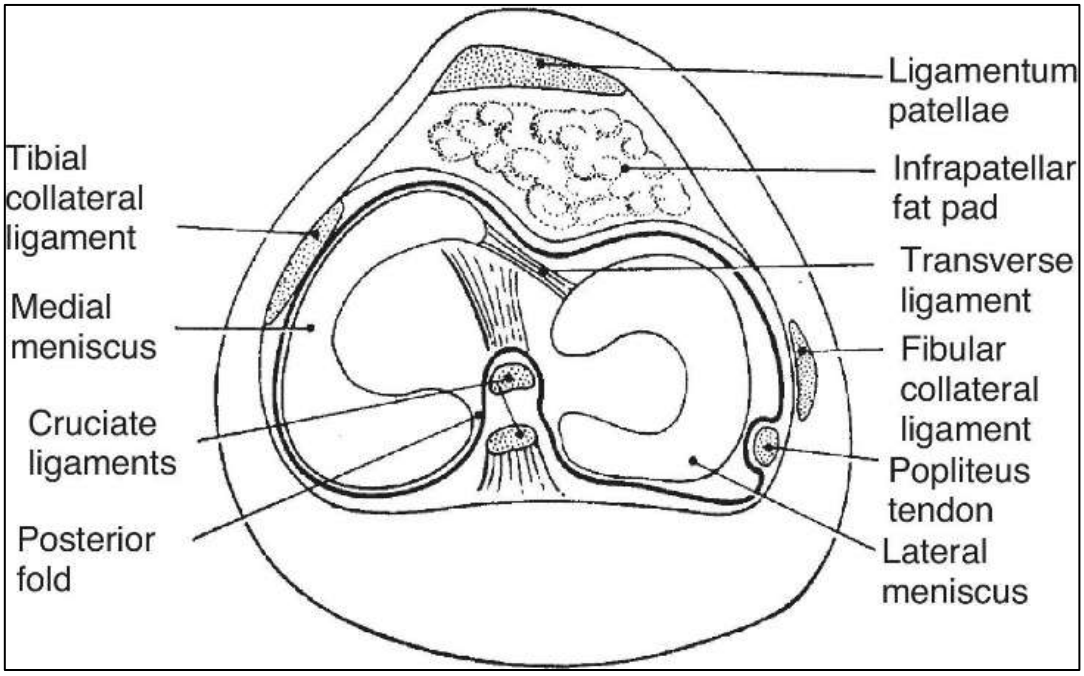

Single Best Response (SBR) questions.

(11) C

The infra orbital nerve lies in a groove that bulges down into the roof of the sinus.

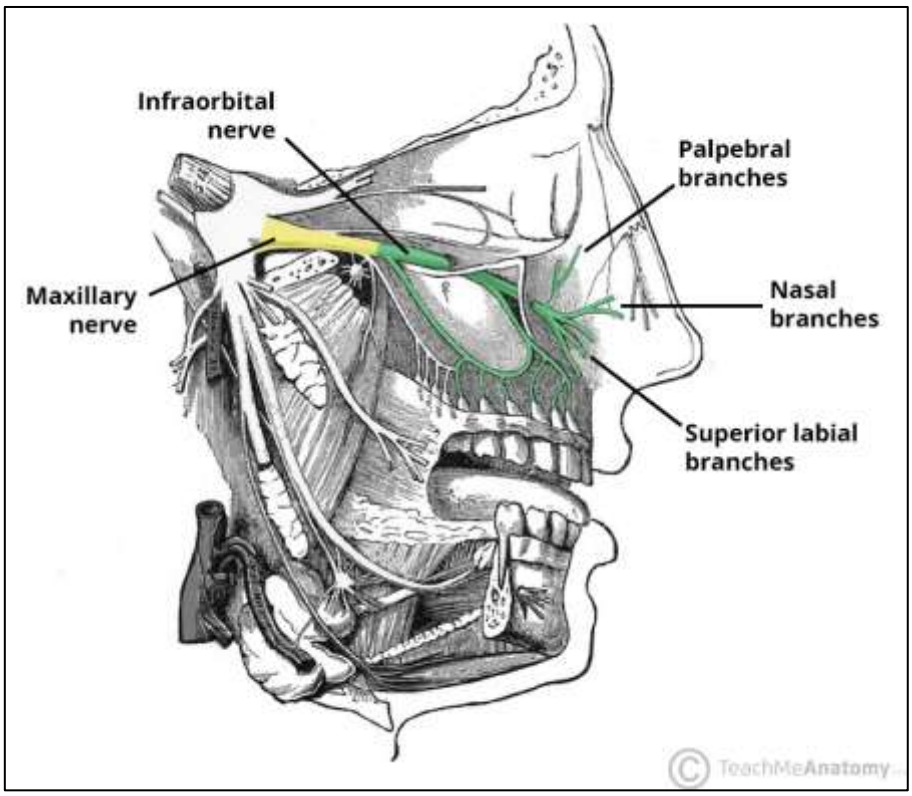

(12) B

The genioglossus muscle protrudes the tongue. Each genioglossus pushes the tongue forward and toward the opposite side. If the right genioglossus is paralyzed, the left side pushes unopposed → tongue deviates towards the right (same side lesion).

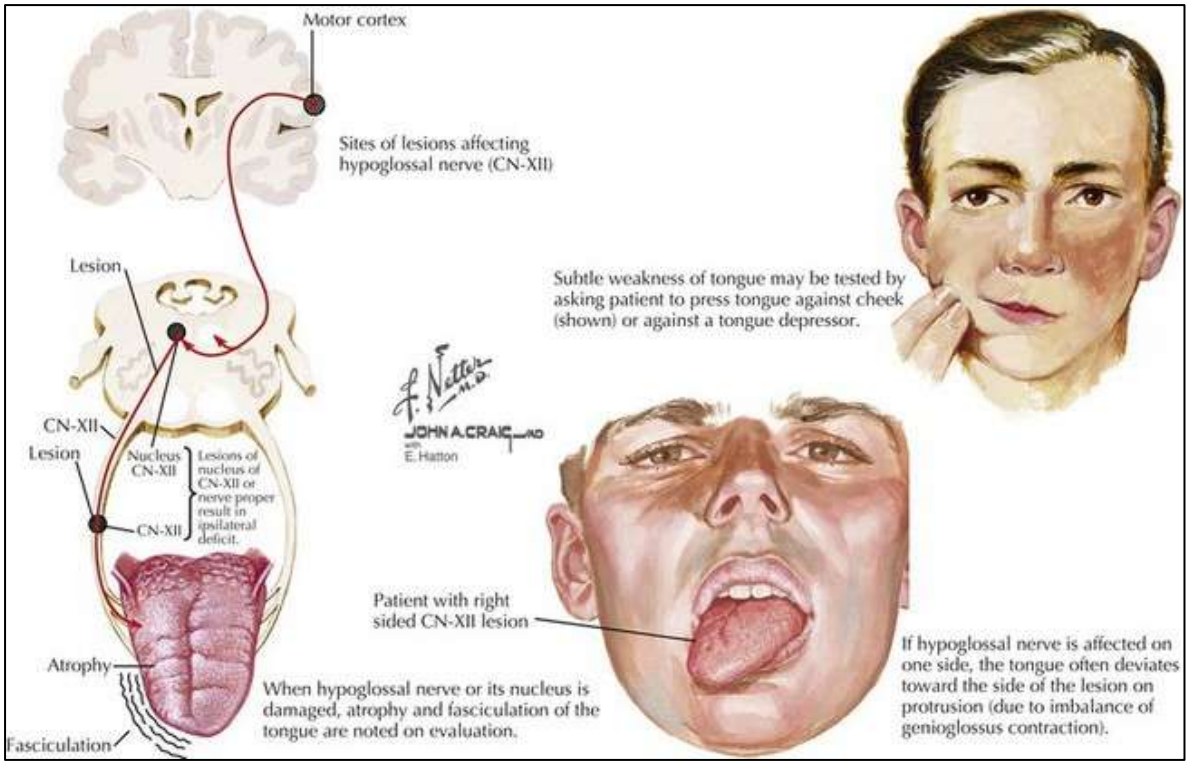

(13) B

Facial nerve paralysis with hearing loss suggests a lesion where both CN VII and CN VIII are affected together. These two nerves pass through the internal auditory meatus, so a lesion here can damage both. Therefore, the most likely site of injury is the internal auditory meatus.

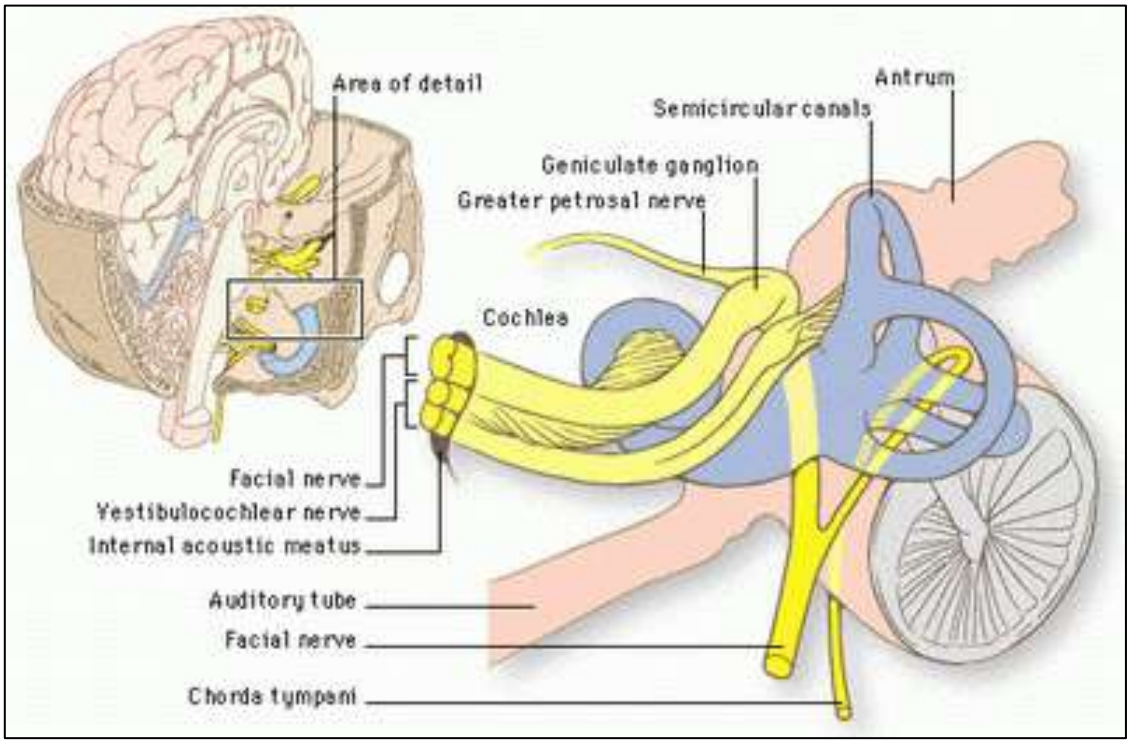

(14) B

Brainstem death is identified by the absence of **cranial nerve reflexes**, especially those mediated through the midbrain and medulla. The **pupillary light reflex** is the most reliable single indicator, as it directly tests midbrain function; the **gag reflex**, although brainstem-mediated, is excluded in SBA contexts because it can be variable or suppressed. Spinal reflexes such as the **Babinski sign**, cremasteric reflex, and knee jerk may persist and are not useful for diagnosing brainstem death.

(15) A

The cricothyroid muscle is supplied by the external laryngeal branch of the superior laryngeal nerve.

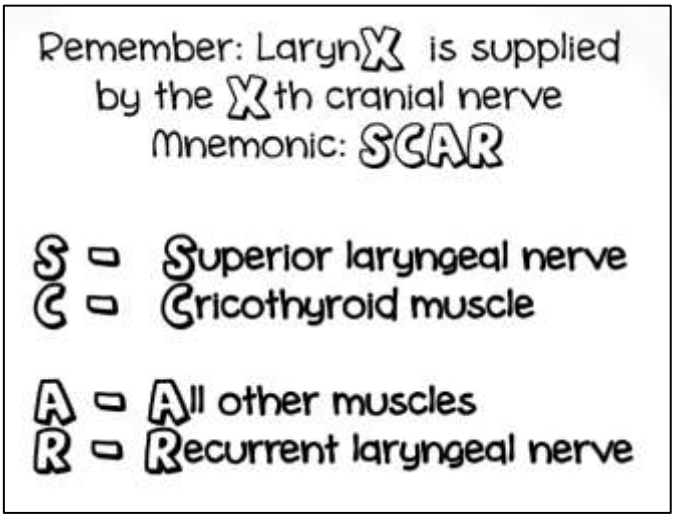

(16) C

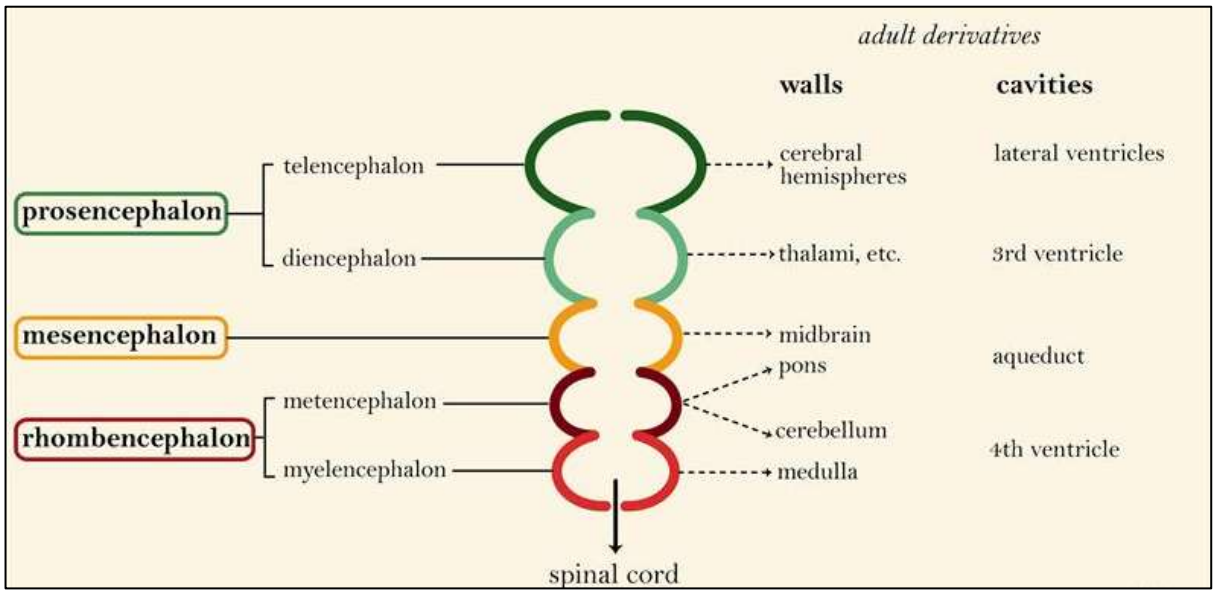

(17) B

The ventromedial nucleus is the satiety center of the hypothalamus.

- Lesion → hyperphagia (overeating) → weight gain
- The lateral nucleus acts as the hunger center (lesion → loss of appetite)

(18) C

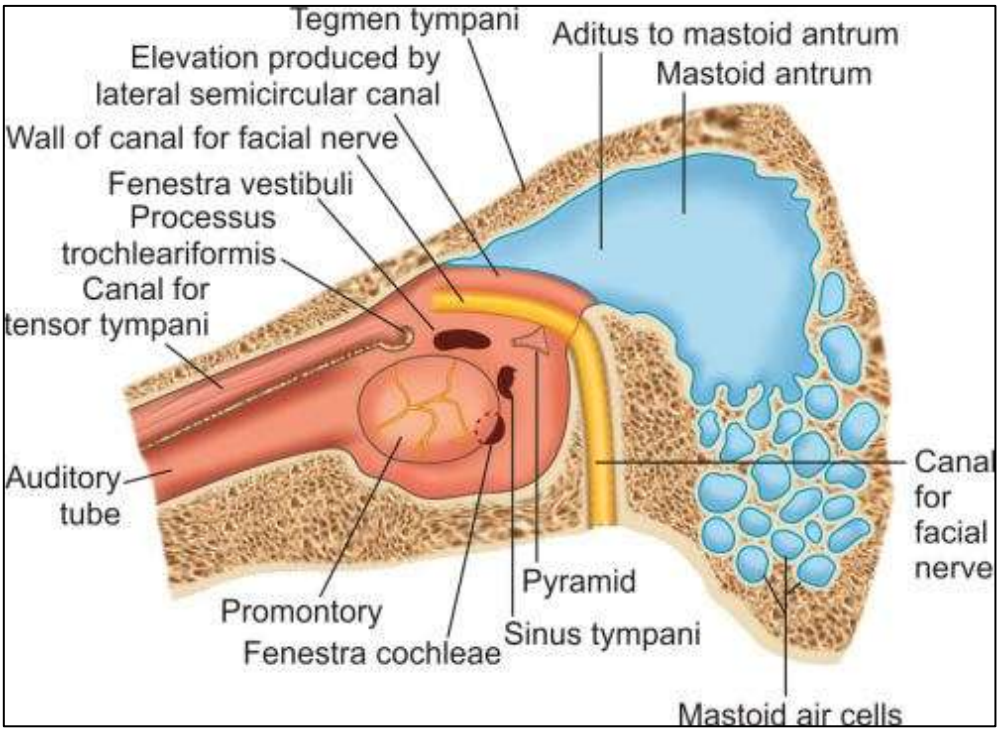

(19) D

The head of the femur is mainly supplied by retinacular arteries (branches of the medial circumflex femoral artery) that run along the neck of the femur.
A subcapital fracture occurs just below the head and disrupts these vessels most severely, cutting off blood supply, leading to avascular necrosis.
Other fractures (like intertrochanteric or subtrochanteric) are extracapsular and usually preserve the blood supply, so AVN is less common.

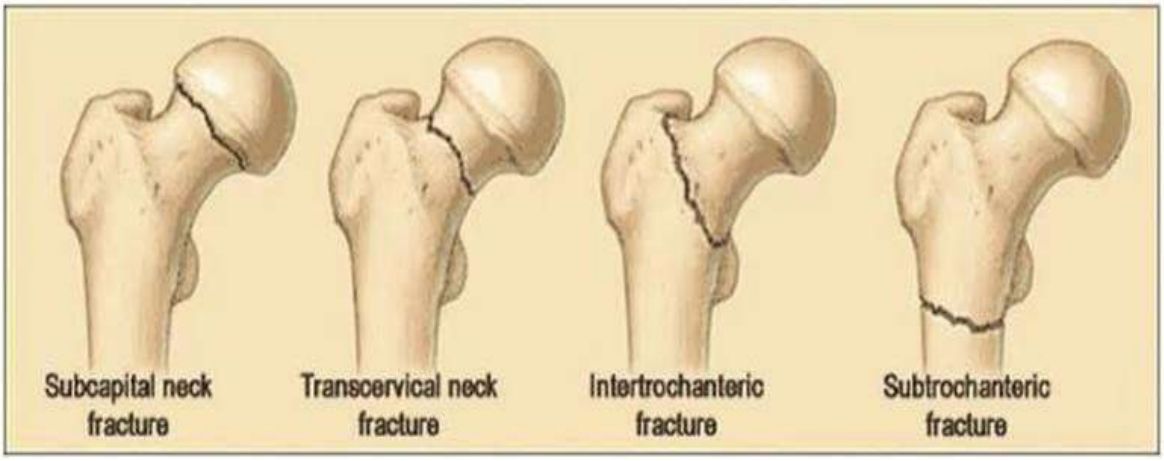

(20) E

The finding of excessive posterior movement of the tibia on the femur indicates injury to the posterior stabilizing structures of the knee joint, most importantly the posterior cruciate ligament.
This ligament normally prevents posterior displacement of the tibia, especially when the knee is flexed, as in a fall on a bent knee.
Damage to it classically produces posterior drawer instability, which matches the clinical presentation described.

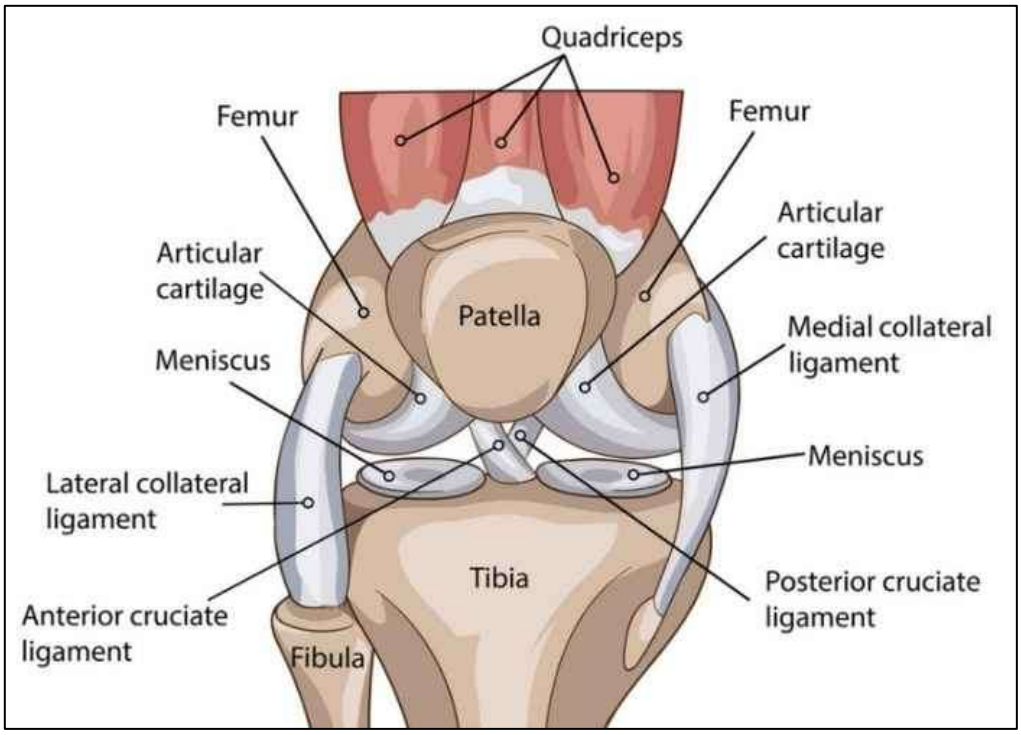

Batch 02 – CAT 03 - MOCK OSPE Paper

Time: 1 hour

(1)

(A) Identify the structure labelled as D.

(B) Mention its anatomical origin.

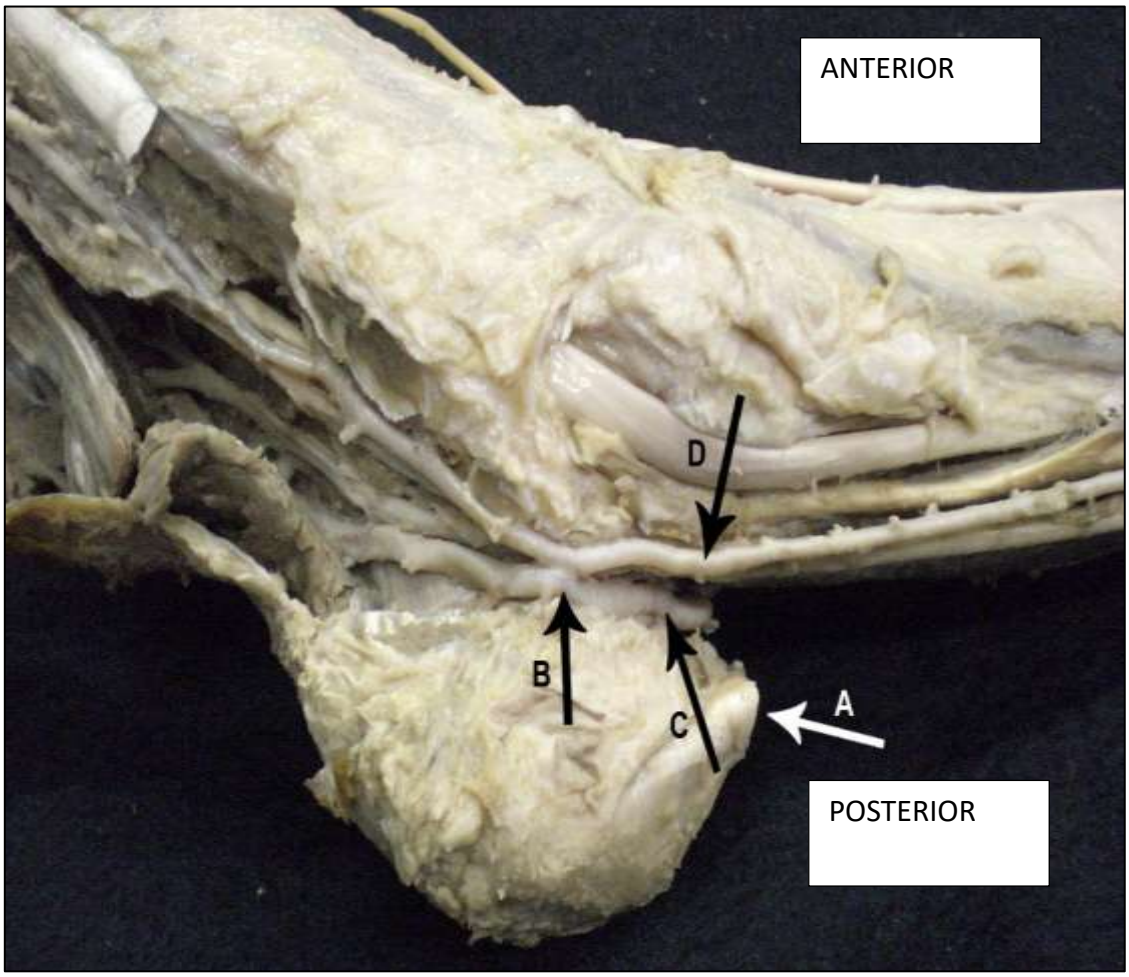

(2)

(A) Identify the structure rounded in black color.

(B) Mention a structure that passes through it.

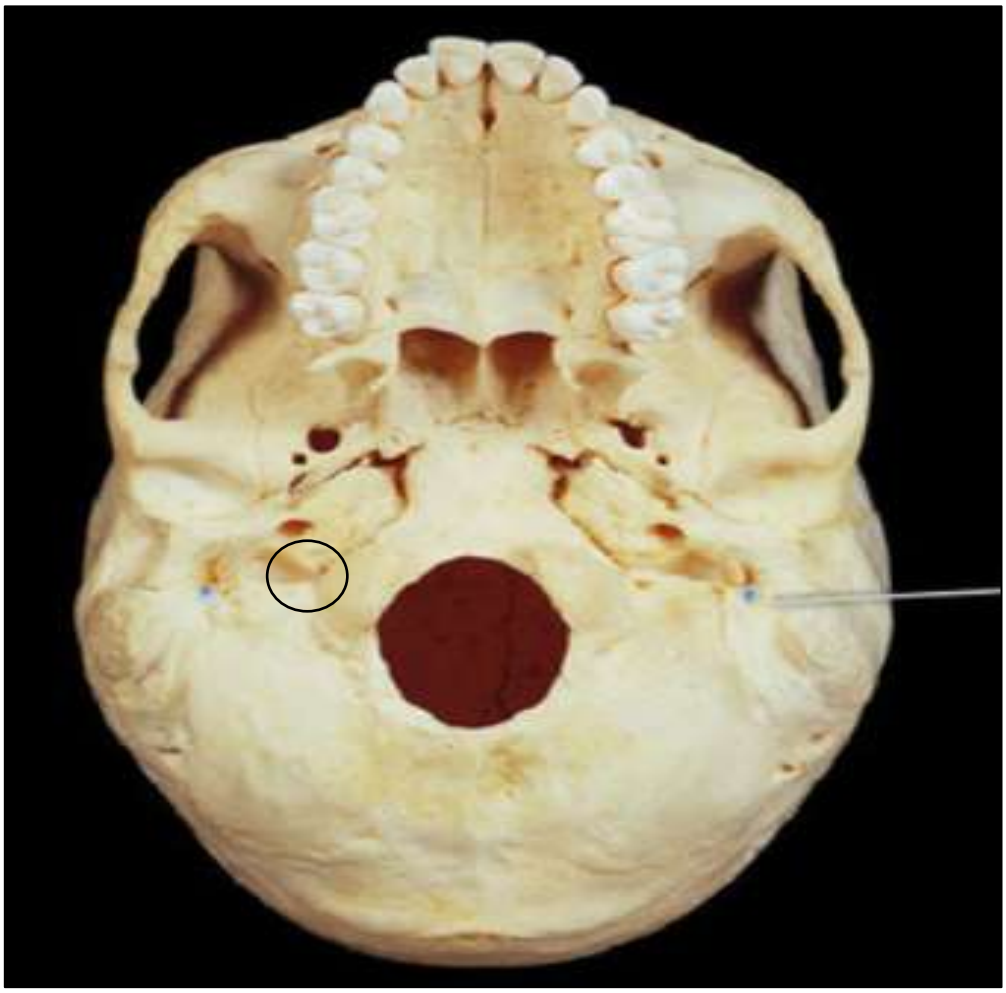

(3) A 60-year-old male patient presented with abnormal movements of left upper and lower limbs. CT/MRI shows a lesion marked by the black arrow.

(A) Identify the structure.

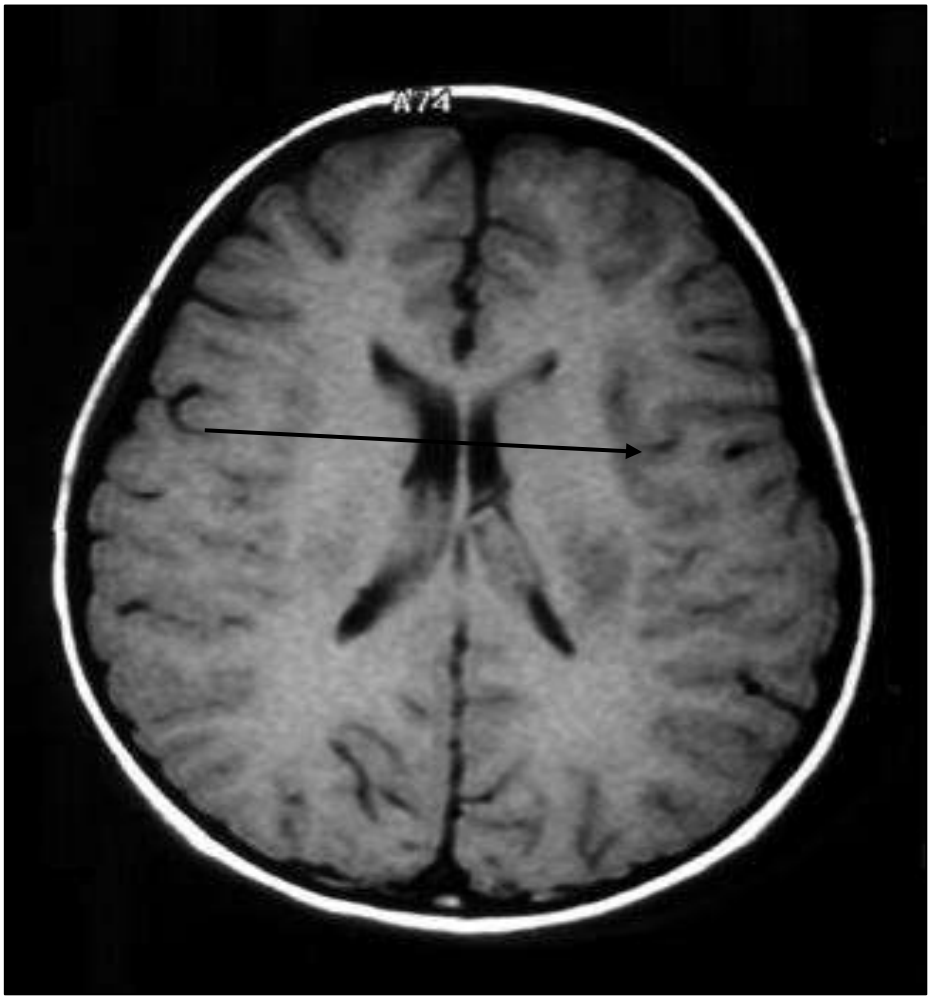

(4)

(A) Identify the bony prominence marked with black arrows.

(B) Name a structure attached to it.

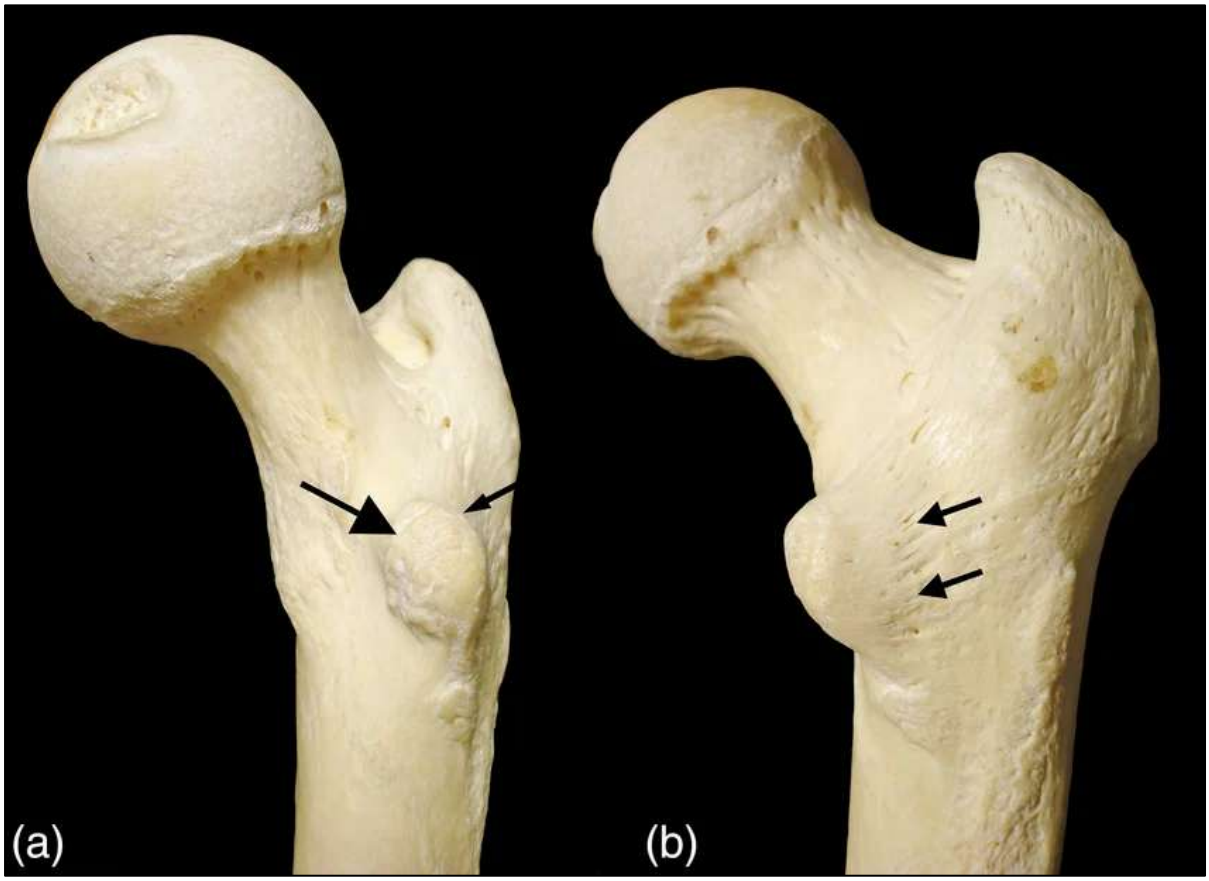

(5)

(A) Identify the space indicated by the pin.

(B) Name the structure that traverses this space.



(6) A 40-year-old male patient had a fracture of the acetabulum and posterior dislocation of the femoral head following a dashboard injury, damaging the indicated (black pin) structure.

(A) Identify the structure pierced by the pin.
(B) Mention one clinical feature of this injury



(7) A 33-year-old male patient was admitted following a severe head injury due to a motorcycle accident. He had pulsating proptosis and throat bleeding. A base of skull fracture was suspected, tearing this structure marked with the black arrow.

(A) Identify the structure.



(8) Identify the structure marked with the black arrow.

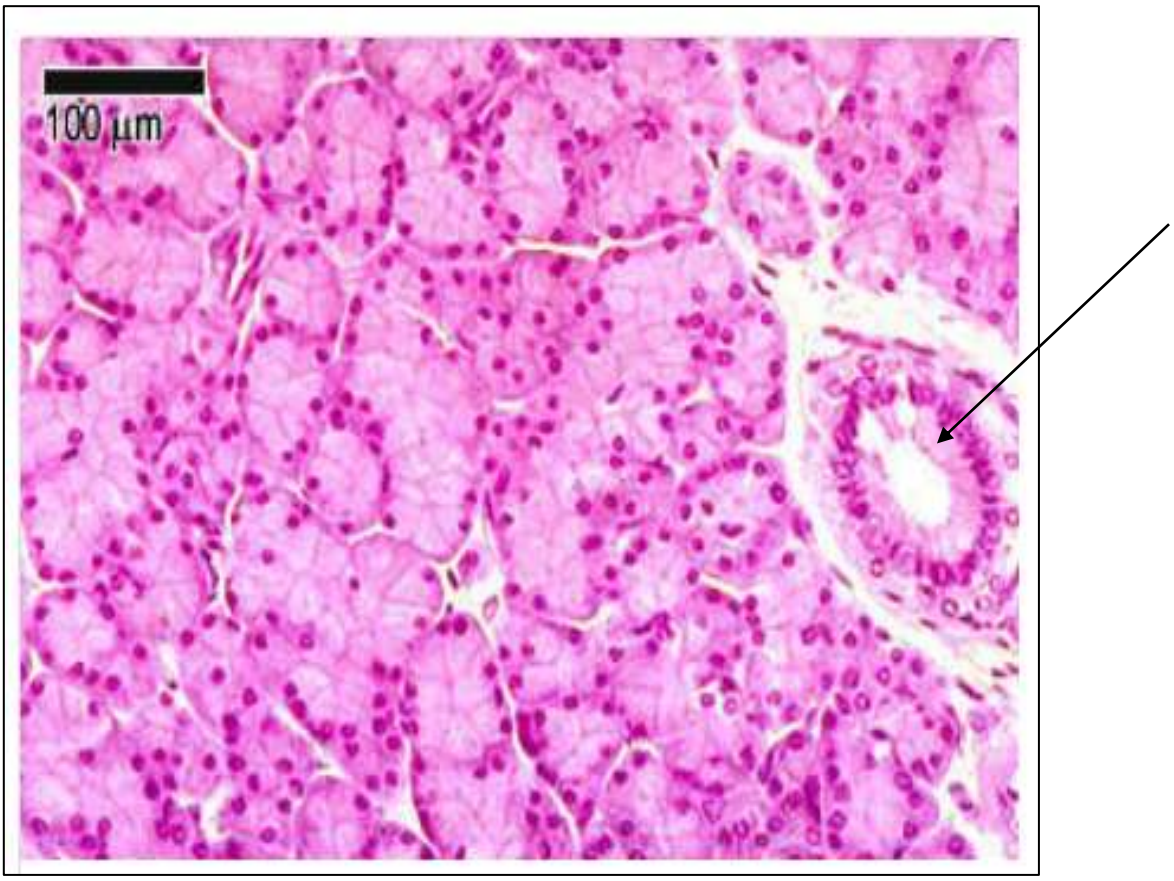

(9) Identify the structure.

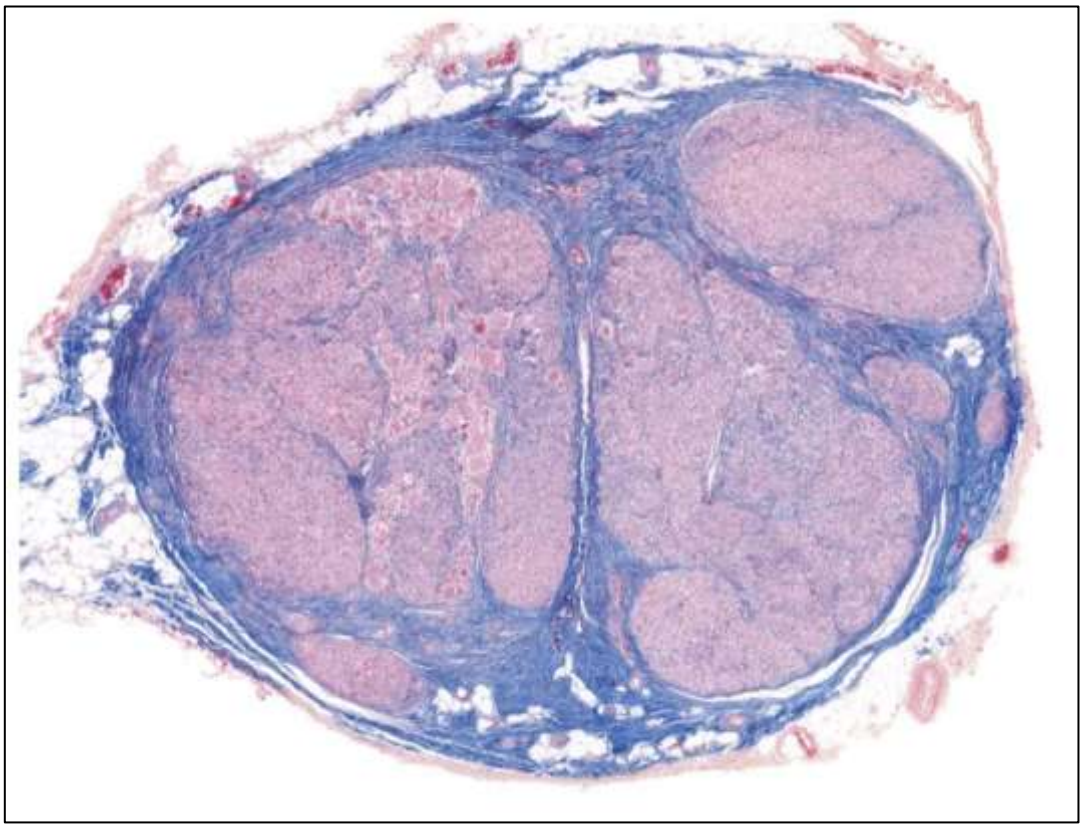

(10)

(A) Identify the muscle mentioned in black arrow.

(B) State its origin and insertion.

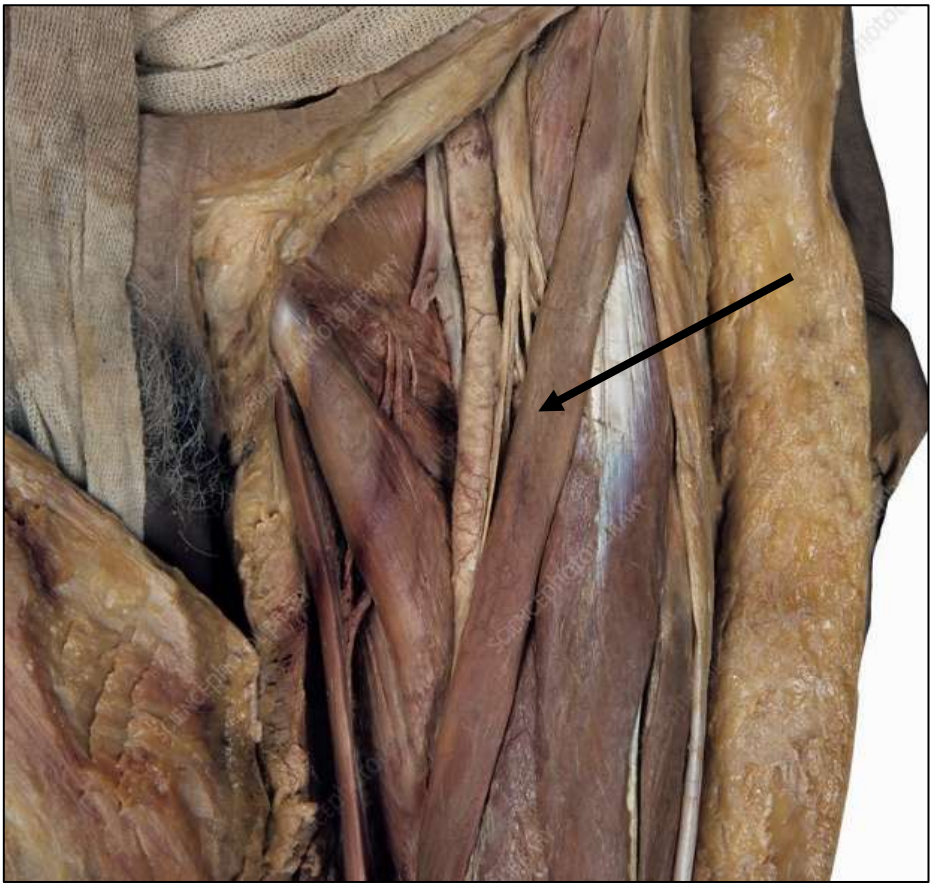

Batch 02 – CAT 03 - MOCK OSPE Paper Answers

(1) Posterior tibial artery is demonstrated

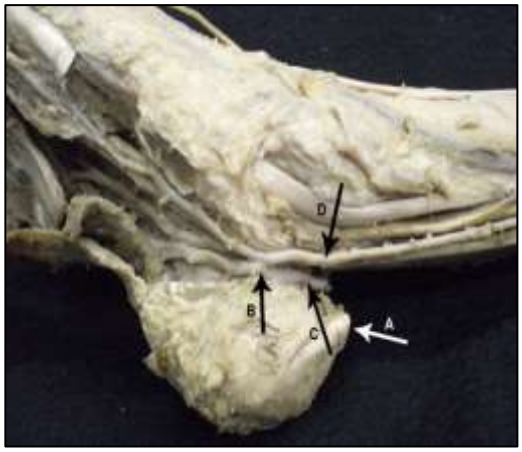

(A) Posterior tibial artery
(B) Popliteal artery

(2) Stylomastoid foramen is demonstrated.

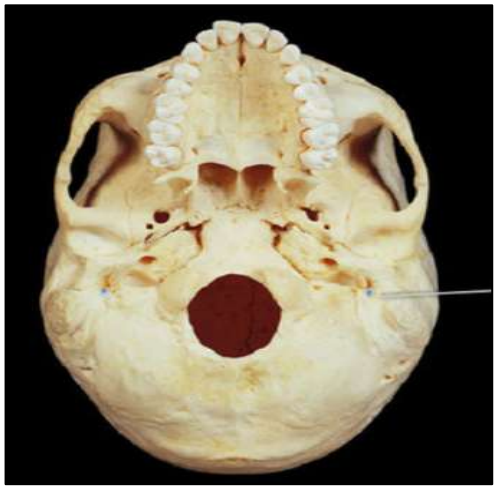

(A) Stylomastoid foramen
(B) Facial nerve

(3) CT/MRI brain is demonstrated with marked lentiform nucleus.

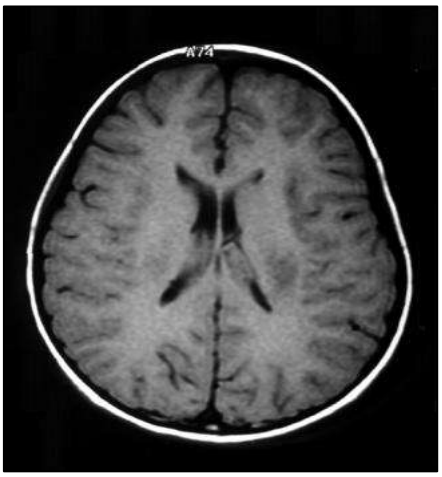

(A) lentiform nucleus

(4) Lesser trochanter is demonstrated.

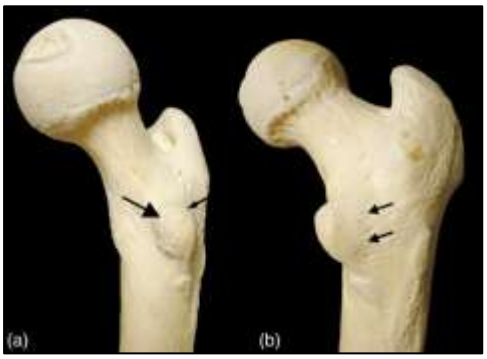

(A) Lesser trochanter
(B) Right Femur/ Illiacus Muscle/ Psoas Major,

(5) Transverse foramen is demonstrated.



(A) Transverse foramen
(B) Vertebral artery

(6) Sciatic nerve is demonstrated.



(A) Sciatic nerve
(B) Foot drop

(7) Internal carotid artery is demonstrated.



(A) Internal carotid artery

(8) Parotid gland/ Parotid duct

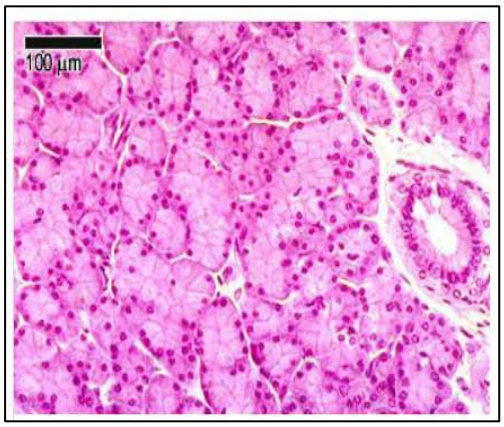

(9) Dorsal root ganglion

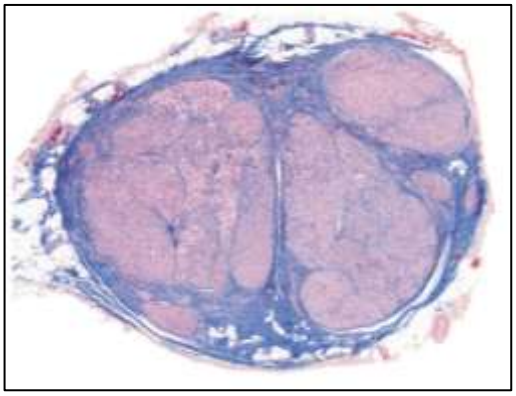

(10) Sartorius muscle is indicated.



(A) Sartorius muscle

(B) Origin: Anterior superior iliac spine (ASIS)

Insertion**:** Upper medial surface of tibia (via pes anserinus)

CONTINUOUS ASSESSMENT (CAT) – 03 PAPERS WITH ANSWERS

(1) Batch 01

(2) Batch 02

Batch 01 – CAT 03 (2025) – MCQ Paper

UVA WELLASSA UNIVERSITY OF SRI LANKA
FACULTY OF MEDICINE
Continuous Assessment 03
August 2025
2022/2023 (1st) Batch Anatomy
Multiple Choice Questions (MCQ) Paper

Time 10.00 am – 11.00 am (01 hour) Date of the exam 2025.08.15

Please do not attempt or promote copying. No textbooks, notes, mobile phones, smart watches, or any other electronic communication devices are allowed.

Please read the following instructions before marking responses on your answer sheets

1. Check that your question paper has a total of **06 pages,** including the front page.
2. **A single answer sheet is provided**. Please write your index number in the given space.
3. Read each question carefully before answering.
4. Mark the correct response as a **heavy black mark, filling the relevant circle completely**, using a **black lead pencil (6B or above grade).**
5. Do not make stray marks on the answer sheet. In case of an error, erase cleanly.
6. Your final answer should be a densely coloured circle through which the underlying letter is not visible.
7. Marking using any other method (e.g., mark the circle with a cross) is not valid.

Ten (10) True/False Type Questions (Questions 1-10/Page 2-3)

1. Mark whether each response is true or false.
2. Given below is an example of how to mark a true/false type question.

Q 11. A woman has
A. One ovary.
B. One nose.
C. Two ears.
D. One eye.
E. Two hairs.

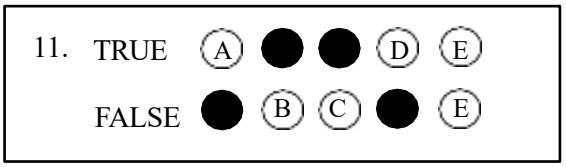

A correct response will get = +1 mark
An incorrect response will get = -1 mark
No response will get = 0 (zero) mark
Negative marks will not be carried over to the next question

Ten (10) Single Best Response (SBR) Type Questions (Questions 11-20/ Page 4-6)

1. Mark the best response. Only one response per question should be marked.
2. If you mark the correct response, you will get the full marks for the question.
3. If you mark an incorrect response, fail to mark any response, select more than one response, or mark your response unclearly, you will not receive any marks for that question.
4. Given below is an example of how to mark a single best response type question.

Q 16. Speaking is a unique ability observed in humans. Which of the following body parts is primarily used for speech production?
A. Tongue
B. Hands
C. Feet
D. Ears
E. Nose

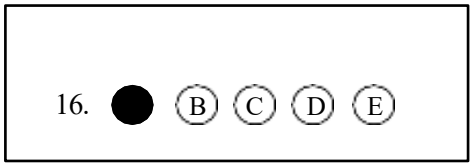

Question numbers 01 to 10 are True or False type questions. Mark your answer for each of the 5 responses (A to E).

(1) True/ False regarding ossicles of the middle ear?

A. All three ossicles are located in the inner ear.
B. The incus articulates with both the malleus and stapes.
C. The malleus is attached to the tympanic membrane.
D. The ossicles amplify sound vibrations.
E. The stapes footplate fits into the round window.

(2) True/ False regarding the vocal cords and glottis?

A. The false vocal cords are superior to the true vocal cords.
B. The length and tension of the vocal cords affect pitch.
C. The space between the vocal cords is called the rima glottidis.
D. The true vocal cords are also known as vocal folds.
E. The vocal cords are covered with respiratory epithelium.

(3) True/ False regarding the scalenus anterior muscle?

A. It is attached to the anteriör tubercles of typical cervical vertebrae.
B. It is inserted to the scalene tubercle of the second rib.
C. It Separates the subclavian artery from the subclavian vein.
D. Phrenic nerve passes anterior to it.
E. Trunks of the brachial plexus emerge from the lateral border.

(4) True/ False regarding surface anatomy of lower limb blood vessels?

A. Dorsalis pedis pulse can be felt, lateral to the extensor hallucis longus tendon.
B. Femoral pulse can be felt at the midinguinal point.
C. Great saphenous vein is anterior to the medial malleolus.
D. Posterior tibial pulse can be felt posterior to the lateral malleolus.
E. Small saphenous vein is posterior to the lateral malleolus.

(5) True/ False regarding the Oculomotor nerve?

A. It can be compressed by an aneurysm of posterior communicating artery.
B. It can be compressed by the uncus in large intracranial space occupying lesion.
C. It carries motor fibers to lateral rectus muscle.
D. It carries parasympathetic fibers to constrictor pupillae muscle.
E. It exits through the midbrain.

(6) True/ False regarding parotid gland?

A. It is a purely mucous gland.
B. It lies entirely superficial to the masseter muscle.
C. It receives parasympathetic innervation from the facial nerve directly.
D. The facial nerve passes through the gland but does not innervate it.
E. E. The parotid duct opens opposite the upper second molar tooth.

(7) True/ False regarding the anatomy of the knee joint?

A. The anterior cruciate ligament (ACL) prevents anterior displacement of the tibia on the femur.
B. The fibular (lateral) collateral ligament is firmly attached to the lateral meniscus.
C. The knee joint is a synovial hinge joint with slight rotational movement.
D. The medial meniscus is more mobile than the lateral meniscus.
E. The synovial membrane of the knee joint lines the articular surfaces of the femur and tibia.

(8) True/ False regarding the ascending (sensory) tracts of the spinal cord?

A. First-order neurons of the dorsal column pathway synapse in the spinal cord gray matter.
B. The dorsal column-medial lemniscus pathway carries fine touch, vibration, and proprioception.
C. The gracile fasciculus carries information from the upper limbs and trunk.
D. The spinocerebellar tracts are responsible for unconscious proprioception.
E. The spinothalamic tract conveys pain and temperature sensations.

(9) True/ False regarding the cross-sectional anatomy of medulla oblongata?

A. Most of the corticospinal fibers cross to form the lateral corticospinal tract.
B. The anterior median fissure is visible in cross-section at this level.
C. The nucleus gracilis and nucleus cuneatus are located anterior to the central canal.
D. The pyramidal decussation occurs in the lower part of the medulla oblongata.
E. The spinothalamic tract lies in the posterior funiculus of the spinal cord,

(10) True/ False regarding the primary Motor and Sensory Cortices?

A. Lesion of the precentral gyrus causes contralateral motor weakness.
B. The motor homunculus shows the head represented medially and the lower limb laterally.
C. The primary motor cortex is located in the precentral gyrus of the frontal lobe.
D. The primary somatosensory cortex is located in the postcentral gyrus.
E. The somatosensory cortex receives input from the dorsal column-medial lemniscus and spinothalamic pathways.

Questions number 11 to 20 are Single Best Response (SBR) type. Select the best response to each question.

(11) A 75-year-old woman presented after a fall at home. She is unable to bear weight on her left leg, and her left lower limb is shortened and externally rotated. X-ray confirms an intracapsular fracture of the femoral neck.
Which of the following arteries is most responsible for supplying the femoral head in adults and is at risk in this injury?

A. Obturator artery — artery to the ligamentum teres
B. Inferior gluteal artery
C. Superior gluteal artery
D. Medial circumflex femoral artery
E. Lateral circumflex femoral artery

(12) A 24-year-old male presented to the emergency department after a motorcycle accident. He reported being unable to dorsiflex his foot, and on examination, his foot is plantarflexed and inverted. He also has loss of sensation over the dorsum of the foot and the lateral aspect of his leg.
Which of the following nerves is most likely injured?

A. Common peroneal (fibular) nerve
B. Deep peroneal (fibular) nerve
C. Saphenous nerve
D. Superficial peroneal (fibular) nerve
E. Tibial nerve

(13) A 42-year-old woman presented with a painful, swollen left leg, especially in the calf region. She recently returned from a long international flight. On examination, her left leg is warm, swollen, and tender to palpation in the posterior calf. Doppler ultrasound confirms a deep vein thrombosis (DVT).
Which of the following veins is most likely the site of thrombosis in this patient?

A. Great saphenous vein
B. Small saphenous vein
C. Femoral vein
D. Popliteal vein
E. Dorsal venous arch

(14) A 50-year-old man underwent thyroidectomy for a multinodular goiter. During surgery, the surgeon ligated the superior thyroid artery close to the thyroid gland to reduce bleeding. Postoperatively, the patient experienced difficulty in modulating his voice pitch but no hoarseness.

Which of the following nerves was most likely affected during the surgery?

A. External branch of the superior laryngeal nerve
B. Glossopharyngeal nerve
C. Internal branch of superior laryngeal nerve
D. Non recurrent inferior laryngeal nerve
E. Recurrent laryngeal nerve

(15) A 19-year-old male was brought to the emergency department after being struck on the side of the head with a cricket bat. He was briefly unconscious, then lucid, but later collapsed. CT shows a biconvex (lens-shaped) hyperdense lesion in the temporo-parietal region.

Which vessel is most likely injured?

A. Bridging veins
B. Internal carotid artery
C. Middle meningeal artery
D. Posterior cerebral artery
E. Superior sagittal sinus

(16) A 58-year-old man presented with a painless, hard mass in the left upper deep cervical region. He has also experienced persistent hoarseness and a sore throat for 3 months. On examination, there is a firm lymph node just anterior to the upper third of the sternocleidomastoid muscle. Flexible laryngoscopy reveals a suspicious lesion on the left side of the larynx, just above the vocal cords.

Which group of lymph nodes is most likely involved in draining this primary lesion?

A. Deep cervical lymph nodes
B. Prelaryngeal (Delphian) nodes
C. Retropharyngeal lymph nodes
D. Submental lymph nodes
E. Supraclavicular lymph nodes

(17) A 45-year-old man presented with recurrent right-sided nasal obstruction, facial pressure, and a thick nasal discharge. Nasal endoscopy reveals pus draining from a foramen of the lateral wall of the nose. A CT scan confirms maxillary sinusitis.

Through which of the following openings does the maxillary sinus drain into the nasal cavity?

A. Inferior meatus
B. Middle meatus
C. Nasolacrimal duct
D. Spheno-ethmoidal recess
E. Superior meatus

(18) A 40-year-old man presented with double vision, drooping of the right eyelid, and numbness over the forehead and upper eyelid. On examination, he has ptosis, a dilated pupil, and is unable to move his right eye medially, upward, or downward. Sensory loss is noted in the ophthalmic division of the trigeminal nerve. MRI brain reveals a mass compressing the lateral wall of the right cavernous sinus.
Which of the following cranial nerves is NOT located within the lateral wall of the cavernous sinus?

A. Abducens nerve (CN VI)
B. Maxillary nerve (V2)
C. Oculomotor nerve (CN Ill)
D. Ophthalmic nerve (VI)
E. Trochlear nerve (CN IV)

(19) A 68-year-old right-handed man was brought to the emergency department with sudden onset of weakness in his right lower limb and difficulty initiating speech. He is alert, with intact upper limb strength and facial movements.
Imaging confirms an ischemic stroke. Which artery is most likely occluded?

A. Anterior cerebral artery
B. Anterior choroidal artery
C. Basilar artery
D. Middle cerebral artery
E. Posterior cerebral artery

(20) A 70-year-old man presented with sudden-onset left-sided hemiplegia and hemianesthesia affecting the face, arm, and leg equally. There is also a left-sided lower facial droop, but forehead movement is spared. A CT scan confirms a small lacunar infarct in the right internal capsule.
Which part of the internal capsule is most likely affected?

A. Anterior limb
B. Genu
C. Posterior limb
D. Retrolentiform part
E. Sublentiform part

Batch 01 - CAT 03 (2025) – MCQ Paper Answers

(1)	F	T	T	T	F
(2)	T	T	T	T	F
(3)	T	F	T	T	T
(4)	T	T	T	T	T
(5)	T	T	F	T	T
(6)	F	F	F	T	T
(7)	T	F	T	F	F
(8)	F	T	F	T	T
(9)	T	T	F	T	F
(10)	T	F	T	T	T
(11)	D				
(12)	A				
(13)	D				
(14)	A				
(15)	C				
(16)	A				
(17)	B				
(18)	A				
(19)	A				
(20)	C				

Batch 01 – CAT 03 (2025)– OSPE Paper

Time - 01 hour

(1) Pterion of the skull is demonstrated.

Q. A 22-year-old man admitted following an assault to head. He was confused and X ray of the skull showed linear fracture involving the marked region,

(A) Identify the region.
(B) What is the important anatomical structure related to its deep aspect.

(2) Histology - Pancreatic tissue is demonstrated.

(A) Identify the tissue presented in microscope.
(B) Identify the structure pointed.

(3) Lesser Trochanter of Right Femur is demonstrated.

(A) Identify the bony prominence marked.
(B) Name a structure attached to it

(4) Histology - Submandibular gland.is demonstrated.

Q. A 75-year-old male presented with an anterior neck lump presented with a lesion in the tissue depicted.

(A) Identify the tissue
(B) Identify precisely the structure pointed

(5) Right Lentiform Nucleus in a CT brain is demonstrated.

Q. 60-year-old male patient was presented with abnormal spontaneous movements of the left leg.

(A) Identify the structure

(6) Cauda Equina is demonstrated.

Q. 30-year-old male patient presented with acute severe back pain and bilateral lower limb pain with numbness of buttocks, acute retention of urine following lifting a heavy weight. MRI revealed L4-L5 central disc prolapse compressing the indicated structure.

(A) Identify the structure marked

(7) Histology - Thyroid Gland is demonstrated.

Q. A 55-year-old female patient presented with neck lump. Histopathology revealed a carcinoma in presented tissue

(A) Identify the tissue

(8) Histology - Appendix,is demonstrated.

(A) Identify the tissue
(B) State a special feature in that tissue

(9) Anterior Cruciate Ligamenti s demonstrated.

(A) Identify the structure pierced by pin.

(10) Sural nerve is demonstrated.

Q. A 60-year-old patient was admitted with anaesthetic hypopigmented skin patches. Leprosy was suspected and planned to do a nerve biopsy from this nerve.

(A) Identify the structure pierced by pin.

(11) Common Carotid Artery is demonstrated.

Q. A-55-year man with history of diabetes and hypertension admitted following frequent episodes of left side weakness.
He had narrowing of this vessel due an atheroma.

(A) Identify the structure.

(12) Internal Carotid Artery is demonstrated.

Q. A 33-year-old patient was admitted following a severe head injury due to a motor bike accident. He had pulsating proptosis and throat bleeding,
A base of skull fracture was suspected tearing this vessel.

(A) Identify the vessel.

(13) Posterior Tibia/ Artery is demonstrated.

Q. A 60-year-old male patient with a history of prolonged smoking presented with pain in both calves while walking about 50 meters.
Examination revealed reduced pulse volume of this artery.

(A) Identify the artery

(14) Third Ventricle is demonstrated.

Q. A 22-year-old patient presented with acute onset headache, vomiting, blurred vision followed by loss of consciousness. Urgent CT brain revealed a lesion here,

(A) Identify the structure pierced by pin.

(15) Recurrent Laryngeal Nerve is demonstrated.

Q. A 45-year-old female patient had hoarseness of voice following thyroidectomy, Intraoperatively, a structure was severed during dissection due to involvement by the thyroid cancer

(A) Identify the structure

Batch 01 – CAT 03 (2025) – OSPE Paper Answers

(1)

(A) Pterion of the skull
(B) Middle Meningeal Artery

(2)

(A) Pancreatic tissue
(B) Islets of Langerhans

(3)

(A) Lesser Trochanter of Right Femur
(B) Illiacus Muscle, Psoas Major,

(4)

(A) Submandibular gland
(B) Serous demilunes

(5)

(A) Right Lentiform Nucleus (Putamen/Globus Pallidus)

(6)

(A) Cauda Equina

(7)

(A) Thyroid Gland

(8)

(A) Appendix
(B) Payers Patches

(9)

(A) Anterior Cruciate Ligament

(10)

(A) Sural

(11)

(A) Common Carotid Artery

(12)

(A) Internal Carotid Artery

(13)

(A) Posterior Tibia/ Artery

(14)

(A) Third Ventricle

(15)

(A) Recurrent Laryngeal Nerve

Batch 02 – CAT 03 (2026) – MCQ Paper

UVA WELLASSA UNIVERSITY OF SRI LANKA
FACULTY OF MEDICINE
Continuous Assessment 03
May 2026
2023/2024 (02nd) Batch Anatomy
Multiple Choice Questions (MCQ) Paper

Time 10.00 am – 11.00 am (01 hour) Date of the exam: 2026.05.18

Please do not attempt or promote copying. No textbooks, notes, mobile phones, smart watches, or any other electronic communication devices are allowed.

Please read the following instructions before marking responses on your answer sheets

1. Check that your question paper has a total of **06 pages,** including the front page.
2. **A single answer sheet is provided**. Please write your index number in the given space.
3. Read each question carefully before answering.
4. Mark the correct response as a **heavy black mark, filling the relevant circle completely**, using a **black lead pencil (6B or above grade).**
5. Do not make stray marks on the answer sheet. In case of an error, erase cleanly.
6. Your final answer should be a densely coloured circle through which the underlying letter is not visible.
7. Marking using any other method (e.g., mark the circle with a cross) is not valid.

Ten (10) True/False Type Questions (Questions 1-10/Page 2-3)

1. Mark whether each response is true or false.
2. Given below is an example of how to mark a true/false type question.

Q 11. A woman has
- A. One ovary.
- B. One nose.
- C. Two ears.
- D. One eye.
- E. Two hairs.

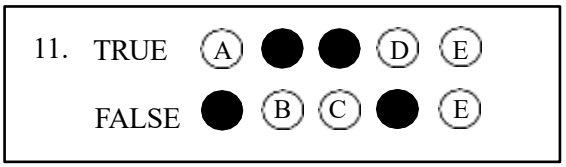

A correct response will get = +1 mark
An incorrect response will get = -1 mark
No response will get = 0 (zero) mark
Negative marks will not be carried over to the next question

Ten (10) Single Best Response (SBR) Type Questions (Questions 11-20/ Page 4-6)

1. Mark the best response. Only one response per question should be marked.
2. If you mark the correct response, you will get the full marks for the question.
3. If you mark an incorrect response, fail to mark any response, select more than one response, or mark your response unclearly, you will not receive any marks for that question.
4. Given below is an example of how to mark a single best response type question.

Q 16. Speaking is a unique ability observed in humans. Which of the following body parts is primarily used for speech production?
- A. Tongue
- B. Hands
- C. Feet
- D. Ears
- E. Nose

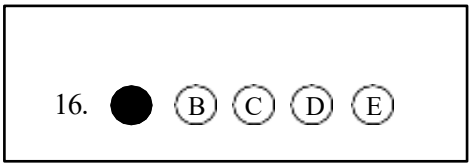

Question numbers 01 to 10 are True or False type questions. Mark your answer for each of the five responses (A to E).

(1) True or False regarding cervical spine and neck movements?

(A) Contraction of sternocleidomastoid rotates the head to opposite side.
(B) Flexion of the neck is mainly by splenius capitis.
(C) Rotation of the head occurs mainly at the atlanto-occipital joint.
(D) The dens articulate with the anterior arch of atlas.
(E) Vertebral artery passes through all cervical transverse foramina.

(2) True or False regarding vasculature of head and neck?

(A) Facial vein has no valves.
(B) Internal jugular vein lies medial to the carotid artery.
(C) Lingual artery arises from the external carotid artery.
(D) The external jugular vein is formed by anterior jugular vein and facial vein.
(E) Thoracic duct drains into right venous angle.

(3) True or False regarding nose and paranasal sinuses?

(A) Frontal sinus drains into middle meatus.
(B) Inferior turbinate is part of ethmoid bone.
(C) Kiesselbach's plexus is a common site of epistaxis.
(D) Maxillary sinus drains into superior meatus.
(E) Olfactory epithelium is located in superior nasal concha.

(4) True or False regarding tongue?

(A) Hypoglossal nerve supplies palatoglossus muscle.
(B) It is deviated to opposite side on protrusion following hypoglossal nerve damage.
(C) It is supplied by lingual artery.
(D) Taste sensation of the anterior part is carried via glossopharyngeal nerve.
(E) Vallate papillae lie anterior to sulcus terminalis.

(5) True or False regarding orbital wall?

(A) The lateral wall is the thinnest wall of the orbit.
(B) The maxilla contributes to the floor of the orbit.
(C) The medial wall of the orbit is formed mainly by the ethmoid bone.
(D) The orbital roof is formed by the frontal bone.
(E) The sphenoid bone contributes to the apex of the orbit.

(6) True or False regarding muscles of mastication?

(A) Lateral pterygoid elevates the mandible.
(B) Lateral pterygoid helps in opening the mouth.
(C) Masseter elevates the mandible.
(D) Medial pterygoid assists in protrusion.
(E) Temporalis assists in retraction of the mandible.

(7) True or False regarding cerebral ventricular system?

(A) CSF flows from third ventricle to lateral ventricles.
(B) The cerebral aqueduct lies in the pons.
(C) The Foramen of Magendie is located at the lateral recess of the fourth ventricle.
(D) Third ventricle communicates with lateral ventricles via interventricular foramina.
(E) Third ventricle communicates with the fourth ventricle via cerebral aqueduct.

(8) True or False regarding oculomotor nerve?

(A) External compression of the nerve causes pupillary constriction.
(B) It contains General Visceral Efferent (GVE) fibers.
(C) It enters the orbit through the optic canal.
(D) It passes between posterior cerebral artery and superior cerebellar artery.
(E) Its nuclei are located at the level of the facial colliculus.

(9) True or False regarding femoral triangle?

(A) The femoral artery is positioned between the femoral nerve and the femoral vein.
(B) The femoral nerve lies within the femoral sheath.
(C) The floor is composed of the iliopsoas, pectineus, and adductor longus muscles.
(D) The medial border is formed by the lateral margin of the adductor longus muscle.
(E) The sartorius muscle forms the lateral boundary.

(10) True or False regarding ankle joint?

(A) Dorsiflexion is the most stable position of the ankle joint.
(B) It allows inversion and eversion.
(C) It is a hinge-type synovial joint.
(D) The anterior talofibular ligament is injured in eversion type injury.
(E) The medial (deltoid) ligament is stronger than the lateral ligament.

Question numbers 11 to 20 are Single Best Response (SBR) type. Select the best response for each question.

(11) A 48-year-old patient undergoes a deep-lobe parotidectomy to remove a pleomorphic adenoma. During the dissection, the surgeon identifies the structures passing through the gland to ensure they are preserved.
Which of the following best describes the correct relationship of these structures from superficial to deep within the substance of the parotid gland?

(A) External carotid artery, Retromandibular vein, Facial nerve
(B) Facial nerve, External carotid artery, Retromandibular vein
(C) Facial nerve, Retromandibular vein, External carotid artery
(D) Retromandibular vein, External carotid artery, Facial nerve
(E) Retromandibular vein, Facial nerve, External carotid artery

(12) A patient with a tumor in the jugular foramen exhibits loss of taste on the posterior 1/3 of the tongue and absent gag reflex.
Which cranial nerve (CN) is most likely affected?

(A) Accessory Nerve (CN XI)
(B) Facial Nerve (CN VII)
(C) Glossopharyngeal Nerve (CN IX)
(D) Hypoglossal Nerve (CN XII)
(E) Vagus Nerve (CN X)

(13) A 22-year-old man accidentally inhales a small piece of a peanut while eating. The peanut lodges in the subglottic (infraglottic) space, just inferior to the vocal folds. He immediately begins coughing violently.
Which of the following nerves is primarily responsible for carrying the sensory information from the mucosa where the peanut is lodged?

(A) External laryngeal nerve
(B) Glossopharyngeal nerve
(C) Internal laryngeal nerve
(D) Recurrent laryngeal nerve
(E) Superior laryngeal nerve (main trunk)

(14) A 55-year-old patient presents with a severe headache and double vision. Imaging reveals a small aneurysm within the right cavernous sinus. During examination the patient is unable to abduct the right eye, but other eye movements and the pupillary light reflex are intact.
Which of the following structures is most likely being compressed by the aneurysm?

(A) Abducens nerve (CN VI)
(B) Maxillary nerve (CN V2)
(C) Oculomotor nerve (CN III)
(D) Ophthalmic nerve (CN V1)
(E) Trochlear nerve (CN IV)

(15) A 62-year-old man with hypertension and atrial fibrillation presents to the emergency department with sudden-onset vertigo, nausea, and inability to walk. Physical examination reveals ipsilateral facial numbness (loss of pain and temperature), contralateral body numbness (loss of pain and temperature), and Horner's syndrome.
Which of the following artery is most likely occluded?

(A) Anterior Inferior Cerebellar Artery (AICA)
(B) Basilar artery
(C) Labyrinthine artery
(D) Posterior Inferior Cerebellar Artery (PICA)
(E) Superior Cerebellar Artery (SCA)

(16) A 68-year-old man presents with sudden-onset weakness in his left arm and leg. Physical examination reveals a right-sided "facial droop" involving both the upper and lower quadrants of the face, and his right eye is turned medially and cannot be abducted.
Which of the following structure is most likely the site of a single focal lesion?

(A) Internal capsule (posterior limb)
(B) Lower (caudal) pons
(C) Medulla at the level of the olive
(D) Midbrain at the level of the superior colliculus
(E) Upper (rostral) pons

(17) A 75-year-old woman falls in her bathroom and unable to get up. In the emergency department, her right leg is noted to be shortened and externally rotated. Radiographs confirm a displaced intracapsular fracture of the femoral neck. The orthopedic surgeon explains that this fracture carries a high risk of avascular necrosis (AVN) of the femoral head.
Which of the following vessel provides the primary blood supply to the adult femoral head and is most likely compromised in this patient?

(A) Artery of the ligamentum teres
(B) First perforating branch of the profunda femoris
(C) Lateral circumflex femoral artery
(D) Medial circumflex femoral artery
(E) Superior gluteal artery

(18) While performing a surgical exploration of the popliteal fossa, a surgeon identifies the tibial nerve. To safely reach the popliteal artery for a bypass graft, the surgeon must remember the specific relationship between these structures.
Which of the following statement best describes the path of the tibial nerve relative to the popliteal artery in the popliteal fossa?

(A) It remains consistently lateral to the artery throughout the fossa.
(B) It remains consistently medial to the artery throughout the fossa.
(C) It remains directly anterior to the artery throughout the fossa.
(D) It starts lateral to the artery and crosses to the medial side.
(E) It starts medial to the artery and crosses to the lateral side.

(19) A 20-year-old female basketball player is brought to the clinic after injuring her right knee during a game. She describes a non-contact injury where she landed from a jump and felt a sudden "pop," followed by the knee "giving way." Significant swelling (hemarthrosis) developed within two hours of the incident. On examination, there is excessive anterior translation of the tibia when the knee is flexed at 30 degrees, with no firm endpoint.
Which of the following ligament is most likely ruptured?

(A) Anterior cruciate ligament (ACL)
(B) Lateral collateral ligament (LCL)
(C) Medial collateral ligament (MCL)
(D) Oblique popliteal ligament
(E) Posterior cruciate ligament (PCL)

(20) A 35-year-old warehouse worker presents with chronic aching pain along the medial aspect of his midfoot. Physical examination reveals that his feet appear abnormally flat (pes planus) when standing, and his "medial longitudinal arch" has significantly collapsed.
Which of the following ligament is most likely damaged in this patient?

(A) Bifurcate ligament
(B) Long plantar ligament
(C) Medial (deltoid) ligament
(D) Plantar calcaneonavicular (spring) ligament
(E) Short plantar ligament (plantar calcaneocuboid)

Batch 02 – CAT 03 (2026) – MCQ Paper Answers

(1)	F	T	T	F	F
(2)	T	F	F	F	T
(3)	F	T	T	F	T
(4)	F	F	T	T	F
(5)	T	F	T	T	T
(6)	T	T	F	T	T
(7)	T	T	F	F	F
(8)	T	F	T	F	F
(9)	F	T	T	F	T
(10)	T	T	F	T	F
(11)	C				
(12)	C				
(13)	D				
(14)	A				
(15)	D				
(16)	B				
(17)	D				
(18)	D				
(19)	A				
(20)	D				

Batch 02- CAT 03 (2026) - SEQ Paper

UVA WELLASSA UNIVERSITY OF SRI LANKA
FACULTY OF MEDICINE
Continuous Assessment 03
May 2026
2023/2024 (02nd) Batch
Anatomy
Structured Essay Questions (SEQ) Paper

Time 11.15 a.m. – 12.15 p.m. (01 hour) Date of the exam: 2026.05.18

Index (MED) Number ……..

Please do not attempt or promote copying. No textbooks, notes, mobile phones, smart watches, or any other electronic communication devices are allowed.

Instructions to Candidates

- This paper contains two (06) Structured Essay Questions.
- Answer all questions.
- Write your answers in the spaces provided.
- If additional space is required, you may use extra sheets. Ensure that the relevant question number is clearly indicated on each additional sheet.
- Write your index number in the designated space on each answer sheet, including any extra sheets used.

(Q 1) Anatomy of the submandibular gland.

(1.1) Name the following structures. (15 Marks)

(1.1.1) Name two nerves closely related to the deep part of the gland.

(1.1.2) Name the artery grooving the posterior surface of the gland.

(1.2) Outline the course of submandibular duct. (15 Marks)

(1.3) Briefly explain the anatomical parts and relations of the submandibular gland. (30 marks)

(1.4) Briefly explain the blood supply, lymphatic drainage, nerve supply, and clinical anatomy of the submandibular gland. (40 marks)

(Total: 100 Marks)

(Q 2) A 24-year-old male presents to the emergency unit after a motorcycle accident. He complains of severe pain in his right lower limb and is unable to bear weight. He cannot stand or walk. On examination, there is swelling around the knee and weakness in foot dorsiflexion. Sensory loss is noted over the dorsum of the affected foot.

(2.1) List the neurovascular structures in the popliteal fossa. (30 Marks)

(2.2) List four muscles responsible for dorsiflexion of the foot. (20 Marks)

(2.3) Describe the course & distribution of the common peroneal nerve and explain the anatomical basis of patients' symptoms in relation to the injuries to the nerve.

(50 Marks)
(Total: 100 Marks)

Batch 02- CAT 03 (2026) - SEQ Paper Answers

Q1

Q1.1 Name the following structures **(15 Marks)**

1.1.1 Two nerves closely related to deep part

Lingual nerve (5), Hypoglossal nerve (5)

1.1.2 Artery grooving posterior surface

Facial artery (5)

Q1.2 Course of Submandibular Duct **(15 Marks)**

Arises from deep part of gland (2)
Emerges from medial/deep part (2)
Passes forwards in floor of mouth (2)
Runs between mylohyoid and hyoglossus/genioglossus (3)
Lingual nerve loops around duct (4)
Opens at sublingual papilla beside frenulum (2)

Q1.3 Parts and Relations of Submandibular Gland **(30 Marks)**

Parts: Superficial part (5), Deep part (5)
Relations - award 2 marks for each correct relation.

Superficial part relations
- Skin
- Superficial fascia
- Platysma
- Deep cervical fascia
- Body/submandibular fossa of mandible
- Facial artery
- Facial vein
- Mylohyoid
- Posterior belly of digastric
- Stylohyoid

Deep part relations

- Mylohyoid
- Hyoglossus
- Genioglossus
- Lingual nerve
- Hypoglossal nerve
- Submandibular ganglion
- Submandibular duct
- Sublingual gland
- Middle constrictor

Q1.4 Blood supply, lymphatic drainage, nerve supply & clinical anatomy (40 Marks)

Blood supply: Facial artery (4), Lingual/submental contribution (4)
Lymphatic drainage: Submandibular nodes (5), Deep cervical nodes (3)
Nerve supply: Parasympathetic (8), Sympathetic (4), Sensory (2)
Clinical anatomy: any two relevant points ×5

Q2

Q2.1 Neurovascular structures in popliteal fossa (30 Marks)

Tibial nerve (6), Common peroneal nerve (6), Popliteal vein (6), Popliteal artery (6), Additional structures 3×2

Q2.2 Muscles of dorsiflexion (20 Marks)

Tibialis anterior (5), Extensor hallucis longus (5), Extensor digitorum longus (5), Fibularis tertius (5)

Q2.3 Common Peroneal Nerve: Course, Distribution & Clinical Basis (50 Marks)

Course (20), Distribution (15), Clinical correlation (15)

Course

- Terminal branch of sciatic nerve
- Begins at superior angle of popliteal fossa
- Runs with biceps femoris
- Crosses lateral gastrocnemius
- Winds around fibular neck
- Pierces fibularis longus
- Divides into superficial & deep peroneal nerves

Motor distribution

- Short head of biceps femoris
- Fibularis longus
- Fibularis brevis
- Tibialis anterior
- Extensor hallucis longus
- Extensor digitorum longus
- Fibularis tertius
- Extensor digitorum brevis
- Extensor hallucis brevis

Sensory distribution

- Upper lateral cutaneous nerve of leg
- Sural communícating branch
- Dorsum of foot
- Lower anterolateral leg
- First interdigital cleft

Clinical basis

- Foot drop
- Loss/weakness of dorsiflexion
- Steppage gait
- Weak eversion
- Sensory loss over dorsum of foot
- Sensory loss first web space
- Injury vulnerability at fibular neck

Batch 02 – CAT 03 (2026)– OSPE Paper

(1)

(A) Identify the cell shown in picture A

(B) State one function of the cell identified in (A)

(C) Identify the type of cell in picture B

(D) State the site where the cell identified in (C) is found

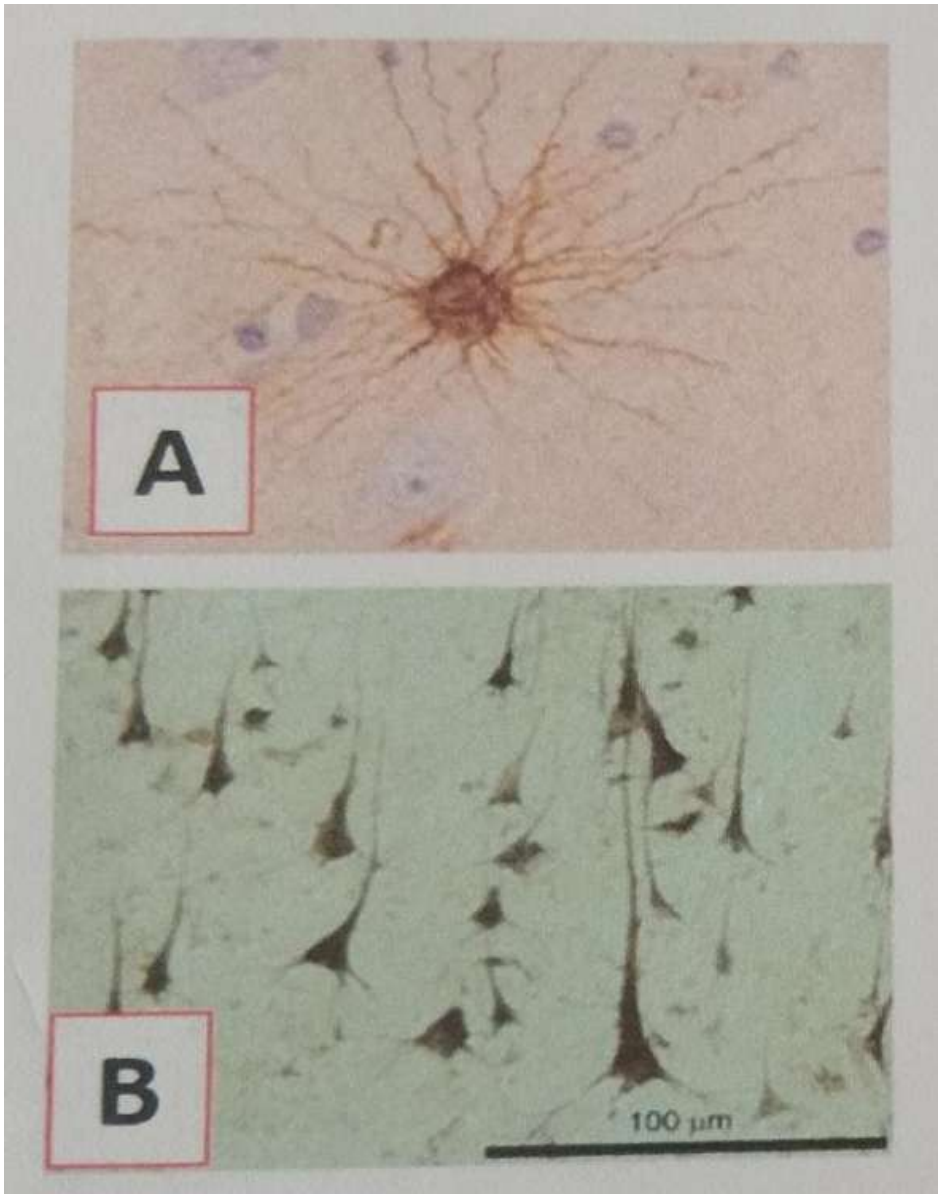

(2)

(A) Identify the gland.

(B) Mention the structure shown in red pin.

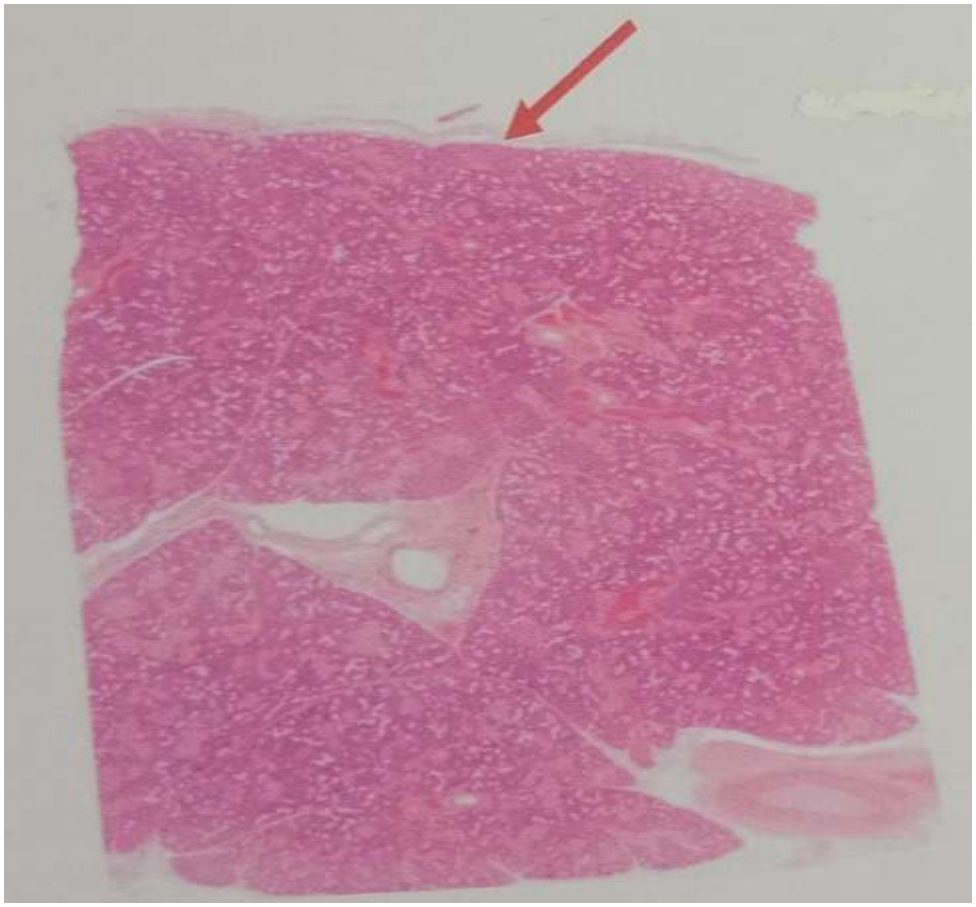

(3)

(A) Identify the structure.

(B) Mention the structure attached to it.



(4)

(A) Identify the structure marked.
(B) Name two structures traversing this.



(5) A 60-year-old female patient with diabetes mellitus and hypertension admitted with sudden onset of left sided face, arm, leg weakness. Imaging revealed an infarction of marked structure.

(A) Identify the structure marked.
(B) Mention the neuronal pathway affected.



(6) A 24-year-old football player admitted following severe pain in his right knee joint which injured while tackling. Investigations revealed damage to this structure.

(A) Identify the structure pierced by the pin.
(B) State its attachment.

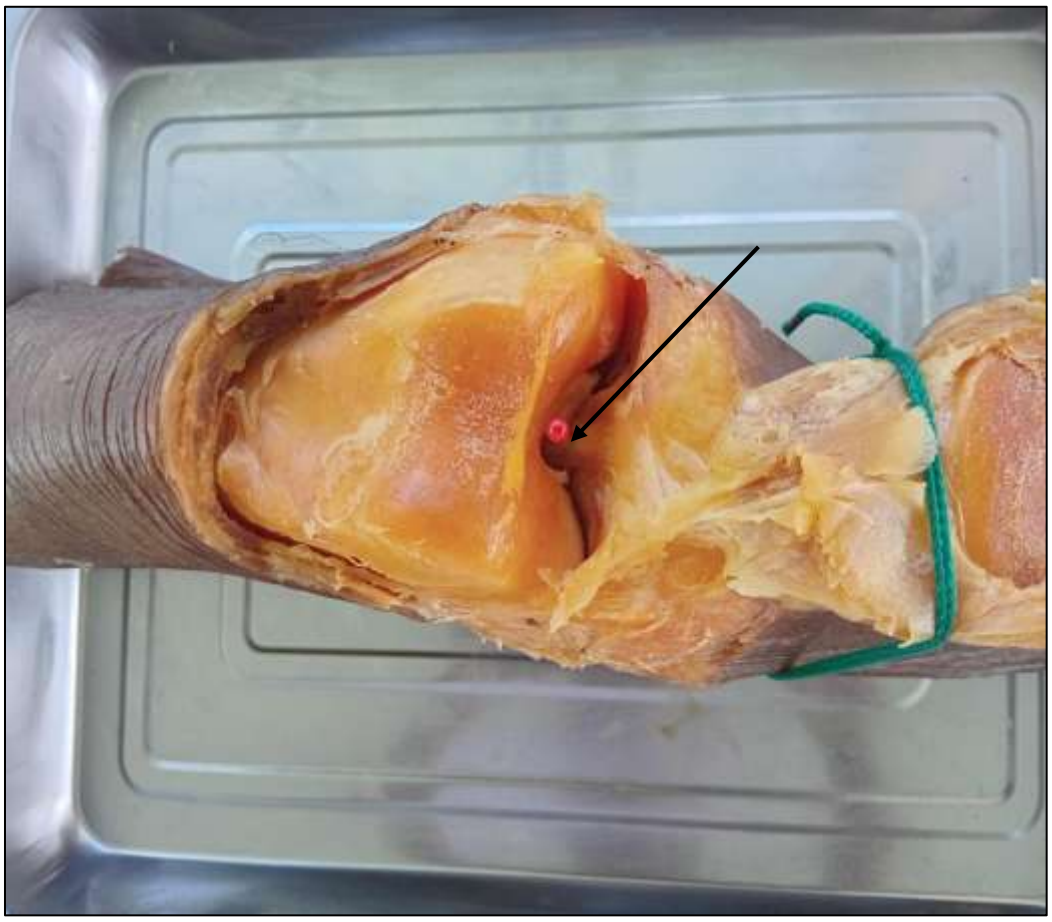

(7) 30-year-old male patient admitted with foot drop following a direct blow close to the knee joint. Investigations revealed damage of this structure.

(A) Identify the structure pierced by the pin.
(B) Name two muscles affected by this.



(8) A 56-year-old male patient with hypertension admitted following sudden severe neck pain, occipital headache followed by loss of consciousness. Imaging revealed damage (dissection) of this structure.

(A) Identify the structure marked by the pin.
(B) State its origin.



(9) A 65-year-old male patient who was a smoker for 40 years presented with pain in the left thigh while walking for 20 meters, which settled after resting for 5 minutes. Imaging showed narrowing of the lumen of this vessel.

(A) Identify the structure pierced by the pin.
(B) Name one important anastomosis contributed by this artery.



(10) 24-year-old bike rider collided with a wall and had a head impact. His clinical features were suggestive of damage to the marked structure.

(A) Identify the structure.
(B) Mention one clinical feature due to the damage of this structure.

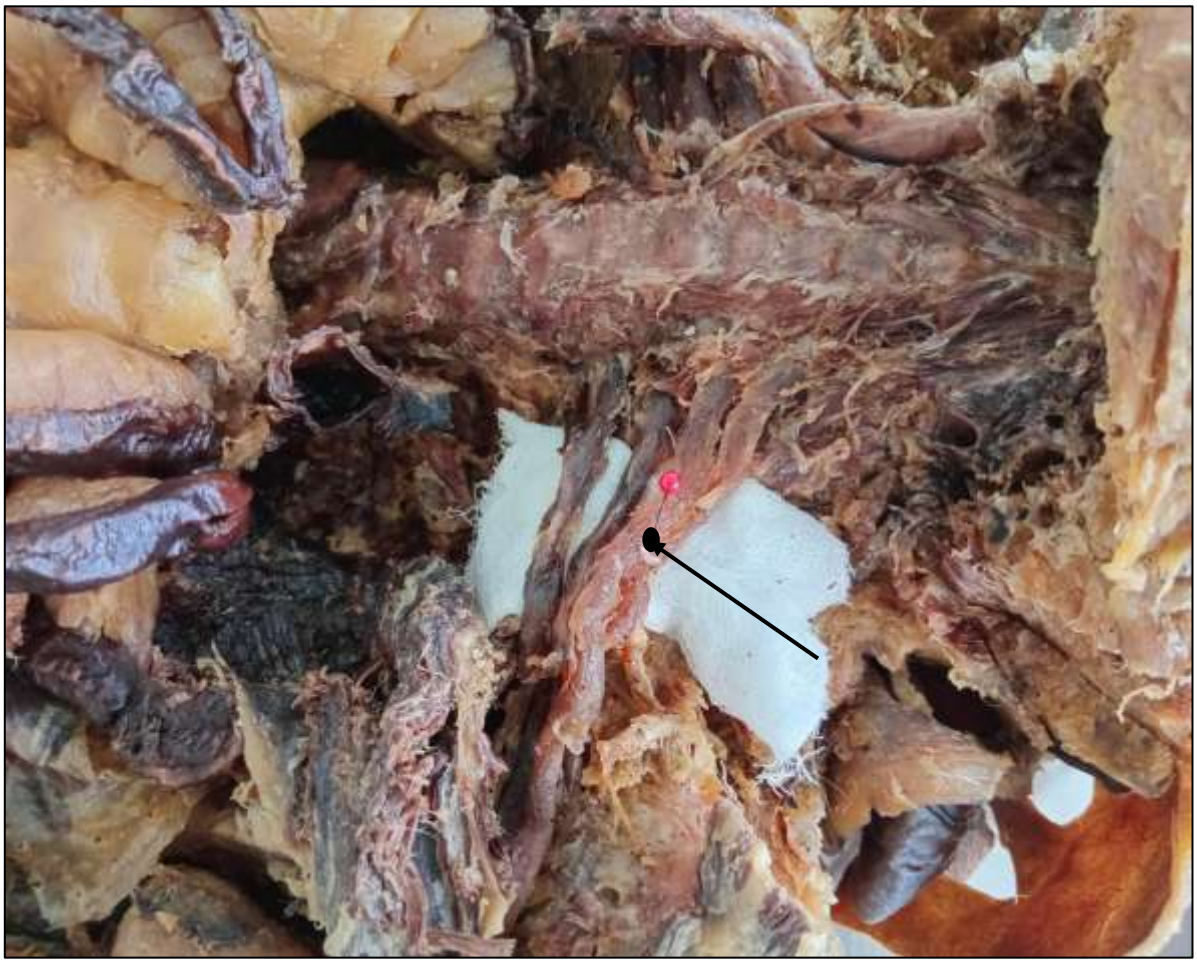

Batch 02 – CAT 03 (2026) – OSPE Paper Answers

(1)

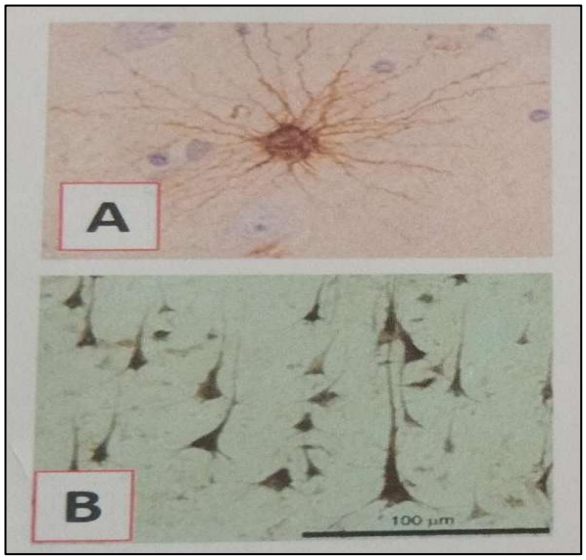

(A) Astrocyte
(B) Metabolic support to neurons
(C) Pyramidal cells/Betz cells
(D) Cerebral cortex /motor cortes

(2)

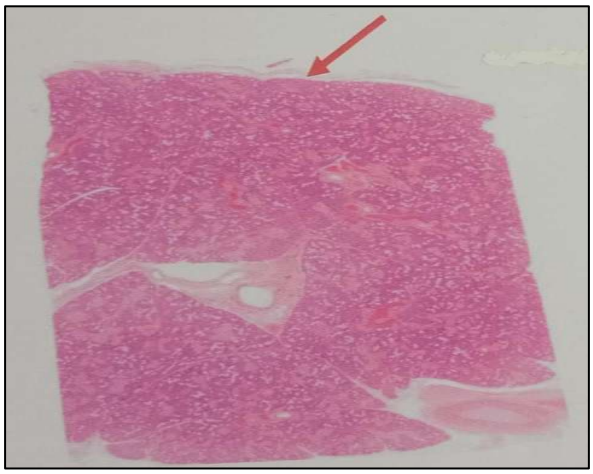

(A) Submandibular salivary and capsule

(3) Adductor tubercle is demonstrated



(A) Adductor tubercle
(B) Tendon of adductor magnus (hamstring part)

(4) Jugular foramen is demonstrated;



(A) Jugular foramen
(B) Glossopharyngeal nerve (CN IX)
Vagus nerve (CN X)
(Also, CN XI, internal jugular vein - optional additional answers)

(5) Right internal capsule is demonstrated (CT brain)

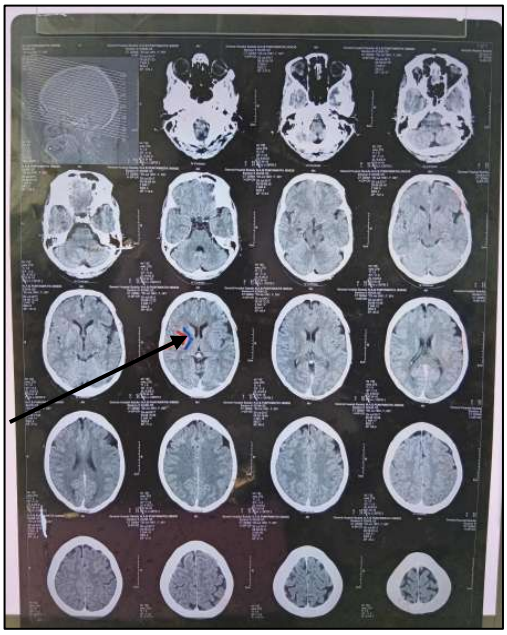

(A) Right internal capsule
(B) Corticospinal tract (pyramidal tract)
Leads to contralateral (left-sided) upper motor neuron weakness

(6) Anterior cruciate ligament is demonstrated

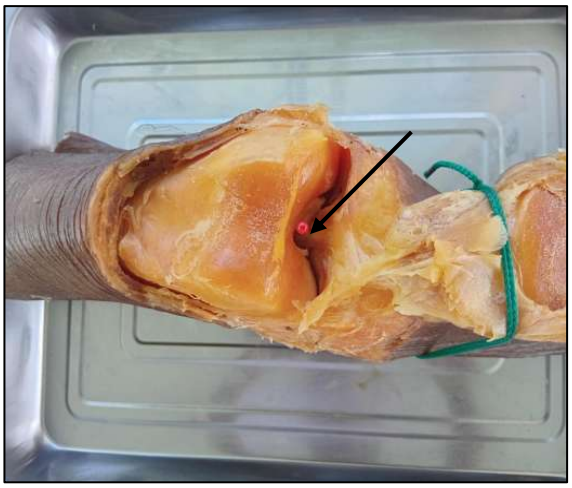

(A) Anterior cruciate ligament
(B) Anterior intercondylar area of tibia
Posterior part of medial surface of lateral femoral condyle

(7) Common peroneal nerve is demonstrated



(A) Common peroneal nerve (fibular nerve)
(B) Tibialis anterior
Extensor hallucis longus
(Also, extensor digitorum longus, fibularis longus acceptable)

(8) Vertebral artery is demonstrated:

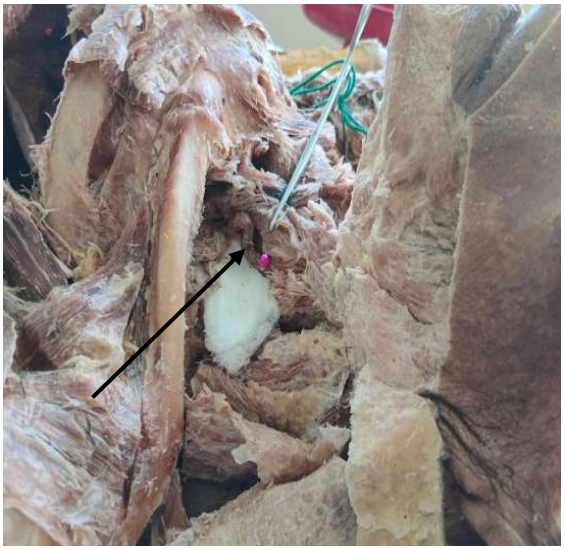

(A) Vertebral artery
(B) First part of subclavian artery

(9) Profunda femoris artery is demonstrated



(A) Profunda femoris artery
(B) Trochanteric anastomosis
Cruciate anastomosis
(Also, genicular contribution may be accepted depending on marking scheme)

(10) Upper trunk of the brachial plexus is demonstrated.



(A) Upper trunk of brachial plexus (C5-C6)
(B) Erb's palsy (waiter's tip deformity)
or
Loss of shoulder abduction and lateral rotation
or
Weak elbow flexion and supination

BATCH 01
2nd MBBS (PROPER) PAPERS WITH ANSWERS

Batch 01- 2nd MBBS Proper (2025) – MCQ Paper

UVA WELLASSA UNIVERSITY OF SRI LANKA
FACULTY OF MEDICINE
Second MBBS
September 2025
2022/2023 (1st) Batch Anatomy
Multiple Choice Questions (MCQ) Paper

Time 09.00 am – 12.00 pm (03 hours) Date of the exam 2025.09.24

Please do not attempt or promote copying. No textbooks, notes, mobile phones, smart watches, or any other electronic communication devices are allowed.

Please read the following instructions before marking responses on your answer sheets

1. Check that your question paper has a total of **15 pages,** including the front page.
2. **A single answer sheet is provided**. Please write your index number in the given space.
3. Read each question carefully before answering.
4. Mark the correct response as a **heavy black mark, filling the relevant circle completely**, using a **black lead pencil (6B or above grade).**
5. Do not make stray marks on the answer sheet. In case of an error, erase cleanly.
6. Your final answer should be a densely coloured circle through which the underlying letter is not visible.
7. Marking using any other method (e.g., mark the circle with a cross) is not valid.

Thirty (30) True/False Type Questions (Questions 1-30/Page 2-7)

1. Mark whether each response is true or false.
2. Given below is an example of how to mark a true/false type question.

Q 11. A woman has
A. One ovary.
B. One nose.
C. Two ears.
D. One eye.
E. Two hairs.

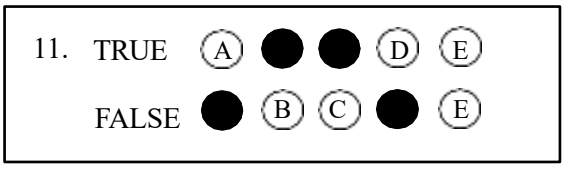

A correct response will get = +1 mark
An incorrect response will get = -1 mark
No response will get = 0 (zero) mark
Negative marks will not be carried over to the next question

Thirty (30) Single Best Response (SBR) Type Questions (Questions 31-60/ Page 8-15)

1. Mark the best response. Only one response per question should be marked.
2. If you mark the correct response, you will get the full marks for the question.
3. If you mark an incorrect response, fail to mark any response, select more than one response, or mark your response unclearly, you will not receive any marks for that question.
4. Given below is an example of how to mark a single best response type question.

Q 16. Speaking is a unique ability observed in humans. Which of the following body parts is primarily used for speech production?
A. Tongue
B. Hands
C. Feet
D. Ears
E. Nose

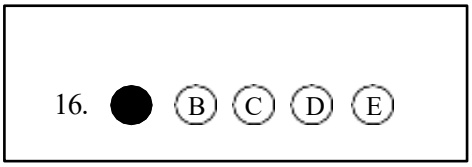

Question no. 01-30 are True or False type questions. Mark your answer for each of the five responses (A to E)

1. **True/ False regarding Cell, Cell Division and Gametogenesis?**
   A. Mitosis results in diploid daughter cells.
   B. Oogonia complete meiosis II before birth.
   C. Spermatids are haploid.
   D. Crossing over occurs in meiosis II.
   E. The centromere divides during anaphase of mitosis.

2. **True/ False regarding the third week‹ of embryological development?**
   A. Gastrulation begins with the formation of the primitive streak.
   B. The notochord develops from epiblast cells.
   C. Mesoderm gives rise to the epidermis.
   D. Neural plate formation is an event of the third week.
   E. The cloacal membrane contributes to gut tube formation.

3. **True/ False regarding the congenital anomalies and assisted reproductive technology (ART)?**
   A. In vitro fertilization (IVF) bypasses the uterine cavity.
   B. ART increases the risk of multiple gestations.
   C. Congenital anomalies may result from genetic or environmental factors.
   D. Folic acid supplementation prevents neural tube defects.
   E. Turner syndrome is associated with an extra X chromosome.

4. **True/ False regarding Autosomal recessive disorders?**
   A. Autosomal recessive disorders are expressed only when both alleles are defective.
   B. Carriers usually show clinical features of the disease.
   C. Consanguinity increases the risk.
   D. Males are more frequently affected than females.
   E. Cystic fibrosis is an example of autosomal recessive condition.

5. **True/ False regarding genetic engineering?**
   A. Growth Hormone is produced using genetically engineered bacteria.
   B. Monoclonal antibodies for cancer are generated using recombinant DNA techniques.
   C. Plasmids are commonly used as vectors in recombinant DNA technology.
   D. Restriction endonucleases are used to cut DNA at specific recognition sites.
   E. The polymerase chain reaction (PCR) is used to amplify DNA sequences.

6. **True/ False regarding tumour suppressor genes?**
   A. APC gene mutation is linked to familial adenomatous polyposis.
   B. Both alleles must be mutated for tumorigenesis (two-hit hypothesis).
   C. Loss of tumour suppressor genes causes apoptosis.
   D. p53 is called the “guardian of the genome.”
   E. RB gene prevents entry into S phase.

7. True/ False regarding the shoulder and upper arm?

A. Fractured surgical neck of the humerus endangers the radial nerve.
B. Coracobrachialis muscle inserts into the lateral epicondyle of the humerus.
C. Deltoid muscle is supplied mainly by the axillary nerve.
D. Long head of the biceps originates from the supraglenoid tubercle.
E. Rotator cuff muscles stabilize the glenohumeral joint.

8. True/ False regarding the radiological anatomy of the breast?

A. Breasts lie anterior to the pectoralis major on a mammogram.
B. Dense glandular tissue appears radiopaque on mammography.
C. Axillary tail is easily visualized on standard mediolateral oblique views.
D. Mammograms are less sensitive in fatty breasts.
E. Breast implants obscure visualization of breast tissue on mammograms.

9. True/ False regarding the ulnar nerve injuries?

A. Elbow dislocations cause ulnar palsy.
B. Clawing is more pronounced in low (wrist) lesions than high (elbow) lesions.
C. Thumb opposition is affected.
D. Sensory loss is over medial one and a half fingers.
E. Cause weakness of interossei muscles.

10. True/ False regarding the nerves in the superior mediastinum?

A. Left recurrent laryngeal nerve loops under the aortic arch near the ligamentum arteriosum.
B. Phrenic nerves pass posterior to the root of the lung.
C. The right recurrent laryngeal nerve loops under the right subclavian artery.
D. The sympathetic trunks lie within the superior mediastinum.
E. The vagus nerve passes posterior to the root of the lung.

11. True/ False regarding the thoracic wall?

A. The intercostal neurovascular bundle lies superior to each rib.
B. The internal thoracic artery runs along the lateral edge of the sternum.
C. The internal thoracic artery is used as a graft in coronary artery bypass surgery.
D. The external intercostal muscles are oriented anteroinferiorly from rib to rib.
E. Tension pneumothorax can cause tracheal deviation toward the affected side.

12. True/ False regarding the inguinal canal?

A. The deep inguinal ring is an opening in the transversal is fascia.
B. The deep ring has medial and lateral crura.
C. The deep ring is located medial to the inferior epigastric vessels.
D. The posterior wall is formed by the transversalis fascia.
E. The superficial inguinal ring is an opening in the external oblique aponeurosis.

13. True/ False regarding surgical anatomy of the rectus sheath?

A. Hematomas below the arcuate line can spread into the prevesical space.
B. Incisional hernia is a complication of rectus sheath injury.
C. Lateral rectus incisions avoid the arcuate line.
D. Midline laparotomy incision cause risk to epigastric vessels.
E. Rectus sheath hematoma can spread easily below' the arcuate line.

14. True/ False regarding pelvic peritoneal folds?

A. Uterovesical fold separates the bladder from the uterus.
B. Rectovesical fold is found in males between the bladder and rectum.
C. Rectovesical pouch dissection leads to anterior mesorectal plane.
D. The vesicouterine pouch is deeper than the rectouterine pouch.
E. The infundibulopelvic ligament contains the ovarian vessels.

15. True/ False regarding the gallbladder?

A. Cystic duct joins common hepatic duct to form the common bile duct.
B. Fundus can project beyond inferior boarder of the liver.
C. It lies in a fossa between the liver segments IV and V.
D. Receives both sympathetic and parasympathetic innervation.
E. Supplied by common hepatic artery

16. True/ False regarding the Stomach?

A. Posterior gastric ulcer may erode into the splenic artery.
B. Fundus of the stomach receives blood from the short gastric arteries.
C. The left gastric artery is a branch of the celiac trunk.
D. The left gastroepiploic artery is a branch of the gastroduodenal artery.
E. It *is* supplied by branches of both the celiac and superior mesenteric arteries.

17. True/ False regarding the rectum and anal canal?

A. External hemorrhoids occur above the dentate line.
B. Internal hemorrhoids are painful.
C. Lymphatic drainage of the upper anal canal goes to the internal iliac nodes.
D. The dentate line marks the junction between columnar and stratified squamous epithelium.
E. The upper third of the rectum *is* covered anteriorly and laterally by peritoneum.

18. True/ False regarding the portal circulation?

A. Caput medusae occurs due to portosystemic anastomosis around the umbilicus.
B. External hemorrhoids are due to portosystemic anastomosis at the anal canal.
C. Portal hypertension causes esophageal varices via the short gastric veins.
D. The inferior mesenteric vein drains into the superior mesenteric vein.
E. The portal vein is formed by the superior mesenteric vein and splenic vein.

19. True/ False regarding the kidneys?

A. Left kidney is slightly higher than the right kidney.
B. Right kidney is in close contact with the Morrison's pouch.
C. Posterior surface is related to diaphragm and quadratus lumborum.
D. Tail of the pancreas is anterior the hilum of the left kidney.
E. Spleen lies lateral to the right kidney.

20. True/ False regarding the larynx?

A. Injury to the recurrent laryngeal nerve cause hoarseness of voice.
B. Cricothyroid muscle is supplied by the recurrent laryngeal nerve
C. The rima glottidis is the space between the vestibular folds.
D. Vocal cords are lined by stratified columnar epithelium.
E. Thyroid cartilage lies at C6 vertebra level.

21. True/ False regarding the pharynx?

A. It communicates with the middle ear via the auditory tube.
B. Palatine tonsil lies between the palatoglossal and palatopharyngeal arches.
C. Glossopharyngeal nerve provides sensory innervation to the oropharynx.
D. Cricopharyngeus forms the upper esophageal sphincter.
E. Laryngopharynx extends from the epiglottis to the level of C3 vertebra.

22. True/ False regarding the thyroid histology?

A. C cells secrete calcitonin.
B. Colloid inside the follicle contains thyroglobulin.
C. Follicular cells become columnar when the gland is highly active.
D. Parafollicular (C) cells are located inside the follicular lumen.
E. The thyroid follicle is the functional unit of the gland.

23. True/ False regarding the lymphatic drainage of scrotal structures?

A. Epididymal lymph drains to the deep inguinal lymph nodes.
B. Lymph from the tunica vaginalis drains to the para-aortic nodes.
C. Scrotal incision for testicular cancer can prevent inguinal lymph node spread.
D. Scrotal skin lymph drains to the superficial inguinal lymph nodes.
E. Testicular lymph drains primarily to the deep inguinal lymph nodes.

24. True/ False regarding the pituitary gland?

A. A pituitary tumor may compress the optic radiation.
B. Anterior pituitary is supplied by branches of the superior hypophyseal artery.
C. It is connected to the hypothalamus by the infundibulum.
D. It lies in the hypophyseal fossa of the sphenoid bone.
E. Posterior pituitary produces oxytocin.

25. True/ False regarding the internal capsule?

A. A lesion in the anterior limb affects primary motor control of the limbs.
B. The corticospinal tract passes through the posterior limb.
C. The genu of the internal capsule carries corticonuclear fibers.
D. The posterior limb lies between the caudate nucleus and lentiform nucleus.
E. Vascular lesions cause contralateral hemiplegia.

26. True/ False regarding the hip joint?

A. Extracapsular fracture endangers arterial supply to the head of the femur.
B. It is a ball-and-socket synovial joint.
C. Gluteus medius and minimus stabilize the hip during walking.
D. The iliofemoral ligament prevents hyperextension.
E. Ligamentum teres is the main source of blood supply to the femoral head in adults.

27. True/ False regarding the lungs?

A. Apex of the lung extends above the level of the clavicle.
B. The cardiac notch is found on the medial surface of the right lung.
C. Lingula of the left lung corresponds to the middle lobe of the right lung.
D. Pulmonary arteries carry oxygenated blood to the lungs.
E. Right lung has three lobes and two fissures.

28. True/ False regarding liver sinusoids?

A. Bile duct cells phagocytose debris.
B. Hepatocytes perform metabolic and synthetic functions.
C. Kupffer cells are macrophages.
D. Sinusoidal endothelial cells are fenestrated.
E. Stellate (Ito) cells produce bile.

29. True/ False regarding the pharyngeal arches?

A. First pharyngeal arch gives rise to muscles of mastication.
B. Second pharyngeal arch contributes to the stapes.
C. Third pharyngeal arch forms the stylopharyngeus muscle.
D. Fourth pharyngeal arch forms the greater horn of hyoid bone.
E. Sixth pharyngeal arch contributes to the formation of cricoid cartilage.

30. True/False regarding the lower limb nerve injuries?

A. Injury to the femoral nerve can cause weakness in hip flexion.
B. Compression of the obturator nerve causes impairment of thigh adduction.
C. Damage to the sciatic nerve causes foot drop.
D. The superior gluteal nerve injury leads to Trendelenburg gait.
E. Common peroneal nerve is prone to injury in fractures of neck of fibula.

Question no. 31-60 are Single Best Answer (SBA) type questions. Select the best response to each question.

31. A patient with breast cancer undergoes testing for BRCA1 mutations to decide the treatment plan. What is the name given for this type of approach?

A. Genetic counseling
B. Genetic engineering
C. Karyotyping
D. DNA sequencing
E. Pharmacogenetics

32. A biotechnology lab develops a strain of bacteria capable of producing human insulin. Which of the following processes best describes this method?

A. CRISPR-Cas9 gene editing
B. DNA sequencing
C. Polymerase chain reaction (PCR)
D. Recombinant DNA technology
E. Southern blotting

33. A 57-year-old man presents with chest pain and shortness of breath. ECG shows ST elevation in leads I, aVL, V5—V6, indicating a lateral wall myocardial infarction. Angiography reveals blockage of a branch that arises from the artery running in the left atrioventricular groove and supplies the lateral wall of the left ventricle. Which branch is most likely occluded?

A. Diagonal branch of left anterior descending artery (LAD)
B. Marginal branch of left circumflex artery
C. Posterior descending artery (PDA)
D. Septal branch of LAD
E. Small cardiac branch of right coronary artery

34. A 6-month-old infant presents with cyanosis, squatting spells, and a systolic ejection murmur. Echocardiography shows overriding aorta. VSD, pulmonary stenosis, and right ventricular hypertrophy. Which embryological defect is responsible?

A. Abnormal looping of heart tube
B. Anterior malalignment of conotruncal septum
C. Defective ductus arteriosus closure
D. Failure of septum secundum formation
E. Malformation of septum primum

35. A 50-year-old man presents with painless jaundice and mild hepatomegaly. Imaging shows a mass at the transverse fissure of the liver (porta hepatis), compressing the biliary structures. Which of the following biliary structures gets compressed at the initial stage due to this mass?

A. Anterior branch of right hepatic duct.
B. Common bite duct.
C. Common hepatic duct
D. Cystic duct.
E. Intrahepatic hepatic ducts.

36. A 60-year-old man presents with obstructive jaundice. Imaging reveals a mass in the head of the pancreas. Which of the following structures is most likely' compressed?

A. Common bile duct
B. Common hepatic duct
C. Cystic duct
D. Porta hepatis
E. Right hepatic duct

37. A 22-year-old man presents with abdominal pain that began around the umbilicus and later localized to the right iliac fossa. On examination, there is maximum tenderness at McBurney's point. There is severe pain on hip flexion. Which of the following anatomical facts best explains the patient's clinical features?

A. Somatic nerve irritation leads to periumbilical pain.
B. Pain at McBurney's point corresponds to the surface marking of the tip of the appendix.
C. Retrocecal appendicitis cause psoas sign due to irritation of the psoas muscle.
D. The irritation of sympathetic innervation of appendix leads to psoas sign.
E. The somatic pain in the right iliac fossa is due to visceral peritoneum supplied by the iliohypogastric and ilioinguinal nerves.

38. A 60-year-old male presents with a change in bowel habits, blood in stool, and unexplained weight loss. Colonoscopy reveals a tumor in the sigmoid colon. Imaging suggests involvement of regional lymph nodes. Which of the following statements regarding colorectal anatomy in relation to malignancy is most accurate?

A. Lymph from the sigmoid colon drains directly into para-aortic lymph nodes.
B. Lymphatics from the sigmoid colon follows inferior mesenteric vein.
C. Lymphatics from tumour drain along the marginal artery of Drummond.
D. Tumors in the sigmoid colon metastasize directly to porta hepatis lymph nodes.
E. Tumors in the sigmoid colon primarily metastasize to the inferior mesenteric lymph nodes.

39. A 28-year-old male presents to the emergency department after a motor vehicle accident. He complains of left upper abdominal pain, shoulder tip pain, and dizziness. On examination, there is tenderness in the left hypochondrium and signs of hypovolemic shock. FAST ultrasound shows free fluid in the left upper quadrant. Which of the following statements regarding splenic trauma is most accurate?

A. A ruptured spleen presents typically with left shoulder pain.
B. Lacerations of the spleen cause retroperitoneal hemorrhage.
C. Splenic rupture can occur with 7" rib fracture.
D. The spleen receives its blood supply primarily from the superior mesenteric artery.
E. Trauma splenectomy carries a risk of pancreatic injury.

40. A 25-year-old male presents after a road traffic accident with severe pain and swelling in the anterior aspect of his right leg. On examination, he has weak dorsiflexion of the foot and loss of sensation over the first web space. Which region of the leg is most likely affected?

A. Anterior compartment
B. Deep posterior compartment
C. Lateral compartment
D. Subcutaneous tissue
E. Superficial posterior compartment

41. A 35-year-old male presents with a deep laceration to the posterior aspect of his knee. On examination, he has absent dorsalis pedis pulse, weak plantarflexion, and sensory loss over the sole of the foot. Which of the following structures in the popliteal fossa is most timely injured?

A. Common fibular nerve
B. Popliteal artery
C. Popliteal vein
D. Small saphenous vein
E. Tibial nerve

42. A 32-year-old female presents with sudden onset right-sided facial droop, inability to close her right eye, and loss of taste on the anterior two-thirds of the tongue. On examination, there is hyperacusis (sensitivity to sound) on the same side. Which anatomical segment of the facial nerve is most likely affected?

A. Chorda tympani branch
B. Extracranial segment
C. Greater petrosal nerve
D. Intracranial segment
E. Intratemporal segment

43. A 60-year-old male presents with sudden vertigo, nausea, vomiting, hoarseness, and difficulty swallowing. On examination, he has ipsilateral limb ataxia, loss of pain and temperature sensation on the face, and contralateral loss of pain and temperature sensation on the body. Which artery is most likely affected?

A. Anterior inferior cerebellar artery (AICA)
B. Basilar artery
C. Middle cerebral artery (MCA)
D. Posterior inferior cerebellar artery (PICA)
E. Superior cerebellar artery (SCA)

44. 2-day-old newborn presented with bilious vomiting and abdominal distension. Imaging with contrast reveals a corkscrew appearance of the duodenum. Which embryological condition is the most likely cause?

A. Duodenal atresia
B. Gut malrotation
C. Meckel's diverticulum
D. Omphalocele
E. Tracheo-esophageal fistula

45. A 25-year-old athlete presents with pain in the medial side of the foot after running. Examination reveals flattening of the medial longitudinal arch. Which of the following structures plays the most important role in maintaining the medial longitudinal arch?

A. Peroneus longus tendon
B. Plantar aponeurosis
C. Plantar calcaneonavicular ligament
D. Short plantar ligament
E. Tibialis anterior tendon

46. A 45-year-old male presents with low back pain radiating down the posterior thigh to the lateral aspect of the foot. Straight leg raise is positive on the right side. Neurological examination shows weakness of right ankle dorsiflexion. Which combination of intervertebral disc and nerve root is responsible for the above condition?

A. L3—L4 disc; L3 nerve root
B. L4—L5 disc; L4 nerve root
C. L4—L5 disc; L5 nerve root
D. LS-S1 disc; L5 nerve root
E. LS—SI disc; S1 nerve root

47. A 28-year-old male falls onto the crossbar of his bicycle, striking the perineum directly. He complains of severe perineal pain, inability to pass urine, and blood at the urethral meatus. On examination, there is perineal swelling and ecchymosis ("butterfly hematoma"). Which segment of the urethra is most likely injured in this patient?

A. Bulbar urethra
B. Membranous urethra
C. Navicular fossa
D. Penile (distal spongy) urethra
E. Prostatic urethra

48. During a hysterectomy, a surgeon emphasizes the importance of false and true uterine ligaments as supports of the uterus. Which of the following statements correctly explains uterine ligaments?

A. The broad ligament provides strong mechanical support to the uterus.
B. The round ligament maintains uterine anteversion.
C. The cardinal (transverse cervical) ligament is a false ligament.
D. The uterosacral ligament is only a peritoneal fold.
E. The mesometrium is a true ligament supporting the uterus laterally.

49. A 27-year-o1d football player presents with acute right knee pain after twisting his knee while pivoting. On examination, there is joint swelling, and excessive anterior mobility of tibia relative to femur. Which of the following structures is most likely injured?

A. Lateral collateral ligament
B. Medial collateral ligament
C. Anterior cruciate ligament
D. Posterior cruciate ligament
E. Meniscofemoral ligament

50. During pancreatic neck resection, a surgeon accidentally lacerates a vascular structure lying posterior to the neck of the pancreas, resulting in rapid hemorrhage. Which vessel is most likely injured?

A. Inferior mesenteric vein
B. Portal vein
C. Right gastroepiploic artery
D. Splenic artery
E. Superior mesenteric artery

51. A 45-year-old man presents with difficulty extending his knee after a penetrating injury to the anterior thigh. On examination, there is marked weakness of quadriceps femoris and loss of sensation over the anterior and medial aspects of the thigh. Which nerve is most likely injured?

A. Common peroneal nerve
B. Femoral nerve
C. Obturator nerve
D. Sciatic nerve
E. Lateral cutaneous nerve of the thigh

52. A 64-year-old male with atrial fibrillation develops sudden onset of left homonymous hemianopia. Neurological examination shows that central (macular) vision is preserved. MRI reveals an infarct in the territory of the right posterior cerebral artery (PCA). The sparing of central vision is best explained by collateral supply to which region?

A. Lateral geniculate body
B. Optic chiasm
C. Optic radiations in temporal lobe
D. The calcarine sulcus
E. The occipital pole

53. A 46-year-old woman undergoes excision of a submandibular gland due to recurrent sialolithiasis. During surgery, a nerve that runs superficial to the gland got accidentally injured. Postoperatively, the patient complained of weakness of movements of the lower Lip. Which nerve is most likely injured?

A. Glossopharyngeal nerve
B. Hypoglossal nerve
C. Lingual nerve
D. Marginal mandibular nerve
E. Nerve to mylohyoid

54. During a laparoscopic Nissen fundoplication for severe GERD, a surgeon is performing a crucial dissection along the superior aspect of the lesser curvature to mobilize the gastric fundus. The procedure is complicated by significant bleeding from a vessel. Which artery is the most likely source of this bleeding?

A. A Short gastric artery
B. Left gastric artery
C. Left gastroepiploic artery
D. Right gastric artery
E. Right gastroepiploic artery

55. A 3-month-old infant is diagnosed with Erb's palsy following a difficult delivery involving shoulder dystocia. On examination, the infant's affected arm is held in a characteristic "waiter's tip" position: adducted, internally rotated, and with the elbow extended and forearm pronated. What is the most likely injured component of the brachial plexus?

A. Lower trunk
B. Posterior cord
C. Middle trunk
D. Upper trunk
E. Medial and lateral cords

56. A 12-year-old boy presents with recurrent middle ear infections. During surgical exploration (tympanoplasty), the surgeon must be cautious to avoid injury to a nerve that crosses the middle ear cavity and carries taste sensation from the anterior two-thirds of the tongue. What is the most likely nerve?

A. Auriculotemporal nerve
B. Chorda tympani nerve
C. Glossopharyngeal nerve
D. Greater petrosal nerve
E. Lesser petrosal nerve

57. A 45-year-old male suffers a penetrating neck injury in the posterior triangle. On examination, he cannot shrug his left shoulder against resistance. Which of the following nerves is most likely damaged?

A. Accessory nerve
B. Glossopharyngeal nerve
C. Hypoglossal nerve
D. Upper trunk of brachial plexus
E. Vagus nerve

58. A 52-year-old woman undergoes a total thyroidectomy for multinodular goiter. On the first postoperative day, she develops tetany, perioral numbness, and carpopedal spasms. Which anatomical structure is most likely injured during surgery?

A. Inferior parathyroid glands
B. Recurrent laryngeal nerve
C. Submandibular gland
D. Superior thyroid artery
E. Thyroid ima artery

59. A 25-year-old man falls while playing football and presents with anterior shoulder pain and inability to abduct his arm. On examination, the Numeral head is palpable anteriorly. Which structure is most commonly injured in this type of shoulder dislocation?

A. Acromioclavicular ligament
B. Coracoacromial ligament
C. Coracoclavicular ligament
D. Coracohumeral ligament
E. Glenoid labrum

60. A 32-year-old woman experiences a posterior vaginal tear during childbirth, extending across the perineal body. If the tear is extended further, which structure is most likely to get injured?

A. Superficial transverse perineal muscle
B. Levator ani muscle
C. External anal sphincter
D. Pubococcygeus muscle
E. Ischiocavernosus muscle

Batch 01- 2nd MBBS Proper (2025) – MCQ Paper Answers

(1)	T	F	T	F	T
(2)	T	T	F	T	F
(3)	F	T	T	T	F
(4)	T	F	T	F	T
(5)	T	T	T	T	T
(6)	T	T	T	F	T
(7)	T	F	T	T	F
(8)	T	T	T	F	T
(9)	T	T	F	T	T
(10)	T	F	T	F	T
(11)	F	T	T	T	F
(12)	T	F	F	T	T
(13)	T	T	F	F	T
(14)	T	T	T	F	T
(15)	T	T	T	T	F
(16)	T	T	T	F	F
(17)	F	F	T	T	T
(18)	T	F	F	F	T
(19)	T	T	T	T	F
(20)	T	F	F	F	F
(21)	T	T	T	T	F
(22)	T	T	T	F	T
(23)	F	T	F	T	F
(24)	F	T	T	T	F
(25)	F	T	T	F	T
(26)	F	T	T	T	F
(27)	T	F	T	F	T
(28)	F	T	T	T	F
(29)	T	T	T	F	T
(30)	T	T	T	T	T
(31)	E				
(32)	D				
(33)	B				
(34)	B				
(35)	C				

(36) A
(37) C
(38) E
(39) E
(40) A
(41) B
(42) E
(43) D
(44) B
(45) D
(46) C
(47) A
(48) B
(49) C
(50) B
(51) B
(52) E
(53) D
(54) B
(55) D
(56) B
(57) A
(58) A
(59) E
(60) C

Batch 01- 2nd MBBS Proper (2025) - SEQ Paper

UVA WELLASSA UNIVERSITY OF SRI LANKA
FACULTY OF MEDICINE
2nd MBBS Examination
September 2025
2022/2023 (01st) Batch
Anatomy
Structured Essay Questions (SEQ) Paper

Time 1.00 pm - 4.00 pm (03 hours) Date of the exam: 2025.09.24

Index (MED) Number ……..

Please do not attempt or promote copying. No textbooks, notes, mobile phones, smart watches, or any other electronic communication devices are allowed.

Instructions to Candidates

- This paper contains two (06) Structured Essay Questions.
- Answer all questions.
- Write your answers in the spaces provided.
- If additional space is required, you may use extra sheets. Ensure that the relevant question number is clearly indicated on each additional sheet.
- Write your index number in the designated space on each answer sheet, including any extra sheets used.

Q 1. Anatomy of the pelviureteric system.

(1.1) Describe the embryological development of the ureter. (30 Marks)
(1.2) Describe the course and the anatomical relations of the ureter from kidney to bladder and its clinical relevance. (50 marks)
(1.3) During a percutaneous nephrolithotomy (PCNL), the needle passes from renal angle through several anatomical layers from the skin to the renal collecting system. List 5 structures pierced by the needle excluding skin and subcutaneous tissue. (20 marks)

Q 2. Venous anatomy and fascial compartments of the lower limb

(2.1) Describe the venous anatomy of the lower limb. (40 marks)
(2.2) Discuss the clinical importance of lower limb veins. (30 marks)
(2.3) Write short notes on the fascial compartments of the leg. (30 marks)

Q 3. Duodenum and hepatobiliary anatomy.

(3.1) Describe the course, relations of the second (descending) part of the duodenum. (40 marks)

(3.2) Describe the embryology of the liver, including its development, vascularization, and sociated anomalies. (40 marks)

(3.3) Draw a detailed diagram of subhepatic triangle. (20 marks)

Q 4. Anatomy of the Upper limb Write short notes.

(4.1) Flexor retinaculum of the hand. (30 marks)

(4.2) Innervation of the hand. (40 marks)

(4.3) Scapular anastomosis. (30 marks)

Q 5. A 35-year-old male sustains a stab injury to the right side of his thoracic spine at T8 level. His clinical features are suggestive of Brown-Séquard syndrome.

(5.1) Draw a cross section of the thoracic spinal cord. (50 marks)

(5.2) Describe the spinal tracts that cross this level and explain anatomical basis of the clinical features of this patient. (50 marks)

Q 6. A 52-year-old male presents with bright red bleeding per rectum and painful defecation. On examination, a small tender swelling is noted just lateral to the anal verge. The patient is diagnosed with a perianal abscess.

(6.1) Describe the gross anatomy of anal canal. (40 marks)

(6.2) Outline the contents of the urogenital and anal triangles. (30 marks)

(6.3) List the differences between internal and external hemorrhoids. (30 marks)

Batch 01- 2nd MBBS Proper (2025) - SEQ Paper Answers

Q1 Anatomy of the pelviureteric system.

1.1. Describe the embryological development of the ureter (30 Marks)

a. Ureteric bud origin (6)
b. Interaction with metanephric blastema (6)
c. Formation of renal pelvis, calyces, and ureter (6)
d. Congenital anomalies (duplex ureter, ectopic ureter, PUJ obstruction) (12)

1.2. Describe the course and anatomical relations of the ureter from kidney to bladder and its clinical relevance. (50 marks)

1. Course of the ureter (20 Marks)
    a. Abdominal division: renal pelvis → pelvic brim (5)
    b. Pelvic division: males (relation to vas deferens), females (relation to uterine artery) (5)
    c. Intramural division: bladder wall, ureterovesical junction (5)
    d. Ureteric constrictions (PUJ, crossing iliac vessels, UVJ) (5)

2. Anatomical relations (15 Marks)
    a. Abdominal: vessels, psoas, colon (5)
    b. Pelvic: relation to bladder and reproductive organs (10)

3. Clinical relevance & imaging (15 Marks)
    a. Sites of obstruction, stones, and symptoms (5)
    b. Iatrogenic injury risk during surgery and catheterization (5)
    c. Imaging and surface landmarks for intervention (5)

1.3. During a percutaneous nephrolithotomy (PCNL), the needle passes through several anatomical layers from the skin to the renal collecting system. List 5 structures pierced by the needle excluding skin and subcutaneous tissue. (20 marks)

1. Latissimus dorsi (posterior)
2. Quadratus lumborum (sometimes lateral approach)
3. Thoracolumbar fascia
4. Retroperitoneal fat
5. Gerota's fascia (renal fascia)
6. Perinephric fat
7. Renal capsule
8. Collecting system

Q2. Lower-limb venous anatomy and fascial compartments.

2.1 Describe the venous anatomy of the lower limb. (40 marks)

1. Superficial veins (15 Marks)
    a. Great saphenous vein: origin, course, termination (7)
    b. Small saphenous vein: origin, course, termination (5)
    c. Tributaries (3)

2. Deep veins (15 Marks)
    a. Femoral vein, popliteal vein, tibial and peroneal veins, venae comitantes (10)
    b. Venous valves (5)

3. Perforating veins (10 Marks)
    a. Course and function

2.2 Discuss the clinical importance of lower limb veins. (30 marks)

1. Varicose veins (10 Marks)
    a. Pathophysiology and common sites (5)
    b. Clinical signs (5)

2. Deep vein thrombosis (10 Marks)
    a. Risk factors, sites, complications (pulmonary embolism) (10)

3. Other clinical aspects (10 Marks)
    a. Venous ulcers (5)
    b. Saphenous vein harvesting and clinical relevance (5)

2.3 Write short notes on the fascial compartments of the leg. (30 marks)

1. Anterior compartment (8 Marks)
    a. Muscles: tibialis anterior, extensor digitorum longus, extensor hallucis longus, fibularis tertius (4)
    b. Nerve & vessels: deep fibular nerve, anterior tibial artery (4)
2. Lateral compartment (6 Marks)
    a. Muscles: fibularis longus and brevis (3)
    b. Nerve & vessels: superficial fibular nerve, branches of anterior tibial artery (3)
3. Superficial posterior compartment (6 Marks)
    a. Muscles: gastrocnemius, soleus, plantaris (3)
    b. Nerve & vessels: tibial nerve, posterior tibial vessels (3)
4. Deep posterior compartment (6 Marks)
    a. Muscles: tibialis posterior, flexor digitorum longus, flexor hallucis longus (3)
    b. Nerve & vessels: tibial nerve, posterior tibial vessels (3)
5. Clinical correlation (4 Marks)
    a. Compartment syndrome, nerve compression, surgical relevance

Q3.

3.1 Describe the course, relations of the second (descending) part of the duodenum. (40 marks)

1. Course of the second part (20 Marks)
    a. Vertebral levels (3)
    b. Relation to pancreas and bile duct (10)
    c. Vertical descent from superior duodenal flexure (2)
    d. Retroperitoneal (5)

2. Relations (20 Marks)
    a. Anterior (5)
    b. Posterior (5)
    c. Medial (5)
    d. Lateral (5)

3.2 Describe the embryology of the liver, including its development, vascularization, and associated anomalies. (40 Marks)

1. Origin and early development (15 Marks)
    a. Hepatic diverticulum (5)
    b. Division into liver and gallbladder (5)
    c. Invasion of septum transversum (5)

2. Vascular development (10 Marks)
    a. Vitelline veins and formation of portal system (5)
    b. Sinusoids and hepatic veins (5)

3. Clinical relevance (15 Marks)
    a. Biliary atresia (5)
    b. Accessory lobes / cysts (5)
    c. Other congenital anomalies (5)

3.3 Draw a detailed diagram of subhepatic triangle (20 marks)

a. Borders (10)
b. Contents (10)

Q4. Write short notes.

4.1 Flexor retinaculum of the hand. . (30 Marks)

a. Structure and attachments (10 Marks)
b. Relations (10 Marks)
c. Clinical relevance (10 Marks)

4.2 Innervation of the hand. (40 marks)

a. Median nerve (15 Marks) – motor & sensory (10), clinical (5)
b. Ulnar nerve (15 Marks) – motor & sensory (10), clinical (5)
c. Radial nerve (10 Marks) – sensory & motor, clinical (10)

4.3 scapular anastomosis. (30 marks)

1. Arteries involved: 10
    a. Subclavian → suprascapular, transverse cervical (dorsal scapular)
    b. Axillary → circumflex scapular

2. Sites of anastomosis: 10
    a. Triangular and quadrangular spaces
    b. Collateral network around scapular borders

3. Clinical relevance: 10
    a. Maintains circulation if subclavian or axillary artery is blocked.
    b. Important in shoulder surgery or trauma.

Q5. A 35-year-old male sustains a stab injury to the right side of his thoracic spine at T8 while working. He presents to the emergency department with brown Sequard syndrome.

5.1 Draw a cross section of thoracic spinal cord. (50 marks)

1. Outline & labeling (10 marks):
2. Gray matter (10 marks):
3. White matter tracts (15 marks):
4. Key features (10 marks):
    a. Smaller ventral horns compared to cervical/lumbar (fewer motor neurons).
    b. Intermediolateral cell column present.
5. Neatness/diagram quality (5 marks)

5.2 Describe the spinal tracts that cross this level and explain anatomical basis of the clinical features of this patient. (50 marks)

1. Ascending tracts (25 marks)
    a. Dorsal column (gracile fasciculus at thoracic level) – ipsilateral fine touch, vibration, proprioception → synapse in nucleus gracilis (cross in medulla, not spinal cord).
    b. Spinothalamic tract – pain, temperature, crude touch. Fibers cross in anterior white commissure within 1–2 segments → contralateral symptoms if damaged.
    c. Dorsal spinocerebellar tract – unconscious proprioception (ipsilateral, no crossing).

2. Descending tracts (15 marks)
    a. Lateral corticospinal tract – voluntary motor; fibers already crossed at pyramidal decussation (hence ipsilateral control).
    b. Anterior corticospinal tract – cross at spinal level via anterior commissure.
    c. Extrapyramidal tracts – vestibulospinal, reticulospinal (mostly uncrossed/ipsilateral).

3. Clinical significance (10 marks):
    a. Hemisection (Brown-Séquard syndrome):
        – Ipsilateral loss of fine touch, proprioception (dorsal column).
        – Contralateral loss of pain & temperature (spinothalamic).
        – Ipsilateral motor weakness/paralysis (corticospinal).

Q6. A 52-year-old male presents with bright red bleeding per rectum and painful defecation. On examination, a small tender swelling is noted just lateral to the anal verge. The patient is diagnosed with a perianal abscess.

6.1 Describe the gross anatomy of anal canal. (40 marks)

1. Length & Location (5 marks)
    a. Anal canal ~3–4 cm long (adult)
    b. Extends from anorectal junction to anal verge

2. Divisions (10 marks)
    a. Upper 2/3: anal canal proper (above pectinate line)
    b. Lower 1/3: below pectinate line

3. Muscles (10 marks)
    a. Internal anal sphincter (smooth muscle, involuntary)
    b. External anal sphincter (striated muscle, voluntary)
    c. Puborectalis part of levator ani

4. Blood supply (5 marks)
    a. Superior rectal artery (from IMA)
    b. Middle rectal artery (internal iliac)
    c. Inferior rectal artery (internal pudendal)

5. Relations & other features (10 marks)
    a. Anal columns, anal valves, anal sinuses
    b. Surrounding fat, ischioanal fossa

6.2 Outline the contents of the urogenital and anal triangles. (30 marks)

Urogenital Triangle – 15 marks

a. Muscles: bulbospongiosus, ischiocavernosus, superficial transverse perineal
b. Erectile tissues: bulb of penis/clitoris, crura
c. Fascia: superficial (Colles') and deep perineal fascia
d. Neurovascular structures: internal pudendal artery & branches, pudendal nerve branches

Anal Triangle – 15 marks

a. Muscles: external anal sphincter, levator ani, coccygeus
b. Fat-filled space: ischioanal fossa
c. Neurovascular: inferior rectal nerves & vessels, terminal branches of pudendal nerve

6.3 List the differences between internal and external hemorrhoids. (30 marks)

Feature	**Internal Hemorrhoids**	**External Hemorrhoids**
Origin	Above pectinate line	Below pectinate line
Vein involved	Superior rectal veins	Inferior rectal veins
Pain	Painless	Painful
Bleeding	Bright red, often painless	Minimal or painful bleeding
Covering	Columnar epithelium (visceral	Squamous epithelium (somatic
Clinical relevance	May prolapse	Thrombosis common

Batch 01- 2nd MBBS Proper (2025)– OSPE Paper

(1) Ulnar nerve behind the medial epicondyle is demonstrated.

Q. A 22-year-boy falls on flexed elbow on a broken glass which penetrates this structure.

(A) Identify the structure.

(B) State one clinical feature of this injury.

(2) Right coronary artery is demonstrated.

Q. A 52-year-male patient with diabetes mellitus and hypertension admitted with dizziness. Investigations reveal a narrowing of this vessel.

(A) Identify the structure.

(B) Mention one branch that supplies the conducting system.

(3) Internal thoracic artery is demonstrated.

Q. A 55-year-old man is undergoing coronary artery bypass surgery for left anterior descending artery. The surgeon planned to use this vessel for the bypass.

(A) Identify the vessel.

(B) Mention its origin.

(4) Vermiformis appendix is demonstrated.

Q. A 14-year-old boy admitted following pain in right iliac fossa, fever and vomiting. Surgery was performed and found to have abnormality of this structure.

(A) Identify the structure.

(B) Mention two common locations of that structure.

(5) Cystic artery is demonstrated.

Q.A 40-year-old female admitted following pain in the right hypochondrium and fever. Surgery was performed and demonstrated this structure in the surgical field.

(A) Identify the structure.

(B) Mention its common location.

(6) Obturator nerve is demonstrated.

Q. A 65-year-old female presented with pain in the medial aspect of the thigh. Ultrasound scan showed an ovarian lesion which is thought to compress this structure.

(A) Identify the structure.

(B) State one function of it.

(7) Epididymis is demonstrated.

Q.A 20-year-old male presented with pain in the scrotum. This structure was swollen.

(A) Identify the structure.
(B) Mention its embryological origin.

(8) Posterior tibial artery is demonstrated.

Q. A 65-year-old chronic smoker presented with severe pain in the calf while walking about 10 meters which is relieved by rest. Angiogram showed narrowing of this vessel.

(A) Identify the vessel.
(B) Mention its origin.

(9) Pubic tubercle is demonstrated.

(A) Identify the structure.
(B) Mention two attachments.

(10) Recurrent laryngeal nerve/ external laryngeal nerve is demonstrated.

Q. A 50-year female patient underwent thyroidectomy for a large goiter. Following the surgery, she had voice change which was thought to be a complication of damage to this structure.

(A) Identify the structure.
(B) Name important neurovascular relation to this structure.

(11) Stylomastoid foramen is demonstrated.

(A) Identify the structure pierced by the pin.
(B) Mention a structure passes through this.

(12) Mammogram with lesion displayed.

Q. A 42-year-old female patient underwent this investigation for suspected breast cancer.

(A) Identify the radiological investigation.
(B) Identify the location of the lesion.

(13) X ray – pelvis is demonstrated with marked Shenton's line.

(A) State the line marked.
(B) Mention two conditions that distort this marked line.

(14) ERCP is demonstrated with marked common bile duct.

Q. A 65-year-old male patient presented with yellowish discoloration of eyes, pale stool, dark urine and generalized itching.

(A) Identify the investigation.
(B) Identify the structure.

(15) CT/MRI brain is demonstrated with marked lentiform nucleus.

Q. A 60-year-old male patient presented with abnormal movements of left upper and lower limbs. CT/MRI shows a lesion marked by the arrow.

(A) Identify the structure.

(16) Histology – cardiac muscle.

(A) Identify the tissue type.
(B) Mention two characteristic features.

(17) Histology- small intestine.

(A) Identify the tissue.
(B) Mention two special features.

(18) Histology- kidney.

(A) Identify the tissue.
(B) Mention two special features.

(19) Histology- ovary.

(A) Identify the tissue.
(B) Mention two characteristic features.

(20) Histology- bronchus.

(A) Identify the tissue.
(B) Mention two features.

Batch 01- 2nd MBBS Proper (2025) – OSPE Paper Answers

(1)

(A) Ulnar nerve
(B) Sensory loss over medial 1½ fingers / clawing of 4th and 5th digits.

(2)

(A) Right coronary artery
(B) SA nodal artery (or AV nodal artery)

(3)

(A) Internal thoracic artery
(B) First part of subclavian artery

(4)

(A) Vermiform appendix
(B) Retrocecal and pelvic positions

(5)

(A) Cystic artery
(B) Calot's (hepatobiliary) triangle

(6)

(A) Obturator nerve
(B) Motor supply to medial compartment (adductor muscles) of thigh

(7)

(A) Epididymis
(B) Mesonephric (Wolffian) duct

(8)

(A) Posterior tibial artery
(B) Terminal branch of popliteal artery

(9)

(A) Pubic tubercle
(B) Inguinal ligament; medial crus of superficial inguinal ring

(10)

(A) Recurrent laryngeal nerve / External laryngeal nerve
(B) Inferior thyroid artery (RLN) / Superior thyroid artery (ELN)

(11)

(A) Stylomastoid foramen
(B) Facial nerve passes through it

(12)

(A) Mammography (mammogram)

(B) Lesion at the marked site on the image

(13)

(A) Shenton's line

(B) Fracture neck of femur; developmental dysplasia/dislocation of hip

(14)

(A) ERCP (Endoscopic Retrograde Cholangiopancreatography)

(B) Common bile duct

(15)

(A) Lentiform nucleus

(16)

(A) Cardiac muscle

(B) Striated fibers; intercalated discs

(17)

(A) Small intestine

(B) Villi; crypts of Lieberkühn

(18)

(A) Kidney

(B) Renal corpuscles (glomeruli); proximal/distal convoluted tubules

(19)

(A) Ovary

(B) Ovarian follicles; corpus luteum/stroma

(20)

(A) Bronchus

(B) Pseudostratified ciliated columnar epithelium; hyaline cartilage plates

BATCH 01
2nd MBBS (REPEAT)
PAPERS WITH ANSWERS

Batch 01- 2nd MBBS Repeat (2026)– MCQ Paper

UVA WELLASSA UNIVERSITY OF SRI LANKA
FACULTY OF MEDICINE
Second MBBS (Repeat)
January 2026
2022/2023 (1st) Batch Anatomy
Multiple Choice Questions (MCQ) Paper

Time 09.00 am – 12.00 pm (03 hours) Date of the exam 2026.01.07

Please do not attempt or promote copying. No textbooks, notes, mobile phones, smart watches, or any other electronic communication devices are allowed.

Please read the following instructions before marking responses on your answer sheets

1. Check that your question paper has a total of **15 pages,** including the front page.
2. **A single answer sheet is provided**. Please write your index number in the given space.
3. Read each question carefully before answering.
4. Mark the correct response as a **heavy black mark, filling the relevant circle completely**, using a **black lead pencil (6B or above grade).**
5. Do not make stray marks on the answer sheet. In case of an error, erase cleanly.
6. Your final answer should be a densely coloured circle through which the underlying letter is not visible.
7. Marking using any other method (e.g., mark the circle with a cross) is not valid.

Thirty (30) True/False Type Questions (Questions 1-30/Page 2-7)

1. Mark whether each response is true or false.
2. Given below is an example of how to mark a true/false type question.

Q 11. A woman has
A. One ovary.
B. One nose.
C. Two ears.
D. One eye.
E. Two hairs.

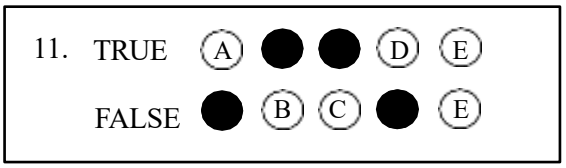

A correct response will get = +1 mark
An incorrect response will get = -1 mark
No response will get = 0 (zero) mark
Negative marks will not be carried over to the next question

Thirty (30) Single Best Response (SBR) Type Questions (Questions 31-60/ Page 8-15)

1. Mark the best response. Only one response per question should be marked.
2. If you mark the correct response, you will get the full marks for the question.
3. If you mark an incorrect response, fail to mark any response, select more than one response, or mark your response unclearly, you will not receive any marks for that question.
4. Given below is an example of how to mark a single best response type question.

Q 16. Speaking is a unique ability observed in humans. Which of the following body parts is primarily used for speech production?
A. Tongue
B. Hands
C. Feet
D. Ears
E. Nose

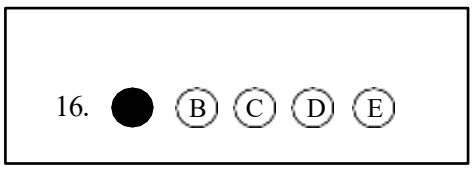

Question no. 01-30 are True or False type questions. Mark your answer for each of the five responses (A to E)

(1) True or False regarding upper limb nerves?

A. Median nerve supplies thenar muscles.
B. Ulnar nerve passes posterior to medial epicondyle.
C. Radial nerve injury at spiral groove spares innervation to triceps.
D. Axillary nerve supplies deltoid.
E. Musculocutaneous nerve pierces coracobrachialis.

(2) True or False regarding the brachial plexus?

A. Upper trunk is formed by C5—C6.
B. Medial cord forms musculocutaneous nerve.
C. Posterior cord gives axillary nerve.
D. Ulnar nerve arises from lateral cord.
E. Roots lie between anterior and middle scalene muscles.

(3) True or False regarding the shoulder joint?

A. It is a synovial saddle joint.
B. Glenoid labrum deepens the socket.
C. Axillary nerve is at risk in dislocation.
D. Supraspinatus initiates abduction.
E. Subscapularis is a rotator cuff muscle.

(4) True or False regarding the forearm?

A. Pronator teres inserts into the radial tuberosity.
B. Flexor digitorum profundus flexes distal interphalangeal joints.
C. Extensor carpi radialis longus extends wrist.
D. Median nerve passes between two heads of pronator teres.
E. Radial artery lies medial to flexor carpi radialis at the wrist.

(5) True or False regarding the heart?

A. Right atrium receives SVC, IVC, and coronary sinus.
B. Auricle of right atrium contains musculi pectinati.
C. Fossa ovalis is located in the interatrial septum.
D. SA node is supplied mainly by the left coronary artery.
E. Moderator band is found in the left ventricle.

(6) True or False regarding the lungs?

A. Right lung has two lobes.
B. Left lung has a cardiac notch.
C. Lingula is part of the upper lobe.
D. Pulmonary artery lies superior to the pulmonary vein at the hilum.
E. Bronchopulmonary segments share blood supply.

(7) True or False regarding the diaphragm?

A. Phrenic nerve originates from C3—C5.
B. IVC passes through the diaphragm at T8.
C. Aortic hiatus lies at T 10.
D. Esophageal hiatus transmits vagus nerves.
E. Diaphragm is the main muscle of inspiration.

(8) True or False regarding vertebral column?

A. Atlas has no body.
B. Thoracic vertebrae have costal facets.
C. Lumbar vertebrae have bifid spines.
D. Sacrum forms posterior pelvic wall.
E. Nucleus pulposus is avascular.

(9) True or False regarding back muscles?

A. Trapezius elevates scapula.
B. Latissimus dorsi inserts into intertubercular sulcus.
C. Erector spinae extend vertebral column.
D. Multifidus stabilizes vertebrae.
E. Rhomboids are supplied by the long thoracic nerve.

(10) True or False regarding the thoracic duct?

A. It originates from cisterna chyli.
B. It lies anterior to esophagus.
C. It drains both lower limbs.
D. It ends at right internal jugular—subclavian junction.
E. It crosses from right to left at T5 level.

(11) True or False regarding the anterior abdominal wall?

A. Linea alba is relatively avascular.
B. External oblique forms inguinal ligament.
C. Arcuate line lies midway between umbilicus and pubic crest.
D. Rectus sheath contains inferior epigastric vessels.
E. Transversalis fascia forms deep inguinal ring.

(12) True or False regarding the stomach?

A. The fundus lies at the level of the left 5th rib.
B. The lesser curvature gives attachment to the gastrophrenic ligament.
C. The left gastric artery is a branch of the celiac trunk.
D. The pylorus lies at Ll in the supine position.
E. The short gastric arteries supply the pylorus.

(13) True or False regarding the jejunum?

A. It has thicker walls than the ileum.
B. Peyer's patches are abundant.
C. Arterial arcades are few and large.
D. Vasa recta are longer than those of the ileum.
E. It occupies mostly the right lower quadrant.

(14) True or False regarding liver anatomy?

A. The quadrate lobe is functionally part of the left liver.
B. The caudate lobe receives blood from both right and left hepatic arteries.
C. The bare area is related to the diaphragm.
D. The ligamentum venosum is a remnant of the fetal umbilical vein.
E. Portal vein contributes 70-80% of the hepatic blood flow.

(15) True or False regarding the pancreas?

A. The uncinate process lies posterior to the superior mesenteric artery.
B. The main pancreatic duct drains into the minor papilla.
C. The tail lies within the splenorenal ligament.
D. It is secondarily retroperitoneal.
E. Bile duct is embedded within the head of the pancreas.

(16) True or False the kidney?

A. The right kidney is higher than the left.
B. Renal papillae project into minor calyces.
C. The renal artery lies anterior to the renal vein at the hilum.
D. It lies anterior to the quadratus lumborum.
E. Ureter emerges from the posterior part of the kidney.

(17) True or False regarding the ureter?

A. It has three classical constrictions.
B. The pelvic ureter passes anterior to the uterine artery in females.
C. Ureter is supplied by multiple segmental branches.
D. Ureteric calculi cause colicky pain from loin to groin.
E. Ureteric pain is carried by TIO - L2.

(18) True or False regarding the female pelvis?

A. The true conjugate is measured during pelvic examination.
B. The subpubic angle is wider in females.
C. Uterus is normally anteverted and anteflexed.
D. The ovary is attached to the uterus by the proper ovarian ligament.
E. The broad ligament contains the ovary.

(19) True or False regarding the pelvic diaphragm?

A. Coccygeus contributes to closure of the urogenital hiatus.
B. Puborectalis forms a U-shaped sling around anorectal junction.
C. Coccygeus spans from ischial spine to sacrum.
D. It supports pelvic organs.
E. Coccygeus is innervated by pudendal nerve.

(20) True or False regarding the perineum?

A. The perineal body lies anterior to the anus.
B. Ischioanal fossa contains pudendal canal laterally.
C. Deep perineal pouch contains bulbourethral glands in males.
D. Superficial perineal pouch contains ischiocavernosus.
E. Anal canal above the pectinate line has somatic innervation.

(21) True or False regarding the common peroneal nerve?

A. It is a branch of the sciatic nerve.
B. It winds around the head of the fibula.
C. It supplies the semitendinosus muscle.
D. Its deep branch supplies the dorsiflexors of the foot.
E. Injury to this nerve produces foot drop.

(22) True or False regarding the foot?

A. Tibialis posterior inserts into navicular.
B. Dorsum of foot is supplied by superficial peroneal nerve.
C. Medial longitudinal arch is supported by plantar aponeurosis.
D. Big toe is extended by extensor hallucis longus.
E. Dorsalis pedis artery lies medial to extensor hallucis longus tendon.

(23) True or False regarding the parotid gland?

A. The parotid duct opens into the oral cavity opposite the upper second molar tooth.
B. It is supplied by the facial nerve.
C. It receives parasympathetic fibers from the glossopharyngeal nerve.
D. The retromandibular vein lies superficial to the facial nerve within the gland.
E. The parotid duct pierces the buccinator muscle before entering the oral cavity.

(24) True or False regarding cranial nerves?

A. Abducent nerve passes through the foramen spinosum.
B. Maxillary division of trigeminal nerve passes through the foramen rotundum.
C. Oculomotor nerve passes through the foramen rotundum.
D. Ophthalmic division of trigeminal nerve passes through the foramen ovale.
E. Trochlear nerve passes through the superior orbital fissure.

(25) True or False regarding the orbit and eye?

A. Superior orbital fissure transmits CN Ill.
B. Ciliary ganglionic parasympathetic supply constricts pupil.
C. Ophthalmic artery arises from the internal carotid artery.
D. Lens is vascular.
E. Retina develops from neuroectoderm.

(26) True or False regarding external carotid artery?

A. It arises at the level of the upper border of the thyroid cartilage.
B. It gives off the vertebral artery as one of its branches.
C. The lingual artery is a direct branch of it.
D. It passes medial to the posterior belly of digastric muscle.
E. Its terminal branches are maxillary and superficial temporal arteries.

(27) True or False regarding characteristics of genetic inheritance patterns?

A. Autosomal dominant inheritance requires two copies of the mutant allele to be expressed.
B. Autosomal recessive disorders typically skip generations.
C. X-Iinked recessive disorders are more common in females than in males.
D. Mitochondrial disorders are inherited exclusively from the mother.
E. X-Iinked dominant disorders are transmitted from an affected mother to all her daughters.

(28) True or False regarding karyotype analysis?

A. A normal male karyotype is 46,XY.
B. Trisomy 21 is associated with an extra chromosome 21.
C. Turner syndrome presents as 46,XO.
D. Karyotyping can detect microdeletions <5 Mb.
E. Karyotype analysis visualizes the number and structure of chromosomes.

(29) True or False regarding clinical genetics?

A. SRY gene is responsible for male sex determination.
B. Autosomal dominant disorders require only one mutant allele to manifest.
C. X-Iinked recessive disorders commonly affect females more than males.
D. Genetic counseling helps families understand inheritance patterns.
E. Fragile X syndrome is caused by a trinucleotide repeat expansion.

(30) True or False regarding renal embryology?

A. Pronephros are functional.
B. Mesonephros forms adult kidney.
C. Ureteric bud forms ureter & collecting system.
D. Metanephric blastema forms nephrons.
E. Horseshoe kidney gets trapped under inferior mesenteric artery.

Question no. 31-60 are Single Best Answer (SBA) type questions. Select the best response to each question.

(31) A 28-year-old man falls on an outstretched hand while playing football. He complains of tenderness in the anatomical snuffbox, swelling, and pain on wrist movement. X-ray shows a fracture. Which bone is most likely fractured?

A. Capitate
B. Hamate
C. Lunate
D. Scaphoid
E. Triquetrum

(32) A 45-year-old carpenter presents with inability to extend his wrist and fingers after a midshaft humeral fracture. On examination, wrist drop is evident. Which nerve is most likely injured?

A. Axillary nerve
B. Median nerve
C. Musculocutaneous nerve
D. Radial nerve
E. Ulnar nerve

(33) A 32-year-old woman complains of numbness and tingling in the lateral aspect of her forearm, along with weakness of elbow flexion after a traumatic shoulder injury. Which nerve is most likely involved?

A. Axillary
B. Median
C. Musculocutaneous
D. Radial
E. Ulnar

(34) A 30-year-old man sustains a fracture of the neck of the fibula during a soccer game. He now presents with foot drop and numbness on the lateral leg and dorsum of the foot. Which nerve is most likely have been injured?

A. Common peroneal
B. Femoral
C. Obturator
D. Saphenous
E. Tibial

(35) A 40-year-old woman develops medial thigh numbness and weakness of thigh adduction after pelvic lymph node dissection.Which nerve is most likely injured?

A. Femoral
B. Inferior gluteal
C. Obturator
D. Sciatic
E. Superior gluteal

(36) A 55-year-old man complains of difficulty walking due to weak hip extension. Examination shows atrophy ofthe buttocks. Which muscle group is primarily affected?

A. Adductor magnus
B. Gluteal muscles
C. Hamstrings
D. Iliopsoas
E. Quadriceps

(37) A 50-year-old patient presents with numbness along the medial leg following knee arthroscopy. Which nerve is most likely involved?

A. Common peroneal
B. Femoral
C. Obturator
D. Saphenous
E. Tibial

(38) A patient presents with plantar flexion weakness and loss of sensation over the sole of the foot following a posterior knee dislocation. Which nerve is most likely injured?

A. Common peroneal
B. Femoral
C. Obturator
D. Saphenous
E. Tibial

(39) A 60-year-old man presents with progressive dyspnea and diminished breath sounds over the right lower lung. Chest X-ray shows fluid accumulation. Which pleural layer is most likely punctured during thoracocentesis to access the fluid safely?

A. Diaphragmatic pleura
B. Endothoracic fascia
C. Mediastinal pleura
D. Parietal pleura
E. Visceral pleura

(40) A 60-year-old man undergoes transthoracic echocardiography for right ventricular hypertrophy due to pulmonary hypertension. A prominent muscular band crossing the cavity from the interventricular septum to the anterior papillary muscle is noted. Whichof the following best describes the function ofthis structure?

A. Anchoring the chordae tendineae of the mitral valve
B. Carrying a part of the right bundle branch
C. Forming the pulmonary valve cusps
D. Preventing prolapse of the tricuspid valve during systole
E. Separating the right and left ventricles internally

(41) A 42-year-old woman sustains a stab injury to the 5th intercostal space midaxillary line and develops hemothorax. Which artery is most likely injured?

A. Intercostal artery
B. Internal thoracic artery
C. Subclavian artery
D. Superior epigastric artery
E. Thoracoacromial artery

(42) A 28-year-old man falls from a roof and sustains a penetrating injury to the posterior left lumbar region at the L3 level. On examination, he has flank tenderness, mild hematuria, and ecchymosis over the posterior abdomen. CT scan reveals a perinephric hematoma with laceration of the kidney. Which part of the kidney is at the highest risk of being damaged?

A. Lower pole of the kidney
B. Medial border of the kidney
C. Renal hilum
D. Renal pelvis
E. Upper pole of the kidney

(43) A 62-year-old man with pancreatic head carcinoma is scheduled for a pancreaticoduodenectomy (Whipple procedure). During surgery, careful dissection is required to avoid injury to the portal vein. The surgeon notes that a structure lies directly posterior to the portal vein along its course toward the liver. What is the most likely structure located posterior to the portal vein?

A. Common bile duct
B. Duodenum
C. Head of the pancreas
D. Inferior vena cava
E. Superior mesenteric artery

(44) A 70-year-old man presents with hematuria and pelvic pain. Imaging reveals that his prostate is enlarged around the urethra but spares the outer capsule. Which part of the prostate is most likely to compress the prostatic urethra in this patient?

A. Anterior fibromuscular stroma
B. Central zone
C. Peripheral zone
D. Seminal vesicle
E. Transition zone

(45) A 50-year-old woman presents with a reducible groin swelling below the inguinal ligament medial to femoral vessels. What is the most likely type of hernia described above?

A. Direct inguinal hernia
B. Femoral hernia
C. Indirect inguinal hernia
D. Paraumbilical hernia
E. Umbilical hernia

(46) A 42-year-old woman undergoes a laparoscopic inguinal hernia repair. During the procedure, an aberrant artery is noted coursing along the superior pubic ramus toward the obturator canal. The surgeon recognizes this as a potential "corona mortis," which can cause significant hemorrhage if injured. What are most likely arteries contributing to the formation of corona mortis?

A. Iliolumbar artery and lateral sacral artery
B. Inferior epigastric artery and obturator artery
C. Internal pudendal artery and inferior gluteal artery
D. Superior gluteal artery and obturator artery
E. Umbilical artery and uterine artery

(47) A 2-day-old newborn presents with bilious vomiting and "double bubble" sign on X-ray. Prenatal scan showed polyhydramnios. What is the most likely embryological cause?

A. Dorsal mesogastrium malformation
B. Failure of duodenal recanalization
C. Hindgut rotation abnormality
D. Malrotation of midgut
E. Persistence of vitelline duct

(48) A 3-year-old girl presents with persistent urine leakage from her umbilicus. Imaging shows a patent connection between bladder and umbilicus. Which structure is most likely responsible for this anomaly?

A. Allantois
B. Cloacal membrane
C. Dorsal mesogastrium
D. Urachus
E. Vitelline duct

(49) A 47-year-old woman undergoes laparoscopic right hemicolectomy for a cecal carcinoma. During surgery, the surgeon ligates a branch of the superior mesenteric artery that supplies both the cecum and the proximal ascending colon. Proper identification of this vessel is essential to avoid compromising blood flow to adjacent bowel segments. What is the artery that is most likely to be ligated during this procedure?

A. Ileocolic artery
B. Left colic artery
C. Marginal artery
D. Middle colic artery
E. Right colic artery

(50) A 3-year-old boy presents with a painless mass in the lateral neck just anterior to the sternocleidomastoid. Ultrasound reveals a cystic lesion. It is diagnosed as a branchial cyst. Which pharyngeal arch is most likely involved in this congenital anomaly?

A. First pharyngeal arch
B. Fourth pharyngeal arch
C. Second pharyngeal arch
D. Sixth pharyngeal arch
E. Third pharyngeal arch

(51) During surgery for a pancreatic tumor, the surgeon identifies a major artery running posterior to the pancreas and anterior to the aorta. What is the most likely artery described in the above scenario?

A. Celiac trunk
B. Common iliac artery
C. Inferior mesenteric artery
D. Renal artery
E. Superior mesenteric artery

(52) A 60-year-old man presents with sudden weakness of the right arm and face, sparing the leg. Imaging shows infarct in the lateral aspect of left cerebral hemisphere. What is the most likely artery affected?

A. Anterior cerebral artery
B. Basilar artery
C. Middle cerebral artery
D. Posterior cerebral artery
E. Vertebral artery

(53) A patient with a cervical syringomyelia (C5—T1) presents with bilateral loss of pain and temperature sensation over the upper limbs but preservation of fine touch and proprioception. Which structure is most likely to be affected initially?

A. Anterior white commissure
B. Dorsal columns
C. Dorsal root ganglion
D. Lateral corticospinal tract
E. Spinocerebellar tract

(54) An orbital floor blowout fracture from a sports injury results in entrapment of the inferior rectus muscle. This fracture passes through the roof of the maxillary sinus. Patient complains of numbness of the upper lip and cheek. Which of the following nerves is most likely injured?

A. Buccal nerve
B. Infraorbital nerve
C. Nasociliary nerve
D. Supraorbital nerve
E. Zygomaticotemporal nerve

(55) A patient presents with dysphagia and nasal regurgitation. Cranial nerve examination shows palatal droop. Which nerve is most likely damaged?

A. Facial nerve
B. Glossopharyngeal nerve
C. Hypoglossal nerve
D. Trigeminal nerve
E. Vagus nerve

(56) During excision of a submandibular gland tumor, the patient develops inability to depress the lower lip on the affected side postoperatively. Which nerve is most likely injured?

A. Buccal branch ofthe facial nerve
B. Cervical branch of the facial nerve
C. Hypoglossal nerve
D. Lingual nerve
E. Marginal mandibular branch of the facial nerve

(57) A 29-year-old man sustains a pelvic fracture following a motorcycle accident. He presents with perineal hematoma, scrotal swelling. CT angiography shows active arterial bleeding in the ischioanal fossa. The bleeding vessel is traced back to a branch that exits the pelvis through the greater sciatic foramen below the piriformis, and re-enters through the lesser sciatic foramen. Which artery is most likely injured in this patient?

A. Iliolumbar artery
B. Inferior gluteal artery
C. Internal pudendal artery
D. Lateral sacral artery
E. Obturator artery

(58) A 33-year-old pregnant woman undergoes routine first-trimester screening. Ultrasound demonstrates increased nuchal translucency, and biochemical markers suggest a high risk of aneuploidy. Chorionic villus sampling is performed, and the fetal karyotype report shows one of the following results. The obstetrician explains that the result represents a pure numerical chromosomal abnormality. Which fetal karyotype best represents a numerical chromosomal abnormality?

A. 45,XX,rob(21;21)
B. 46XX,inv(9p10-q10)
C. 46,XY,rob(14;21)
D. 46XY,t(9;22)
E. 47,XX,+21

(59) A neonate with imperforate anus also has vertebral anomalies, renal agenesis, and limb defects. Which of the following condition is most compatible with above scenario?

A. CHARGE syndrome
B. DiGeorge syndrome
C. Down syndrome
D. Prune belly syndrome
E. VACTERL association

(60) A 10-year-old boy presents with headaches, leg fatigue during exercise, and a blood pressure of 150/90 mmHg in the arms but 90/60 mmHg in the legs. Femoral pulses are delayed compared to radial pulses. Chest X-ray shows rib notching. Which anatomical anomaly is most likely cause for this condition?

A. Anomalous right subclavian artery
B. Narrowing at the level of the brachiocephalic trunk
C. Overriding of aorta
D. Patent ductus arteriosus
E. Post-ductal narrowing of the aorta

Batch 01- 2nd MBBS Repeat (2026) – MCQ Paper Answers

(1)	T	T	T	T	T
(2)	T	F	T	F	T
(3)	F	T	T	T	T
(4)	F	T	T	T	F
(5)	T	T	T	F	F
(6)	F	T	T	T	F
(7)	T	T	F	T	T
(8)	T	T	F	T	T
(9)	T	T	T	T	F
(10)	T	F	T	F	T
(11)	T	T	F	T	T
(12)	T	F	T	T	F
(13)	T	F	T	T	F
(14)	T	T	T	F	T
(15)	T	F	T	T	T
(16)	F	T	F	T	F
(17)	T	F	T	T	T
(18)	F	T	T	T	F
(19)	F	T	T	T	F
(20)	T	T	T	T	F
(21)	T	F	F	T	T
(22)	T	T	T	T	F
(23)	T	F	T	F	T
(24)	F	T	F	F	T
(25)	T	T	T	F	T
(26)	T	F	T	F	T
(27)	F	T	F	T	F
(28)	T	T	F	F	T
(29)	T	T	F	T	T
(30)	T	F	T	T	T
(31)	D				
(32)	D				
(33)	C				
(34)	A				
(35)	C				

(36) B
(37) D
(38) E
(39) D
(40) B
(41) A
(42) A
(43) D
(44) E
(45) B
(46) B
(47) B
(48) D
(49) A
(50) C
(51) E
(52) C
(53) A
(54) B
(55) E
(56) E
(57) C
(58) E
(59) E
(60) E

Batch 01- 2nd MBBS Repeat (2026)- SEQ Paper

UVA WELLASSA UNIVERSITY OF SRI LANKA
FACULTY OF MEDICINE
2nd MBBS Examination
January 2026
2022/2023 (01s) Batch
Anatomy
Structured Essay Questions (SEQ) Paper

Time 1.00 pm - 4.00 pm (03 hours) Date of the exam: 2026.01.07

Index (MED) Number ……..

Please do not attempt or promote copying. No textbooks, notes, mobile phones, smart watches, or any other electronic communication devices are allowed.

Instructions to Candidates

- This paper contains two (06) Structured Essay Questions.
- Answer all questions.
- Write your answers in the spaces provided.
- If additional space is required, you may use extra sheets. Ensure that the relevant question number is clearly indicated on each additional sheet.
- Write your index number in the designated space on each answer sheet, including any extra sheets used.

Q (1)

A 52-year-old woman presents to the surgical outpatient department with a palpable lump in the upper outer quadrant of her right breast. On examination, the lump is firm, nontender, and immobile.

(1.1) Outline the surface anatomy of the breast. (30 marks)
(1.2) Describe the lymphatic drainage of the breast and its clinical relevance. (40 marks)
(1.3) Outline the relations of the breast emphasizing the clinical relevance. (30 marks)

Q (2)

A 45-year-old man presents to the emergency department with a groin swelling following a bicycle accident. On examination, there is a tender, pulsatile mass below the inguinal ligament in the mid-inguinal region. The surgeon suspects a femoral artery pseudoaneurysm. The patient also reports numbness along the anterior thigh and weakness of hip flexion.

Based on the above scenario,

(2.1) Describe the anatomy of the femoral triangle. (30 marks)

(2.2) Describe the course and branches of the femoral nerve and the structures innervated by it. (50 marks)
(2.3) Outline the clinical significance of the structures in the femoral triangle. (20 marks)

Q (3)

A 48-year-old woman presents with a painless, slowly enlarging midline neck swelling for 6 months. Ultrasound shows a multinodular goitre, and she is planned for a total thyroidectomy.

(3.1) Explain the relations of the thyroid gland. (50 marks)
(3.2) Outline the blood supply and venous drainage of the thyroid gland along with its clinical significance. (50 marks)

Q (4)

A 35-year-old male presents to the orthopedic clinic with a knee injury. He complains of pain and swelling in his right knee, especially when trying to stand from a squatting position. On examination, there is tenderness along the joint line and limited extension.

(4.1) Describe the articulations that form the knee joint. (25 marks)
(4.2) List the intracapsular and extracapsular ligaments of the knee joint. (25 marks)
(A) Intracapsular ligaments
(B) Extracapsular ligaments:
(4.3) Explain the mechanisms of locking and unlocking of the knee joint, indicating the role of different muscles involved. (50 marks)

Q (5)

A 38-year-old male presents with acute abdominal pain, vomiting, and other features suggestive of intestinal obstruction. CT angiography reveals a superior mesenteric artery branch compromise affecting the ileum. Patient underwent an emergency laparotomy. During surgery the surgeon notes the differences in vascular pattern and mesenteric attachments between the jejunum and ileum.

Based on the above scenario, answer the following:

(5.1) Compare and contrast the blood supply of the jejunum and ileum, highlighting arterial patterns, arcades, and vasa recta. (50 marks)
(5.2) Describe the anatomy of the mesentery, including attachment, contents, and clinical relevance. (50 marks)

Q (6)

A 55-year-old man presents with difficulty in urination and nocturia. Digital rectal examination reveals enlargement of the prostate. Imaging shows narrowing of the prostatic urethra.

(6.1) Describe the anatomy of the male urethra, including divisions, length, and its relations. (50 marks)

(6.2) Describe the anatomy of the prostate, including lobes, zones, and its relations. (30 marks)

(6.3) Describe the embryological development of the male urethra. (20 marks)

Batch 01- 2nd MBBS Repeat (2026) - SEQ Paper Answers

Q 1.

(1.1) Outline the surface anatomy of the breast. (20 marks)

Key Points (5 marks each).

1. Location (5)
   Overlies pectoralis major, extends vertically from 2nd to 6th rib and horizontally from sternum to mid-axillary line.
2. Shape and size (5)
   Conical, hemispherical or pendulous; varies with age, hormonal status.
3. Nipple and areola (5)
   Nipple at 4th intercostal space, areola pigmented; Montgomery glands present.
4. Quadrants (5)
   Upper outer, upper inner, lower outer, lower inner – used for lesion localization.
5. Special features (5)
   Axillary tail (tail of Spence) extends into axilla; superficial veins visible in thin individuals.

(1.2) Describe the lymphatic drainage of the breast, including clinical significance in carcinoma spread. (50 marks)

Pathways (5 marks each).

1. Axillary nodes (75%) – major pathway (5)
   - Levels I (lateral), II (posterior to pectoralis minor), III (medial).
   - Drains lateral and central quadrants, including axillary tail.

2. Parasternal/ internal mammary nodes (5)
   - Along internal thoracic vessels; drains medial quadrants.

3. Supraclavicular and infraclavicular nodes (5)
   - Rare, but clinically significant in advanced disease.

4. Interpectoral (Rotter's) nodes (5)
   - Between pectoralis major and minor.

5. Clinical significance in carcinoma (5)
   - Axillary node involvement is key for staging and prognosis.
   - Sentinel lymph node biopsy is standard.
   - Internal mammary spread may occur silently; affects radiotherapy planning.

6. Lymphatic mapping (5)
   - Correlates quadrant of tumor with likely nodal involvement (upper outer quadrant → axilla).

7. Implications for metastasis (5)
   - Breast carcinoma commonly spreads first to axillary nodes, then internal mammary, then distant organs.

8. Surgical relevance (5)
   - Axillary clearance may be required; knowledge prevents iatrogenic lymphedema.

9. Imaging correlation (5)
   - MRI, ultrasound, and sentinel node scan visualize lymphatic spread.

10. Variations (5)
    - Accessory breast tissue may have separate lymphatic drainage.

(1.3) Clinical anatomy, including axillary tail, relations to underlying structures, and implications for surgery and imaging. (30 marks)

Key Points (5 marks each).

1. Axillary tail of Spence (5)
   - Extends into axilla; important for tumor detection.

2. Relations to underlying structures (5)
   - Overlies pectoralis major; separated by retromammary space.
   - Retromammary space allows mobility; important in imaging and surgery.

3. Surgical implications (5)
   - Mastectomy must preserve pectoralis major or remove it depending on tumor involvement.
   - Avoid injury to long thoracic nerve (serratus anterior) during axillary surgery.

4. Imaging implications (5)
   - Mammography requires visualization of axillary tail; retromammary space important for detecting deep tumors.

5. Other clinical relevance (5)
   - Nipple retraction, peau d'orange indicate malignancy.
   - Superficial veins or skin changes may guide biopsy and diagnosis.
   - Relations to neurovascular structures
   - Lateral thoracic artery, thoracodorsal vessels in axilla; caution during surgery.

Q 2.

(1.1) Describe the anatomy of the femoral triangle. (30 marks)

Superior boundary – inguinal ligament (5)
Medial boundary – adductor longus (5)
Lateral boundary – sartorius (5)
Floor – iliopsoas & pectineus (5)
Roof – fascia lata, cribriform fascia, skin (5)
Contents (NAVL – Nerve, Artery, Vein, Lymphatics) (5)

(2.1) Describe the course, branches, and innervation of the femoral nerve. (50 marks)

Femoral Nerve (5 marks each).

Origin – L2, L3, L4 (posterior divisions) (5)
Course through psoas major and iliacus (5)
Passage under inguinal ligament into femoral triangle (5)
Muscular branches – iliacus, sartorius, quadriceps (5)
Cutaneous branches – anterior thigh, saphenous nerve (5)
Articular branches – hip and knee joints (5)
Motor innervation – iliacus, sartorius, quadriceps (5)
Sensory innervation – anterior thigh, medial leg/foot (5)
Clinical relevance – quadriceps weakness, sensory loss (5)
Relation to femoral triangle contents (5)

(1.2) Outline the clinical anatomy of the structures in femoral triangle. (20 marks)

Femoral artery – pulse, catheterization (5)
Femoral vein – central venous access, relation to artery (5)
Femoral nerve – injury effects (motor/sensory) (5)
Femoral canal/lymphatics – femoral hernia (5)

Q 3.

(3.1) Explain the relations of the thyroid gland. (50 marks)

Relations of the Thyroid Gland

Lateral relations – carotid sheath, SCM, strap muscles, esophagus, recurrent laryngeal nerve. (10)
Anterior relations – strap muscles, skin, platysma, anterior jugular veins, isthmus. (10)
Posterior / Medial relations – trachea, esophagus, recurrent laryngeal nerve, parathyroids, sympathetic chain. (10)

Superior relations – thyroid cartilage, hyoid bone, larynx, superior thyroid vessels, external branch of superior laryngeal nerve. (10)
Inferior relations – trachea (lower rings), esophagus, inferior thyroid vessels, thoracic inlet, cervical sympathetic trunk. (10)

Optional extra clinical relevance in relations (if needed).

(3.2) Outline the blood supply, venous drainage, and clinical relevance including surgical considerations. (50 marks)

Blood Supply and Venous Drainage (4 points × 5 marks each)
Arterial supply – superior thyroid artery (5)
Arterial supply – inferior thyroid artery (5)
Arterial supply – thyroid ima artery (variant) and anastomoses (5)
Venous drainage – superior, middle, inferior thyroid veins and connection to vertebral plexus (5)

Clinical Relevance and Surgical Considerations (6 points × 5 marks each)
Recurrent laryngeal nerve injury – vocal cord paralysis. (5)
Superior laryngeal nerve injury – loss of pitch. (5)
Parathyroid gland injury – hypocalcemia. (5)
Hemorrhage risk – vascular anatomy. (5)
Goiter and retrosternal extension – airway/esophagus compression. (5)
Surgical landmarks – relation to carotid sheath, vessels, imaging correlation. (5)

Q 4.

(4.1) Enumerate the articulations forming the knee joint. (25marks)

Articulations Forming the Knee Joint

The knee is a compound synovial joint consisting of two main articulations:

Femorotibial articulation – between condyles of femur and tibial plateaus. (10)
Femoropatellar articulation – between patella and femoral trochlea. (10)
Optional: Tibiofibular articulation (proximal, contributes indirectly).
Each articulation allows specific movements – flexion, extension, rotation (mention).
Synovial joint type and cartilage covering – hyaline on femur, fibrocartilage menisci on tibia. (5)

(4.2) List the intracapsular and extracapsular ligaments of the knee. (25 marks)

- Intracapsular (within capsule)
  Anterior cruciate ligament (ACL) (5)
  Posterior cruciate ligament (PCL) (5)

- Extracapsular (outside capsule)
  Medial collateral ligament (tibial collateral) (5)
  Lateral collateral ligament (fibular collateral) (5)
  Other extracapsular ligaments (5)
    Patellar ligament
    Oblique popliteal ligament
    Arcuate popliteal ligament

(4.3) Explain the mechanism of locking and unlocking of the knee joint, mentioning the muscles related to the various movements at the joint. (50 marks)

(A) Locking Mechanism ("Screw-home") – 25 Marks

- Occurs during terminal extension (~last 15°) of the knee.
- Movement (10)
  Slight lateral rotation of the femur on tibia (or medial rotation of tibia if non-weight bearing).
- Muscles involved (5)
  Popliteus muscle – later unlocks the knee.
  Quadriceps femoris – stabilizes during locking.
- Purpose (5)
  Provides stability during standing without muscular effort.
- Ligaments involved (5)
  ACL, collateral ligaments tighten to prevent further rotation.

(B) Unlocking Mechanism – 15 Marks

- Initiated by popliteus muscle contraction. (5)
- Movement (5)
  Medial rotation of femur (or lateral rotation of tibia) to allow flexion.
- Muscles involved (5)
  Hamstrings (biceps femoris, semimembranosus, semitendinosus) – flexion.
  Gastrocnemius – assists flexion.

(C) Other Movements at the Knee – 10 Marks

- Flexion (3)
  hamstrings, gastrocnemius, sartorius, gracilis, popliteus.
- Extension (3)
  quadriceps femoris.

- Medial rotation of tibia (2)
  Semitendinosus, semimembranosus, sartorius, gracilis.
- Lateral rotation of tibia (2)
  Biceps femoris.

Q 5.

(5.1) Compare the blood supply of the jejunum and ileum, highlighting arterial patterns, arcades, and vasa recta. (50 marks)

Primary artery – branches of SMA (5)
Arterial branching pattern – fewer long branches (jejunum) vs more short branches (ileum) (5)
Arcades – simple (jejunum) vs multiple complex (ileum) (5)
Vasa recta – long (jejunum) vs short (ileum) (5)
Wall vascularity & mesenteric fat – rich, less fat (jejunum) vs less rich, more fat (ileum) (5)
Mesenteric border vs antimesenteric border (5)
Loop arrangement – uniform (jejunum) vs irregular (ileum) (5)
Clinical relevance – ischemia risk, surgical resection (5)
Marginal artery of Drummond importance (5)
Functional implication – nutrient absorption, perfusion differences (5)

(5.2) Describe the anatomy of the mesentery, including attachment, contents, and clinical relevance. (50 marks)

(A) Attachment – 5 points × 5 marks = 25 Point
Origin – posterior abdominal wall at L2 (5)
Extent – duodenojejunal flexure to ileocecal junction (5)
Fan-shaped, allows mobility of jejunum & ileum (5)
Base width ~15 cm (5)
Free edge anteriorly encloses vessels (5)

(B) Contents – 5 points × 5 marks = 25 Point
Arteries – jejunal & ileal branches of SMA (5)
Veins – tributaries of SMV (5)
Lymphatics – mesenteric lymph nodes, lacteals (5)
Nerves – sympathetic & parasympathetic fibers (5)
Fat & connective tissue supporting vessels (5)

Q 6.

(6.1) Anatomy of the male urethra, including divisions, length, and relations.

(50 marks)

(A) Divisions and Length (5 points × 5 marks = 25)

- Pre-prostatic urethra (5)
  0.5–1 cm
  Within bladder neck, surrounded by internal urethral sphincter
- Prostatic urethra (5)
  3 cm
  Traverses prostate; receives ejaculatory ducts & prostatic ducts
- Membranous urethra (5)
  1–2 cm
  Passes through urogenital diaphragm; external urethral sphincter surrounds it.
- Spongy (penile) urethra (5)
  15–16 cm
  Runs in corpus spongiosum; receives bulbourethral ducts; ends at external urethral meatus
- Total length ~20 cm (5)
  Average male urethra length

(B) Relations (5 points × 5 marks = 25)

- Pre-prostatic (5)
  Posterior: rectum
  Anterior: pubic symphysis
- Prostatic (5)
  Surrounded by prostate
  Lateral: levator ani
  Posterior: rectum
- Membranous (5)
  Surrounded by urogenital diaphragm.
  Lateral: bulbourethral glands
  Posterior: perineal membrane
- Spongy (5)
  Encased in corpus spongiosum
  Superficial: bulbospongiosus and ischiocavernosus muscles
- Clinical relevance (5)
  Catheterization, urethral strictures, trauma sites

(6.2) Anatomy of the prostate, including lobes, zones, and relations. (30 marks)

Anatomy of the Prostate

(A) Lobes and Zones (5 points × 5 marks = 25)

Lobes (traditional) - Anterior, posterior, median, lateral lobes (5)

Zones (modern – McNeal) - Peripheral, central, transitional, anterior fibromuscular (5)

- Peripheral zone - Largest; common site of carcinoma. (5)
- Central zone – Surrounds ejaculatory ducts; less commonly affected by carcinoma. (5)
- Transitional zone - Surrounds urethra; common site of benign prostatic hyperplasia. (5)

(B) Relations (5)

- Anterior: pubic symphysis, retropubic space (space of Retzius) (1)
- Posterior: rectum (palpable via digital rectal exam) (1)
- Inferolateral: levator ani muscles (1)
- Superior: bladder base (1)
- Inferior: urogenital diaphragm, membranous urethra (1)

(6.3) Embryological development of the male urethra. (20 marks)

Embryological Development of the Male Urethra

- Urethral groove formation - Ventral groove in phallus during 3rd–4th week. (5)
- Fusion of urethral folds - Forms penile (spongy) urethra. (5)
- Prostatic urethra - Derived from pelvic part of urogenital sinus. (5)
- Membranous urethra - Derived from definitive urogenital sinus. (5)

Batch 01 – 2nd MBBS Repeat (2026)– OSPE Paper

(1)

(A) Identify the tissue.

(B) Identify the structure marked by the pin.

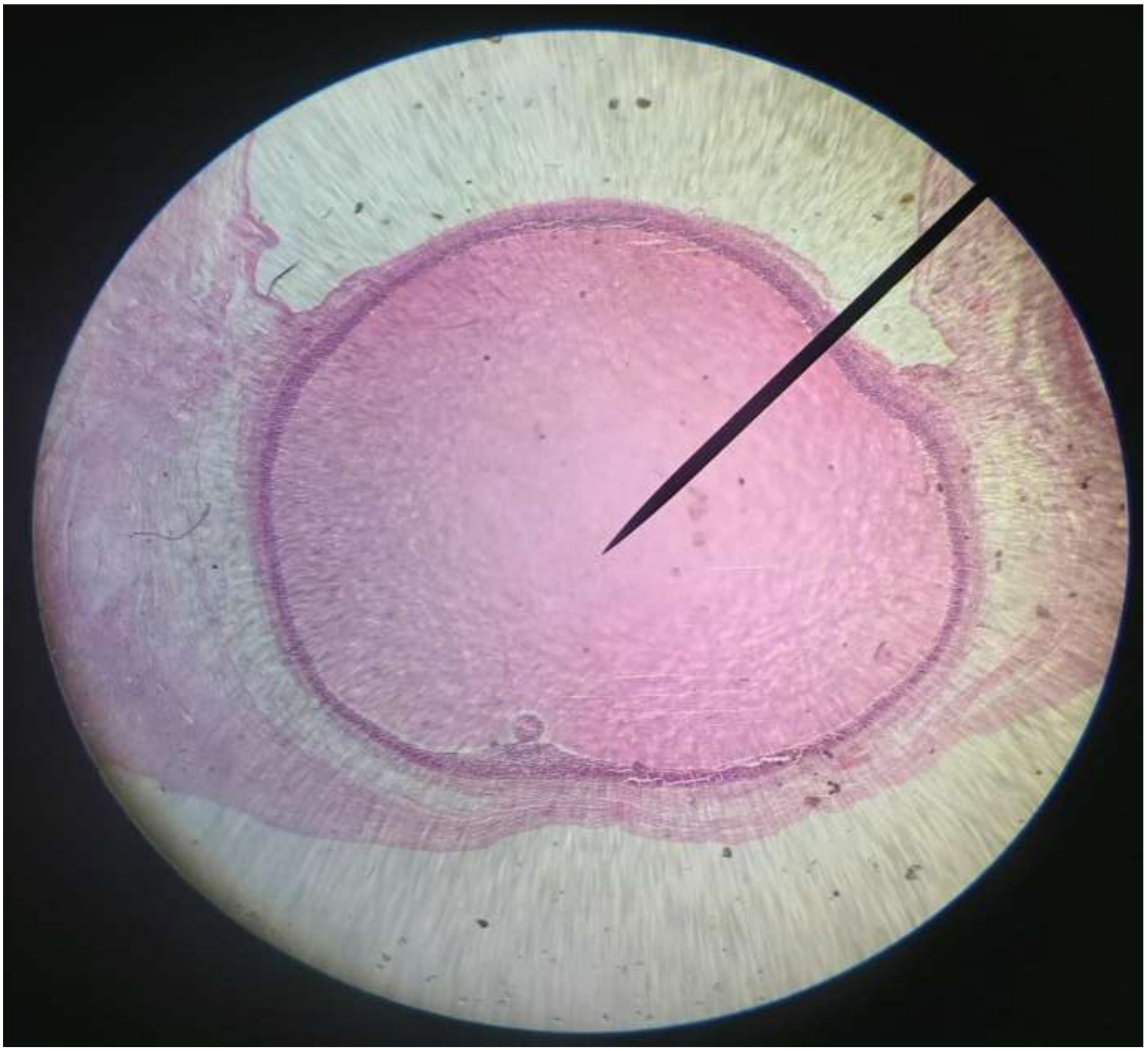

(2)

(A) Identify the tissue.

(B) Name two functions of this tissue.

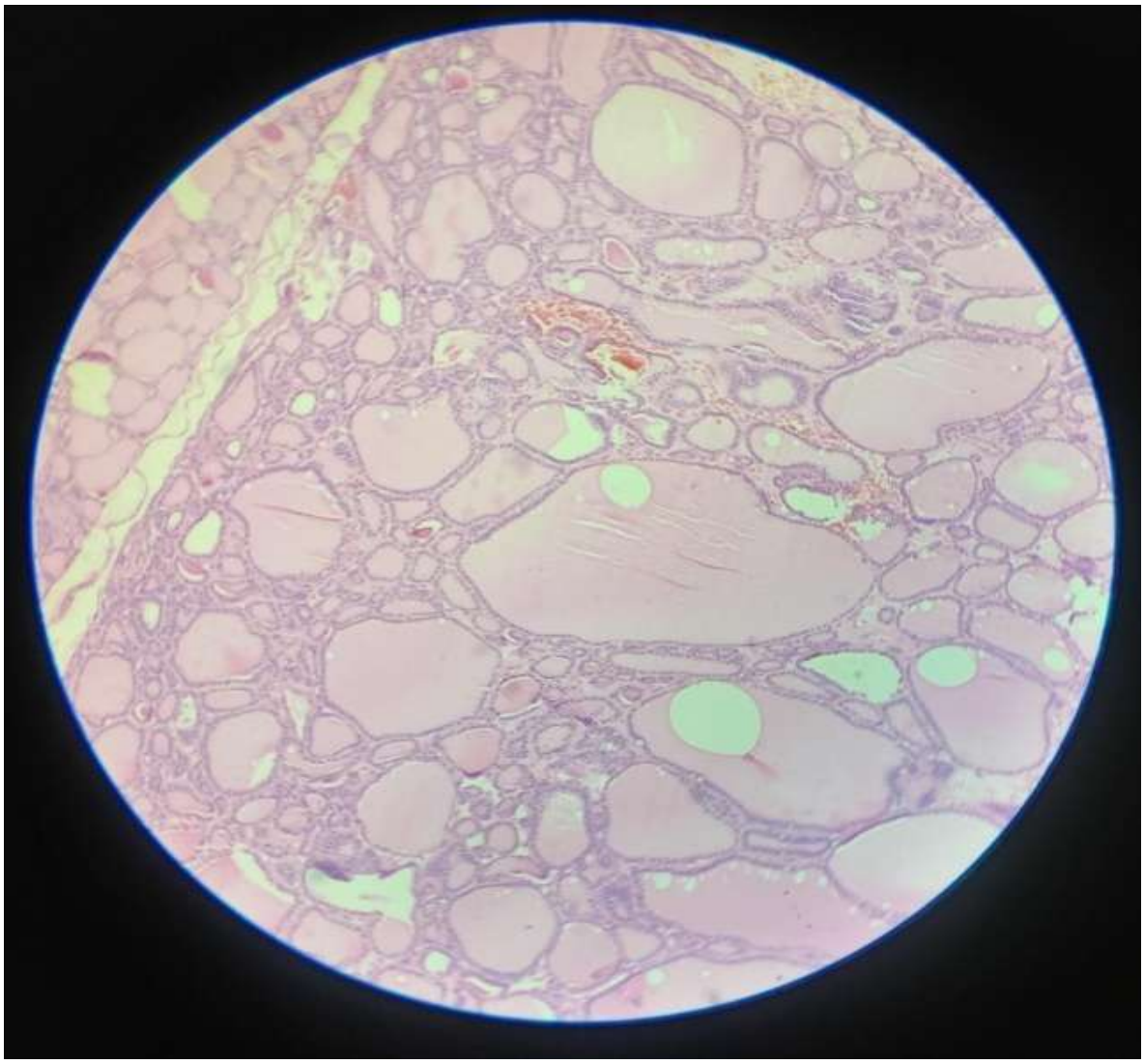

(3)

(A) Identify the space indicated. (Traversed by the pin).

(B) Name the structure that traverses this space.



(4)

(A) Identify the tissue.

(B) Name the epithelium type.

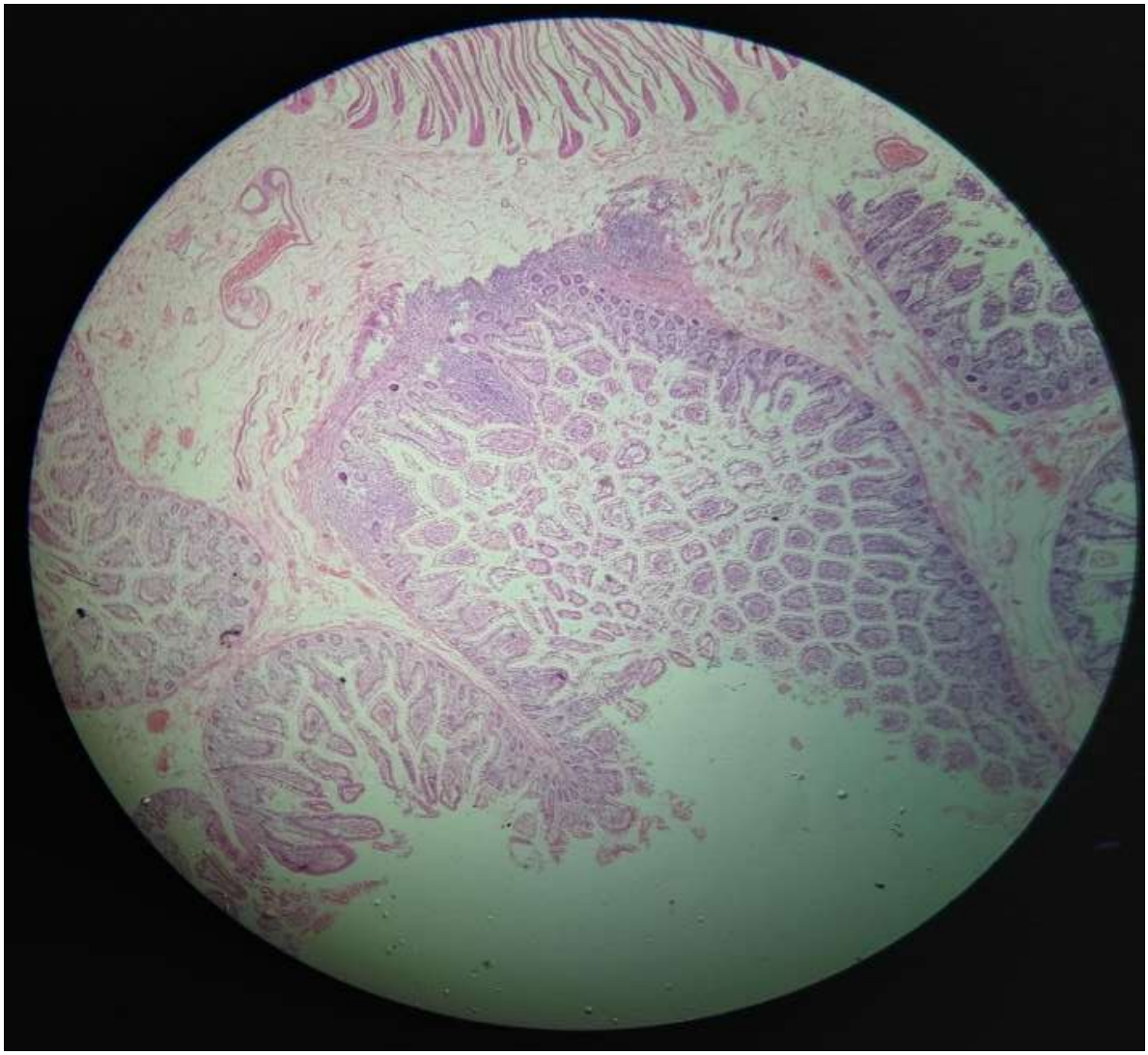

(5) A 70-year-old male patient presented with a chronic cough. Chest X-ray was performed as part of the investigations.

(A) Identify A.
(B) Identify B.

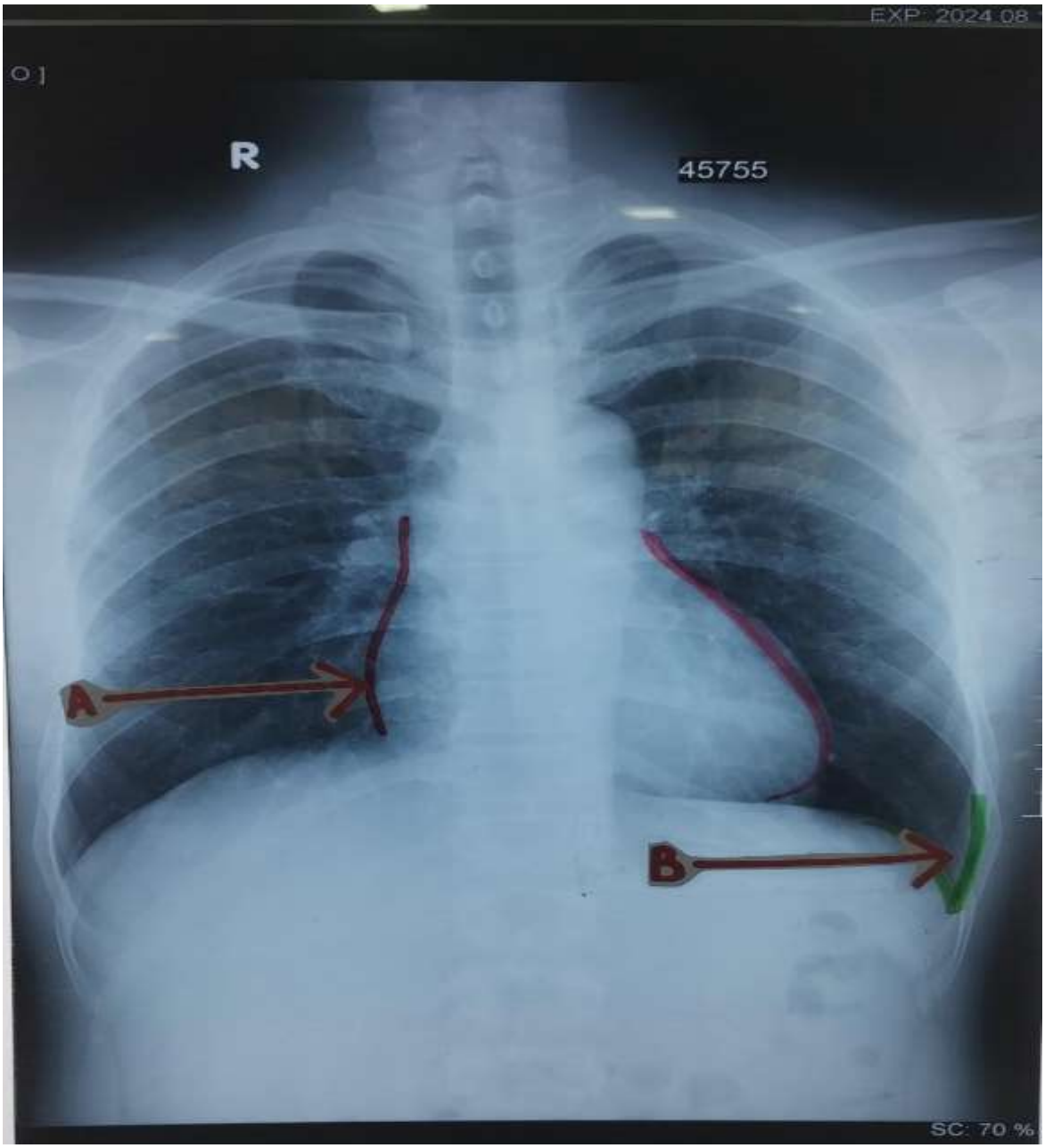

(6)

(A) Identify the tissue.

(B) What is the toughest histological layer in this structure?



(7)

(A) Identify the Structure.

(B) Name a clinical consequence of epithelium damage in this tissue.

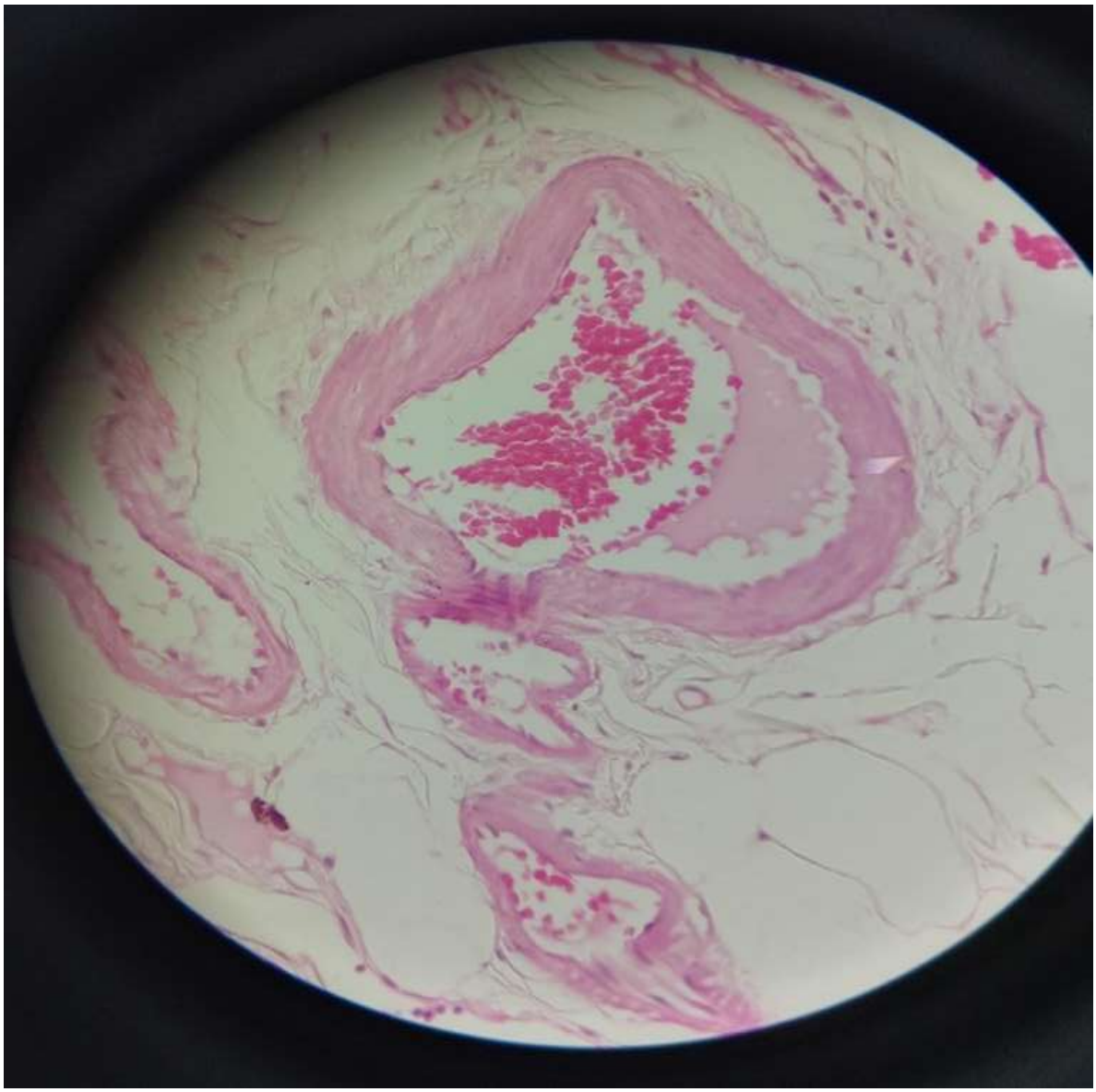

(8) A 54-year-old male patient admitted with severe pain in the right loin radiating to the groin. Ultrasound scan of the abdomen showed an abnormality in urinary system. This investigation was done for further evaluation and an abnormality was found in the marked region.

(A) Identify the structure.
(B) Mention its epithelium.

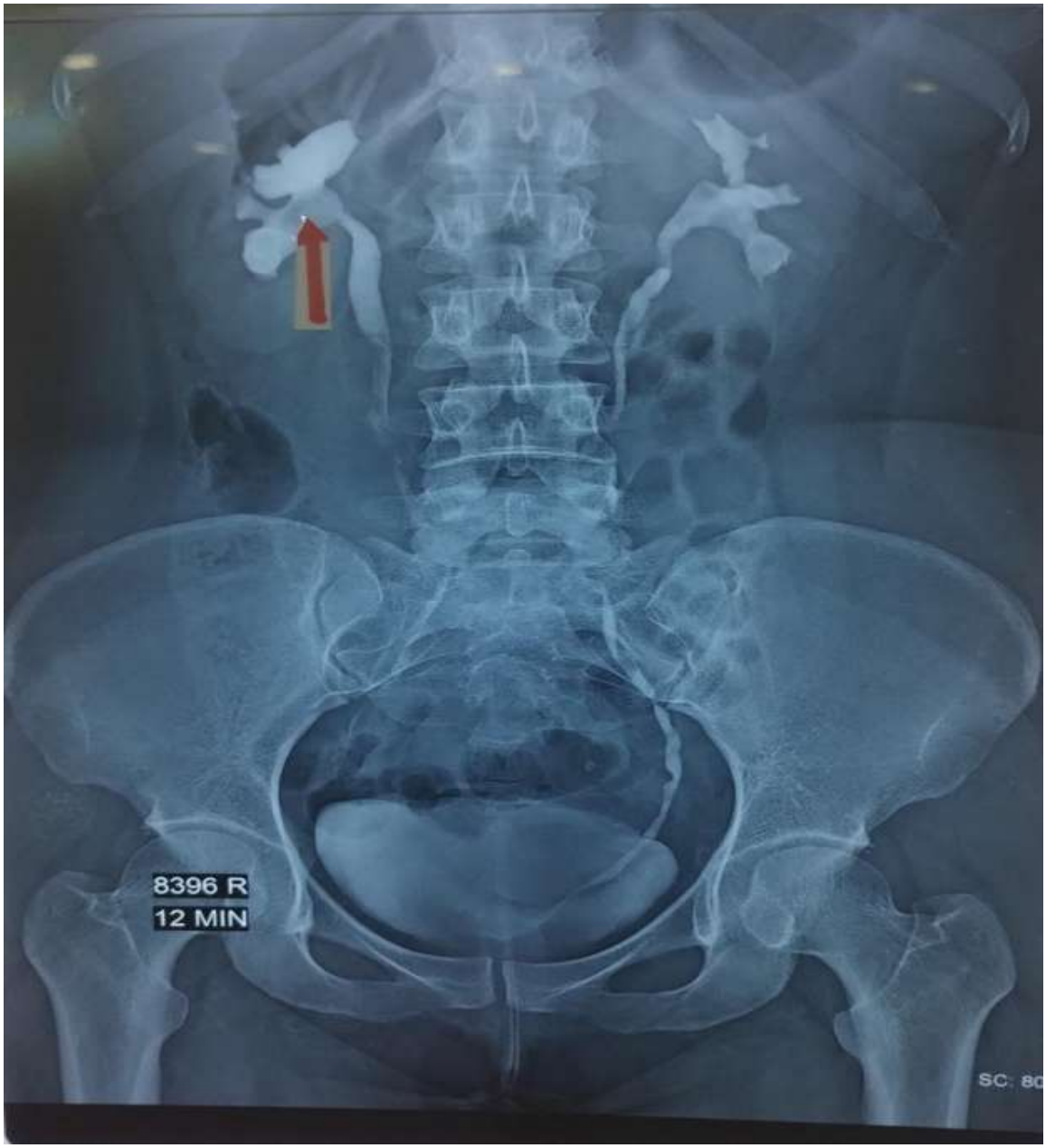

(9) A 15-year-old boy admitted with painful swollen elbow following a fall on outstretched hand.

(A) Identify the abnormality indicated.
(B) Mention one nerve injury related to this.



(10) A 52-year-old male patient with diabetes mellitus presented with difficulty in walking on uneven ground. Clinical examination revealed an abnormality of this structure.

(A) Identify the structure pierced by the pin.
(B) Mention its nerve supply.



(11)

(A) Identify the structure pierced by the pin.

(B) Mention its embryological origin.



(12) A 40-year-old male patient had a fracture of the acetabulum and posterior dislocation of the femoral head following a dashboard injury, damaging the indicated structure.

(A) Identify the structure pierced by the pin.
(B) Mention one clinical feature of this injury.



(13) A 65-year-old male patient with heavy smoking presented with a hoarse voice. CT scan of the chest suspects a bronchial carcinoma affecting this structure.

(A) Identify the structure pierced by the pin.
(B) Name two branches of this structure which supply the larynx.



(14) A 50-year-old female patient underwent thyroidectomy. The surgeon retracted this structure to visualize the thyroid gland.

(A) Identify the structure pierced by the pin.
(B) Mention its nerve supply.

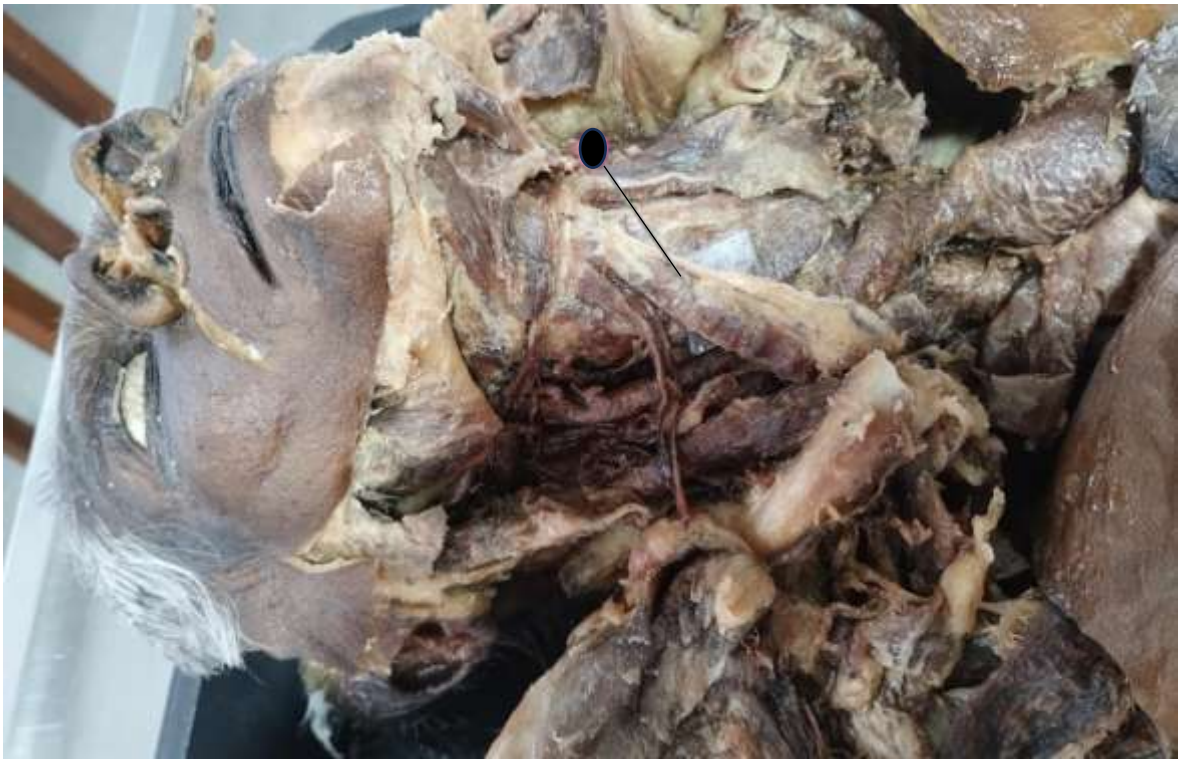

(15) A 60-year-old male patient underwent Whipple procedure. The surgeon demonstrated this structure in the operative field.

(A) Identify the structure pierced by the pin.
(B) Mention its origin.



(16) A 60-year-old male patient presented with a loin mass and hematuria. CT scan of the abdomen suspected a carcinoma spreading to this structure.

(A) Identify the structure pierced by the pin.
(B) Name two structures join this structure at this level.



(17) A 47-year-old female patient is undergoing carpal tunnel decompression. The surgeon wants to avoid injury to this structure during surgery.

(A) Identify the structure pierced by the pin.
(B) Mention its surface marking.



(18) A 35-year-old mother had uncontrollable bleeding following an emergency Cesarean section. The obstetrician decided to ligate this vessel to control bleeding.

(A) Identify the vessel pierced by the pin.
(B) Name three branches.

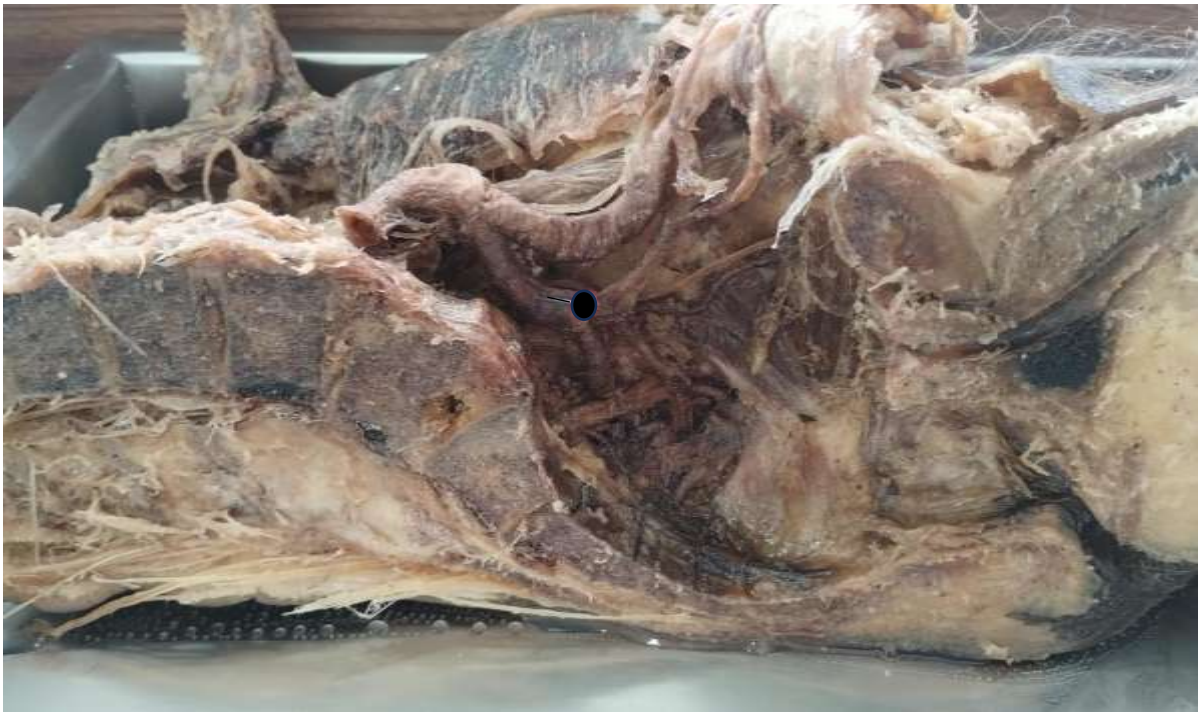

(19) A 78-year-old male patient with uncontrolled hypertension presented with a severe headache. CT scan of the brain revealed a thick blood clot here.

(A) Identify the space pierced by the pin.
(B) Name the artery which runs through this space.



(20) A 78-year-old male patient with uncontrolled hypertension presented with a severe headache. CT scan of the brain revealed a thick blood clot here.

(A) Identify the space pierced by the pin.

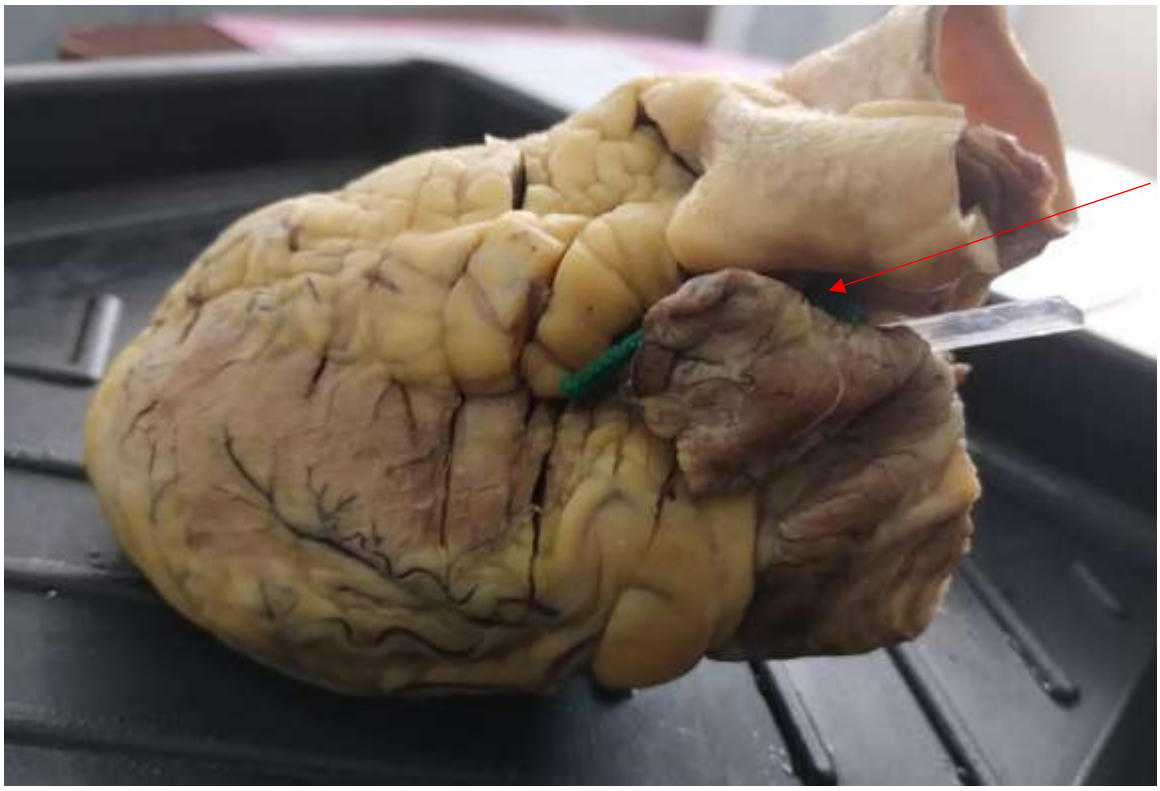

Batch 01 – 2nd MBBS Repeat (2026)– OSPE Paper Answers

(1)

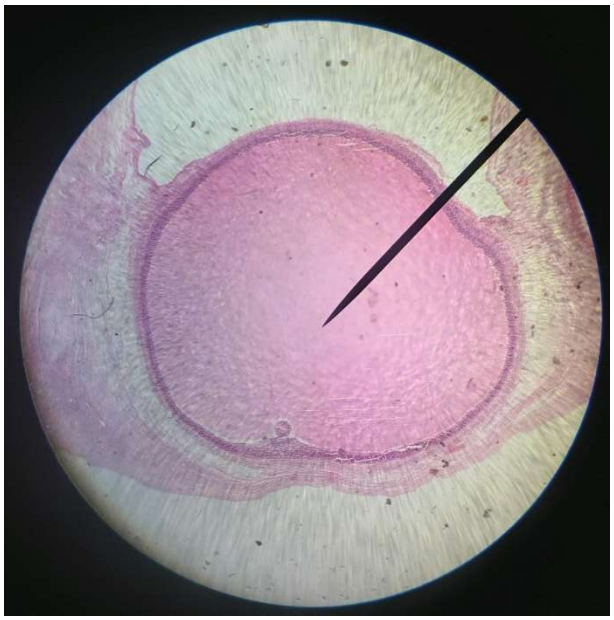

(A) Ovary
(B) Graafian follicle

(2)

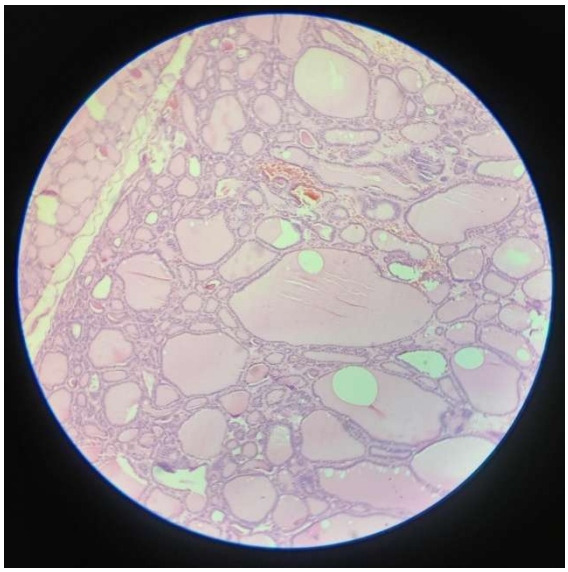

(A) Thyroid gland
(B) T3, T4 production
Calcitonin production

(3)



(A) Foramen transversarium
(B) Vertebral artery

(4)

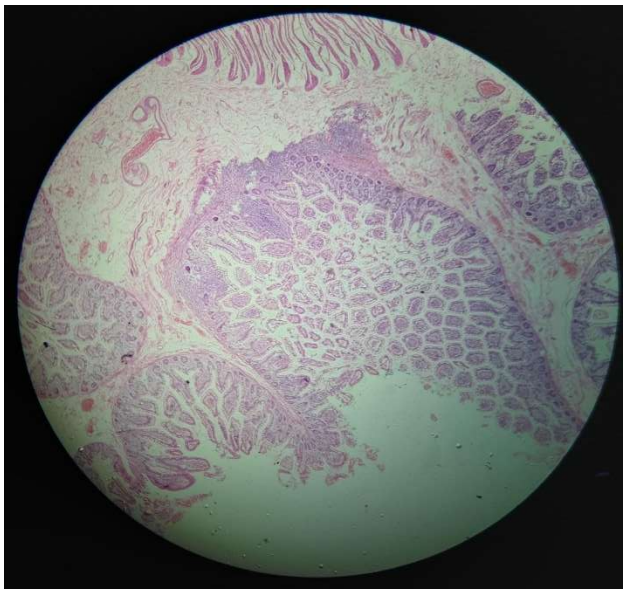

(A) Ileum
(B) Simple columnar epithelium

(5)

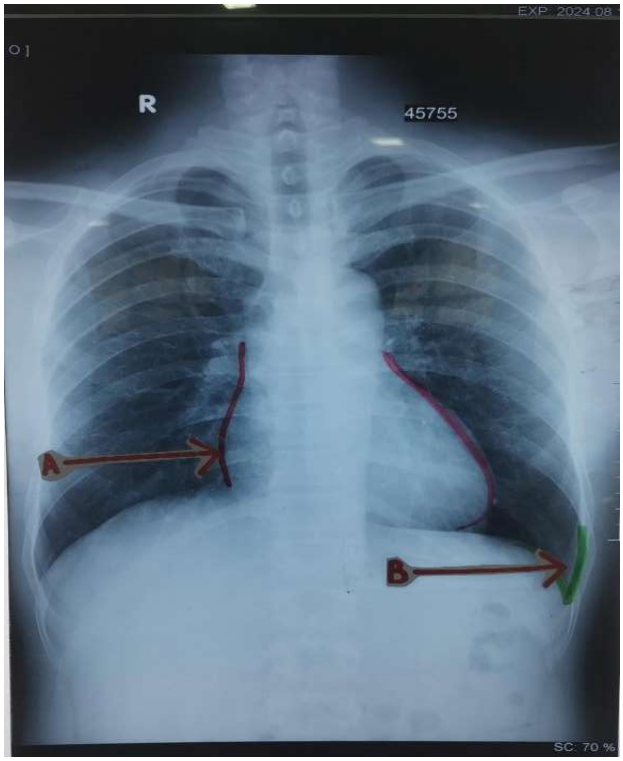

(A) Right border of the heart
(B) Costo diaphragmatic recess

(6)

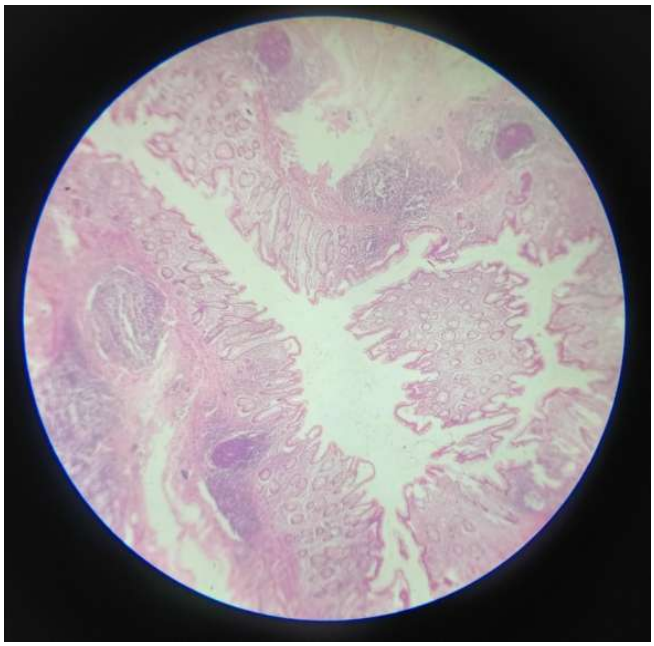

(A) Colon
(B) Submucosa

(7)

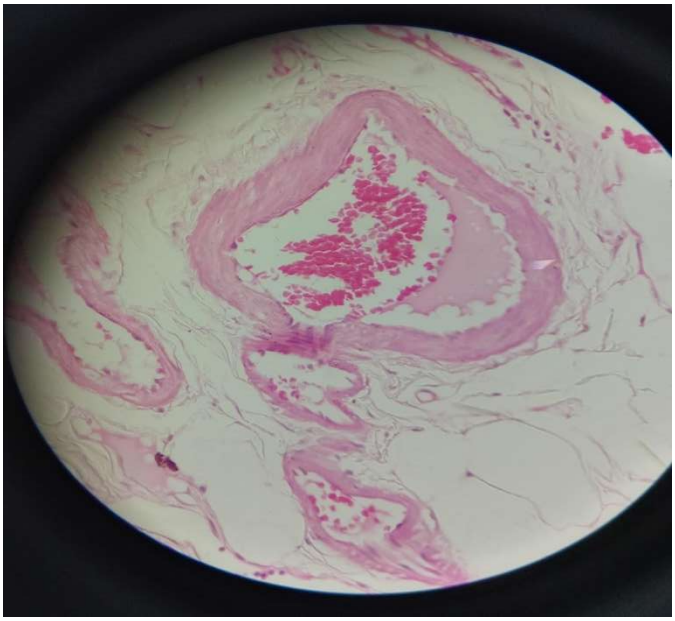

(A) Vascular endothelium
(B) Thrombosis

(8)

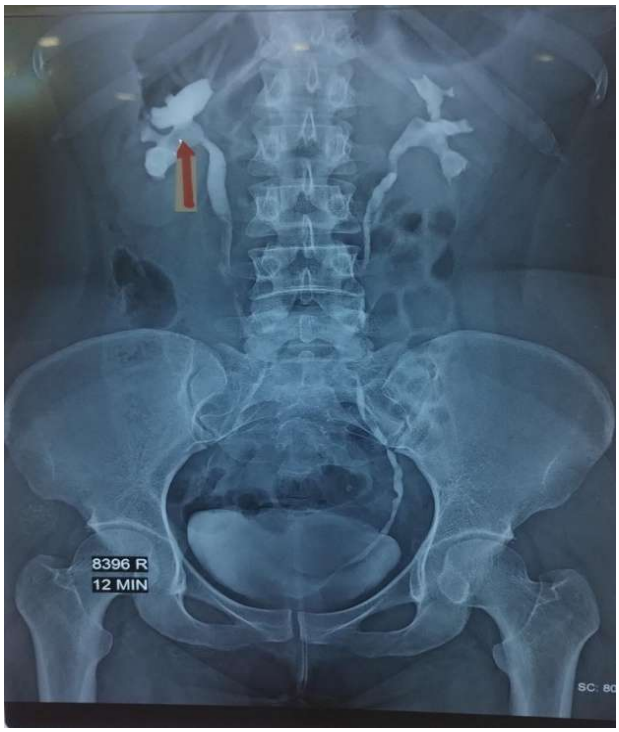

(A) Renal pelvis
(B) Transitional epithelium

(9)



(A) Supracondylar fracture of the humerus
(B) Median nerve injury

(10)



(A) Peroneus longus
(B) Superficial peroneal nerve

(11)



(A) Central tendon of the diaphragm
(B) Septum transversum

(12)



(A) Sciatic nerve
(B) Foot drop, Sensory loss of feet

(13)



(A) Left vagus nerve
(B) External laryngeal nerve and recurrent laryngeal nerve

(14)



(A) Strap muscles (Sternothyroid muscle)
(B) Ansa cervicalis (C1–C3)

(15)



(A) Splenic artery
(B) Celiac trunk

(16)



(A) Left renal vein
(B) Left testicular vein
Left suprarenal vein

(17)



(A) Superficial palmar arch
(B) Distal border of fully extended thumb

(18)



(A) Internal iliac artery
(B) Ilio lumbar, Superior gluteal, Inferior gluteal, Middle rectal, Internal Pudendal, Lateral sacral, Obturator, Umbilical

(19)



(A) Lateral sulcus of the brain
(B) Middle cerebral artery

(20)



(A) Transverse sinus
(B) Greater arteries (Aorta, Pulmonary trunk) from left atrium & SVC



MESSAGE OF THE DEAN

As the Dean of the Uva Wellassa Medical Faculty, I am delighted to present "Mastering Anatomy – Part III: A Comprehensive Guide to MCQs, Essays, and OSPEs". This publication represents a significant achievement in our ongoing commitment to enhancing the quality of medical education and supporting student learning.

In the ever-evolving discipline of medicine, a thorough knowledge of Anatomy continues to be a cornerstone of academic and professional success. This guide has been thoughtfully designed to serve as a comprehensive learning resource, covering a wide range of assessment formats, including MCQs, essays, and OSPEs, while providing detailed explanations and model answers to reinforce understanding.

The primary aim of this book is to equip students with the knowledge and skills necessary to excel in examinations and deepen their comprehension of physiological principles. We believe that this guide will become a trusted companion throughout your academic journey, helping to build confidence, improve clarity, and establish a strong foundation for learning.

I extend my heartfelt gratitude to the faculty members and contributors whose dedication, expertise, and hard work made this publication possible. It is our sincere hope that you will find this guide both informative and inspiring as you advance through your medical studies.

I wish you every success in your academic endeavours and in your future career as a medical professional.

Rs. 1500/-